

# Laryngeal mask airway vs tracheal intubation for laparoscopic hernia repair in children : analysis of respiratory complications

---

**Vickov, Josip**

**Master's thesis / Diplomski rad**

**2019**

*Degree Grantor / Ustanova koja je dodijelila akademski / stručni stupanj:* **University of Split, School of Medicine / Sveučilište u Splitu, Medicinski fakultet**

*Permanent link / Trajna poveznica:* <https://um.nsk.hr/um:nbn:hr:171:474417>

*Rights / Prava:* [In copyright](#) / [Zaštićeno autorskim pravom.](#)

*Download date / Datum preuzimanja:* **2024-04-25**



*Repository / Repozitorij:*

[MEFST Repository](#)



UNIVERSITY OF SPLIT



**UNIVERSITY OF SPLIT  
SCHOOL OF MEDICINE**

**Josip Vickov**

**LARYNGEAL MASK AIRWAY VS TRACHEAL INTUBATION  
FOR LAPAROSCOPIC HERNIA REPAIR IN CHILDREN:  
ANALYSIS OF RESPIRATORY COMPLICATIONS**

**Diploma thesis**

**Academic year:  
2018/2019**

**Mentor:**

**Assist. Prof. Zenon Pogorelić, MD, PhD**

**Split, July 2019**

<b>1. INTRODUCTION.....</b>	<b>1</b>
1.1 ANATOMY OF THE INGUINAL REGION .....	2
1.2. TESTICULAR DESCENT.....	4
1.3. INGUINAL HERNIA .....	5
1.3.1. Anatomy of the inguinal hernia.....	5
1.3.2. Types of inguinal hernia .....	5
1.3.2.1. Indirect inguinal hernia .....	6
1.3.2.2. Direct inguinal hernia .....	6
1.3.3. Incidence .....	7
1.3.4. Clinical Findings .....	7
1.3.5. Complications .....	8
1.3.6. Diagnostic approach.....	9
1.3.7. Treatment.....	10
1.3.7.1. Surgical techniques.....	11
1.3.7.1.1. Open surgery .....	11
1.3.7.1.2. Laparoscopic surgery.....	12
1.4. Airway management in children .....	13
1.4.1. Laryngeal mask airway .....	13
1.4.2. Tracheal Tubes.....	14
1.5. Anesthetics .....	16
1.5.1. Inhalational Anesthetics .....	16
1.5.2. Intravenous Anesthetics.....	16
<b>2. OBJECTIVES OF RESEARCH.....</b>	<b>18</b>
<b>3. MATERIAL AND METHODS.....</b>	<b>20</b>
3.1. Patients.....	21
3.2. Organization of the study .....	21
3.3. Place of the study .....	22
3.4. Methods of data collection and processing .....	22
3.5. Description of research .....	22
3.5.1. Primary outcome measures .....	23
3.5.2. Secondary outcome measures .....	23
3.6. Follow-up.....	23
3.7. Surgery.....	23

3.8. Anesthesiology .....	26
3.8.1. Larygeal mask introduction .....	26
3.8.2. Tracheal intubation .....	26
<b>4. RESULTS.....</b>	<b>27</b>
<b>5. DISCUSSION .....</b>	<b>34</b>
<b>6. CONCLUSION.....</b>	<b>38</b>
<b>7. REFERENCES .....</b>	<b>40</b>
<b>8. SUMMARY .....</b>	<b>45</b>
<b>9. SUMMARY IN CROATIAN .....</b>	<b>47</b>
<b>10. CURRICULUM VITAE.....</b>	<b>49</b>

*I wish to thank*

*my mother, for showing me wisdom and warmth when I needed it the most,*

*my father, for teaching me tenacity,*

*my brother, for leading with optimism,*

*Eli, for always being by my side.*

*I love you all.*

*I would also like to express my great appreciation to my mentor, Dr Zenon Pogorelić, for his valuable suggestions and patience during the planning and development of this research work.*

*Finally, I wish to thank Dr Ana Neveščanin for her help in offering me materials in order to complete my thesis.*

## **1. INTRODUCTION**

## 1.1 ANATOMY OF THE INGUINAL REGION

The inguinal region extends between the anterior superior iliac spine and pubic tubercle. It is an important area both anatomically and clinically; anatomically because it is where various structures enter and exit abdominal cavity, and clinically because the routes of entrance and exit are potential sites of herniation (Figure 1) (1).

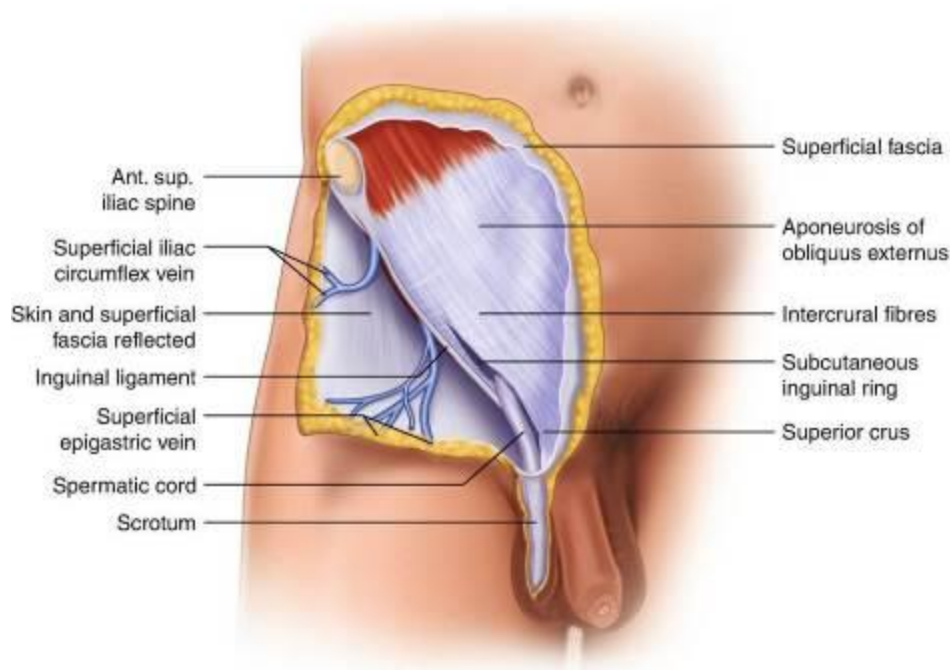
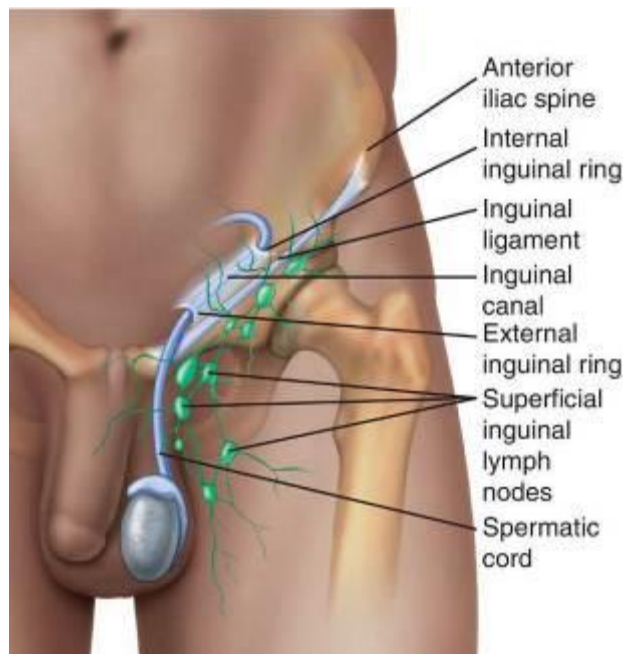


Figure 1. Anatomy of the inguinal region. Source: [https://link.springer.com/chapter/10.1007/978-3-319-72626-7\\_17](https://link.springer.com/chapter/10.1007/978-3-319-72626-7_17)

The major landmarks of the region are the thickened inferolateral-most portions of the external oblique and aponeurosis and the inferior margin of the transversalis fascia. Another major structure is the inguinal canal, formed in relation to the relocation of the testis during fetal development. The inguinal canal in adults is an oblique passage, approximately 4 cm long,

directed inferomedially through the inferior part of the anterolateral abdominal wall. The main occupant in the canal is the spermatic cord in males and the round ligament in females (Figure 2).



*Figure 2. Anatomy of the inguinal canal.*

Source: <https://medical-dictionary.thefreedictionary.com/inguinal+region>

The inguinal canal has two walls (anterior and posterior), a roof, and a floor. It also has an opening at each end, the deep (internal) inguinal ring and the superficial (external) inguinal ring. The anterior wall is formed by the external oblique aponeurosis and its lateral part is reinforced by muscle fibers of the internal oblique. Posterior wall is shaped by the peritoneum and the transversalis fascia. While its medial part is reinforced by pubic attachments of the internal oblique and transversus abdominis fascia, its middle third is very thin and is often referred to as „locus minoris resistentiae“. Furthermore, the posterior wall is also the site where the inguinal (Hesselbach's) triangle is positioned. It is bordered by linea semilunaris, inferior epigastric vessels and the inguinal ligament (Figure 3). Its clinical significance lies in the fact that it's the weakest point of the abdominal wall and the site of both inguinal and femoral hernias (1).



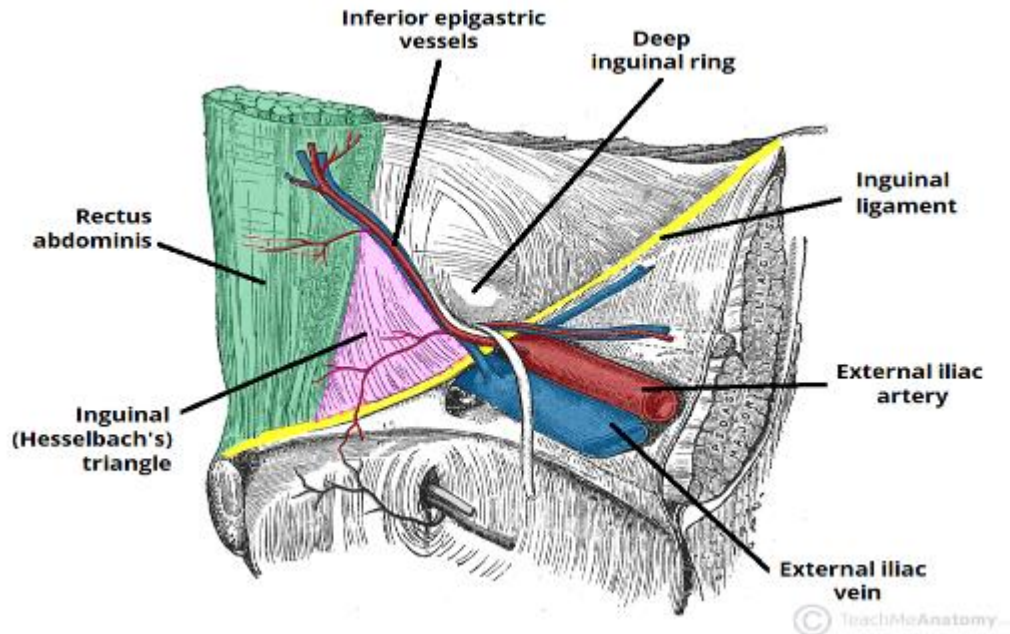


Figure 3. Hesselbach's triangle.

Source: <https://teachmeanatomy.info/abdomen/areas/inguinal-triangle/>

## 1.2. TESTICULAR DESCENT

Although the testis is located in the perineum postnatally, the male gonad originally forms in the extraperitoneal connective tissue in the superior lumbar region of the posterior abdominal wall. A peritoneal diverticulum, the processus vaginalis, traverses the developing inguinal canal, carrying muscular and fascial layers of the abdominal wall. By 28 weeks the testes start to pass the inguinal canal and four weeks later they enter the scrotal sac. The stalk of the processus vaginalis normally degenerates and its distal part forms the tunica vaginalis, pouch of serous membrane that covers the testes and epididymis. However, there is a difference of opinion when it comes to exact time of obliteration of processus vaginalis. As claimed by Snyder and Greaney, processus vaginalis hasn't obliterated in 94% of newborns (2). In 50% of cases, the processus is still open by the end of the child's first year. Patent processus vaginalis (PPV) allows the passage of intraperitoneal contents between the abdomen and scrotum, and 20% of those in whom the

PPV remains patent will present clinically with an inguinal hernia or hydrocele during their lifetime (3). Given this, testicular descent and congenital inguinal hernia remain two very intertwined terms.

When the testes pass through the inguinal canal, they cause pressure on the walls of the canal, strengthening the muscles involved in maintaining the structure of the canal. As the male gonads, their duct, and their vessels and nerves relocate, they are enclosed by internal and external spermatic fascia and cremaster muscle (1). This cord-like structure is called the spermatic cord.

## **1.3. INGUINAL HERNIA**

### **1.3.1. Anatomy of the inguinal hernia**

An inguinal hernia is a protrusion of peritoneum and viscera, like small intestine, through a pathological or normal opening from the cavity in which they belong. As these organs make their way through, they push the parietal peritoneum forming the hernial sac. The main parts of every hernia are the opening in the abdominal wall, hernial sac, hernial tunica and hernial content. Hernial tunica consists of adipose tissue, fascia and aponeurosis (4).

### **1.3.2. Types of inguinal hernia**

Based on how they are formed, there are two types of inguinal hernias: indirect and direct hernias.

### **1.3.2.1. Indirect inguinal hernia**

An indirect inguinal hernia results when there is no obliteration of the processus vaginalis. More than two thirds of all inguinal hernias are indirect and most of the patients are male, most probably, due to the larger size of their inguinal canal (5). When it comes to pediatric patients, indirect hernia comprises 99.4% of all cases, while direct hernia is very rare, forming only 0.25% of the selected patients (6). The resultant hernial sac passes through the internal inguinal ring, an entrance to the inguinal canal. According to Doherty *et al.* the sac is located anteromedially within the spermatic cord and may extend along the inguinal canal (7). A hernia that passes fully into the scrotum is known as complete hernia. There are two types of hernias caused by patent processus vaginalis. The first one, which is more common, is characterized by the hernial sac reaching the proximal part of the testis, which is usually placed in the scrotum. The reason for this is that processus vaginalis obliterates only its distal part, very close to the proximal part of the testis. The other type is called the congenital hernia. In this case, the testis, along with testicular gubernaculum, is completely ensheathed by the hernial sac. The source of this pathology is of developmental nature, weak inguinal musculature, wide inguinal rings and completely or partially patent processus vaginalis (8).

### **1.3.2.2. Direct inguinal hernia**

The direct inguinal hernia enters through a weak point in the fascia of the abdominal wall, mentioned above as the Hesselbach triangle. In most direct hernias, the transversalis fascia is very attenuated, though a discrete defect in the fascia may sometimes occur (7). This funicular type of hernia is more prone to incarceration, due to its distinct borders. Direct inguinal hernias may exit through the external inguinal ring and are unable to enter the scrotum. Most of the aforementioned hernias in pediatric patients are found to be recidives of past treated indirect inguinal hernias. In those cases it is due to inadequate surgical technique or wound closure (4).

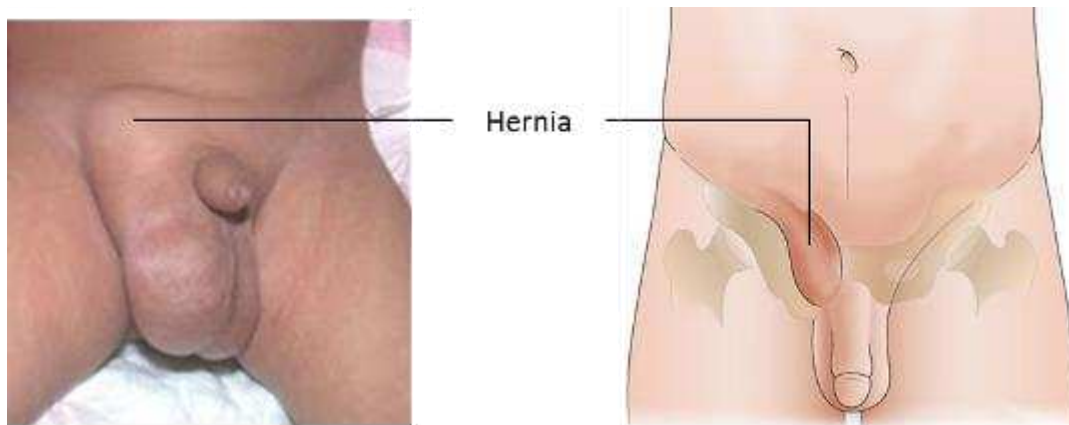
### **1.3.3. Incidence**

According to Grosfeld, the incidence of inguinal hernia ranges approximately from 3% to 5% in term infants and amounts to 13% in infants born earlier than 33 weeks of gestational age (9). The incidence rate is 13.7% for subjects under 1500 g of weight and 8.2% for those between 1500 and 1999 g (10). Males are far more likely to develop an inguinal hernia with a male to female ratio between 3:1 and 10:1. It is also worth noting is that in cases of unilateral hernia, right side is affected in 60% of cases. Bilateral hernia is present in 10% of cases. This percentage is the same for both sexes (11).

Any condition that chronically increases intra-abdominal pressure contributes to the possibility of herniation. The most common ones are marked as obesity, cough, constipation with straining at stool *etc.*

### **1.3.4. Clinical Findings**

The most prominent finding in a patient with an inguinal hernia is a bulge in the inguinal region, sometimes protruding into the scrotal sac. Another symptom is pain, which may or may not be present (1). A hernia that is seen in the scrotum is almost definitely indirect. As a rule, direct hernias produce less symptoms than indirect ones and they are also less likely to become incarcerated. It is of utmost importance to examine the patient with coughing or physical straining, since small hernias may be harder to show. If the hernia is not incarcerated, the swelling is soft to the touch, and is also reducible (Figure 4).



*Figure 4. Inguinal hernia – part of the mass is protruding into the scrotal sac*

Source: <http://www.paediatricsurgeondubai.com/2017/10/09/inguinal-hernia-repair-in-children/>

### **1.3.5. Complications**

In most of the patients suffering from inguinal hernia, external and the internal inguinal rings, along with the inguinal canal are wide enough to allow the repositioning of the hernia to the abdominal cavity (3). In the next moment, increased abdominal pressure forces the hernia back into the hernial sac. This can be done either in prone or standing positions. This type of hernia is called reducible hernia (1). As long as this is the case, there is no fear of ischemia or necrosis.

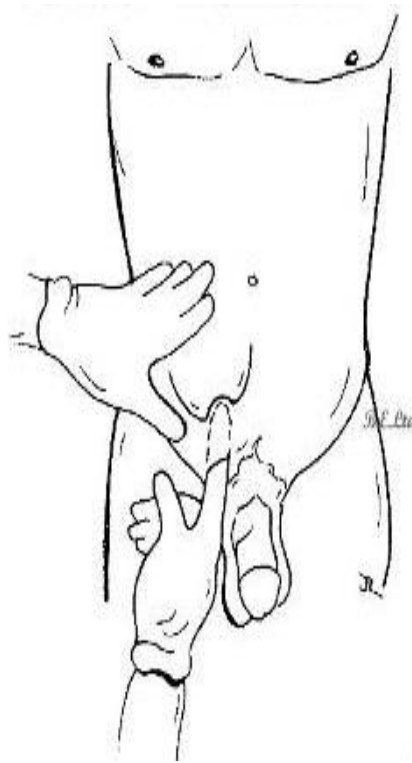
On the other hand, there is also an irreducible hernia. The contents of this hernia cannot return to the abdomen. This is mostly due to the hernial sac being entrapped by a narrow neck. This can lead to a complete obstruction of the vessels in the hernial mass, leading to necrosis. The condition described previously is called strangulated hernia. Another possibility is that feces gets stuck in the herniated part of the intestine, leading to ileus and obstruction of vessels (Figure 5). This type of hernia is called incarcerated. They are most common in newborns. Both of these conditions are life threatening and should be treated surgically as soon as possible.

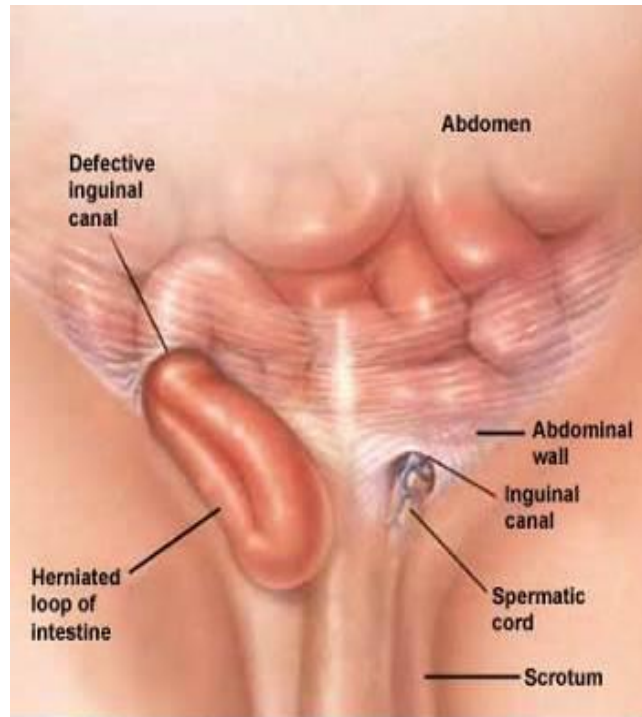

Figure 5. Incarcerated inguinal hernia. Source: <https://www.mayoclinic.org/diseases-conditions/inguinal-hernia/symptoms-causes/syc-20351547>

### 1.3.6. Diagnostic approach

The most important aspect of diagnosing the hernia is observing. In the case of pediatric patients, parents are usually the first ones to see a lump in the groin region (2). The lump is attenuated in the morning while in the evening, due to the abdominal pressure and physical activity, it's intensified. The external ring of the inguinal canal can be palpated by invaginating the scrotum and feeling with a finger superior and lateral to the pubic tubercle (Figure 6). In order to properly diagnose herniation, hernial content must be felt protruding through the canal while coughing. There is no point in differentiating between direct and indirect hernia while examining the patient, not only because it's hard, but also because most groin hernias should be treated surgically regardless of type (8). While percussing the area one can expect a tympanic sound. A dull sound is present if the intestine is occupied with feces or if there is underlying omentum. If the diagnosis isn't readily apparent during physical examination, performing an ultrasound is the next step.



*Figure 6. Palpating the external ring of the inguinal canal.*

Source: <http://www.clinicalexams.co.uk/examination-techniques-for-hernia/>

### **1.3.7. Treatment**

In the case of incarceration, nonoperative reduction of the hernia may be attempted. The patient is placed on the table with hips elevated higher than the head. In most of the cases the hernia will spontaneously reduce due to gravity, usually within 15-20 minutes. If that is not the case, manual repositioning may be attempted. After the child is mildly sedated, the doctor will use one hand to push the hernial content towards the external inguinal ring and the other hand to push the inguinal canal in a downwards direction. Although strangulation is often very evident, as a rule the patient should stay in the hospital for some time to check for possible gangrenous tissue inside the abdomen. It is crucial to schedule a surgery, since no hernia will heal spontaneously. As a study conducted by Goldstein and Potts showed, in female infants the inguinal hernia contains ovary with or without fallopian tube in 15-20% of cases (12). Although an ovary is

relatively easy to reposition, it is prone to recurrent prolapse and strangulation. Some cannot be repositioned, so the only solution is an emergent surgery. The most commonly used surgical techniques today are described in the following section.

### **1.3.7.1. Surgical techniques**

The goal of the inguinal hernia surgery is to reduce the contents of the hernia into the abdomen and to close the fascial defect. Traditional surgical repairs closed the defect between native tissues using permanent sutures.

#### **1.3.7.1.1. Open surgery**

Today, there are various surgical techniques for pediatric inguinal hernia repair. In many centers a modified Marcy repair, which includes high ligation and excision of hernia sac, with narrowing of the internal inguinal ring, is very popular for pediatric inguinal hernia repair, because it is associated with the lowest recurrence rates. The method was introduced in 1871. by Boston born surgeon Henry Marcy. During that procedure Marcy performed a high ligation of the hernial sac and closed the internal inguinal ring using two stitches of carbonized catgut. Another surgical technique is called the Ferguson repair, described in 1899. The main features of the Ferguson herniorrhaphy include leaving the cord undisturbed, using the cremaster muscle and the transversalis fascia during the repair, and suturing the internal oblique muscle and the tendon over the spermatic cord to Poupart's ligament (13). In 1972. in University Hospital of Split a modified Marcy repair was introduced as it proved to leave the least number of recidives. During the surgery, the doctor will open the inguinal canal and the hernial sac, after which, with the help of a finger placed through the sac into the abdominal cavity, the canal will be inspected and the internal ring narrowed to resemble the width of funiculus (14). *Šimunović et al.* compared the Marcy technique to the Ferguson and found no recidives in the former leading to a conclusion that Marcy repair should be the treatment of choice in children with inguinal hernia (15). This initial results were confirmed in study on 6 826 patients. The overall reported recurrence rate for



Marcy repair was only 0.36 % (6). Open herniotomies include an increased risk of hematomas, blood loss, infections, damaging the vas deferens and testicular atrophy (16, 17).

#### **1.3.7.1.2. Laparoscopic surgery**

By advancing of laparoscopic surgery, many successful laparoscopic inguinal hernia repairs were reported (18). After introduction of percutaneous internal ring suturing (PIRS) for pediatric inguinal hernia repair by *Patkowski*, this technique became very popular among pediatric surgeons (19). It involves the percutaneous closure of the internal inguinal ring under the control of a laparoscope placed through the umbilical port (19, 20). Advantages of laparoscopy are already well known. This had been attributed to several factors such as the inexperience of the surgeons, the use of absorbable suture, the use of a single suture or larger defects. More recent publications report lower recurrence and complications rate (21, 22). Recently published meta-analysis had shown the rate of recurrence of 0.7% which is very similar to open surgery (21). An incidence of complications in hands of experienced laparoscopic pediatric surgeon is very low. The most common reported complications are injury of blood vessels, recurrence, hydrocele formation, knot reaction, severe pain, and scrotal swelling (21). An advantage of the PIRS technique is better visualization of the peritoneal cavity, and thus the ability to detect other abnormalities or repair a contralateral open inguinal ring that would be a potential hidden hernia. PIRS technique requires only one umbilical port and needle puncture point. Use of PIRS technique in children shows significantly lower surgical stress in comparison to open hernia repair (23). The surgery showed excellent cosmetic results with almost no visible scars.

## **1.4. Airway management in children**

With regard to delivering pediatric anesthesia, appropriate airway management is its most important dimension. Regardless of the patient's age, surgical procedures can be performed with face mask, laryngeal mask airway (LM), or endotracheal tube placement. Endotracheal tubes are considered to be more appropriate for premature infants and neonates when maintaining general anesthesia due to a greater difficulty of providing effective face mask ventilation and the danger of air entering the stomach. Cases, where patients have recent oral intake or pathology (like intestinal obstruction and pyloric stenosis), are claimed to be best managed with a rapid sequence induction and intubation, no matter the age (24). Since the narrowest portion of a child's airway is at the level of cricoid cartilage, uncuffed tubes are used and, if applied in a correct size, they will make a seal.

### **1.4.1. Laryngeal mask airway**

With respect to the frequency of using LM, Morgan *et al.* state that this kind of airway management is being increasingly used in place of a face mask or tracheal intubation (TI), to promote ventilation and passage of a tracheal tube in children with a difficult airway (25). There are several types of laryngeal masks on the market. The most commonly used ones are: the LM Classic (the original design, reusable), LM Unique (disposable version), LM Fastrach (used in difficult airway algorithms), LM ProSeal (with a built-in channel for suctioning of gastric contents) and LM CTrach (has built-in fiberoptics with a video screen). LM is designed in such a way that its proximal part is connected to a breathing circuit while its distal end is basically an oval shaped inflatable cuff. The deflated cuff is lubricated and inserted blindly into the hypopharynx so when it is inflated, it forms a seal around the entrance to the larynx. The LM

partially protects the larynx from pharyngeal secretions (not from gastric regurgitation) so it should not be moved until the patient has regained airway reflexes. The LM airway provides an alternative to ventilation using a face mask or tracheal tube. The contraindications for the usage of laryngeal mask include patients suffering from pharyngeal pathology like an abscess, pharyngeal obstruction, full stomachs and low pulmonary compliance needing peak inspiratory pressures greater than 30 cm H<sub>2</sub>O. New evidence suggests that as the LM is not placed in the trachea, its use is associated with a fewer number of bronchospasms than a tracheal tube. Furthermore, the LM has shown as being particularly useful as a temporizing measure in patients with difficult airways due to its ease of insertion and high success rate (95-99%) (25).

### **1.4.2. Tracheal Tubes**

Tracheal tubes (TT) are used to deliver anesthetic gases straight into the trachea as they give the most control of ventilation and oxygenation. The most common material used for manufacturing TTs is polyvinyl chloride. It is important to note that the shape and firmness of the tubes can be altered by inserting a stylet. Most adult TTs have a cuff inflation system consisting of a valve, pilot balloon, inflating tube, and a cuff. The idea is that the valve prevents air loss after the cuff is inflated. The tracheal tube reduces the likelihood of aspiration and allows positive-pressure ventilation by creating a tracheal seal. Uncuffed tubes are usually used in pediatric patients to reduce the risk of pressure injury and postintubation croup. As can be seen from Table 1., there are multiple advantages and disadvantages of the usage of TTs and LMs in separate surgical procedures (25).

*Table 1. Advantages and disadvantages of TTs and LMs.*

	Advantages	Disadvantages
Compared with face mask	Hands-free operation Better seal in bearded patients Less cumbersome in ENT surgery Often easier to maintain airway Protects against airway secretions Less facial nerve and eye trauma Less operating room pollution	More invasive More risk of airway trauma Requires new skill Deeper anesthesia required Requires some TMJ mobility N <sub>2</sub> O diffusion into cuff Multiple contraindications
Compared with tracheal intubation	Less invasive Very useful in difficult intubations Less tooth and laryngeal trauma Less laryngospasm and bronchospasm Does not require muscle relaxation Does not require neck mobility No risk of esophageal or endobronchial intubation	Increased risk of gastrointestinal aspiration Less safe in prone or jackknife positions Limits maximum PPV Less secure airway Greater risk of gas leak and pollution Can cause gastric distension

*ENT – ear, nose and throat; TMJ – temporomandibular joint; PPV – positive pressure ventilation*

Based on their cuffs, tracheal tubes can be divided into two types: high and low pressure cuffs. The former ones are not intended for prolonged use since they cause damage to tracheal mucosa. The latter, also being the most commonly used, increase the likelihood of sore throat, aspiration and spontaneous extubation. Different modifications of the tubes are available for different surgeries, e.g. armored and spiral-wound tubes. Although the constant detection of CO<sub>2</sub> by a capnograph is the best sign of tracheal placement of a TT, it cannot exclude bronchial intubation. The earliest confirmation of tracheal intubation is an increase in peak inspiratory pressure. Although there is a lot of discussion regarding the process of intubation, extubation should not be overlooked since its complications can be more treacherous than those of intubation. Most patients are extubated when they regain consciousness and spontaneous respiration or when they can follow simple commands. A patient who seemed to have a difficult airway at the time of anesthetic induction must be considered to have a more difficult extubation as well. The authors further note that the most important complication is a laryngospasm because it is very common in pediatric patients and because it accounts for 23% of all critical postoperative respiratory events in adults (24). It may be caused by respiratory secretions, blood,

foreign structure in the airway, vomitus or pain in any part of the body. It is managed by removing the offending stimulus, administration of oxygen and, if needed, muscle relaxants. The most common consequence of a laryngospasm is negative-pressure pulmonary edema. To prevent these cases, it is important to identify patients at risk early and to have a team ready at the time of extubation.

## **1.5. Anesthetics**

### **1.5.1. Inhalational Anesthetics**

As explained by Gormley, neonates, infants and young children have higher alveolar ventilation which contributes to a fast rise in concentration of anesthetic in alveoli and speeds up inhalation induction (26, 27). Furthermore, the blood pressure of neonates and infants is more sensitive to inhalational anesthetics, most likely due to compensatory mechanisms not being fully developed yet. Sevoflurane is characteristic for its rapid induction of anesthesia. It also has pleasant smell so it is ideal for induction of anesthesia in children. The rate of emergence is fastest with desflurane and sevoflurane anesthesia, but both of these are connected to increased incidence of agitation upon emergence. Therefore anesthesiologists use isoflurane, sometimes mixed with nitrous oxide, for maintaining anesthesia.

### **1.5.2. Intravenous Anesthetics**

The most commonly used nonvolatile anesthetic in children is propofol. It is characterized by a very fast onset, but also very fast awakening without agitation. Another strong point of propofol is that it has a good antiemetic effect. These features make it popular for short surgical or diagnostic procedures. Morgan *et al.* emphasize that this drug shouldn't be used in critically ill pediatric patients in the intensive care unit since propofol has been associated with higher mortality rate compared to other agents (25). Thiopental is the most commonly used barbiturate

in anesthesia. It depresses respiratory center which can lead to delayed response to hypoxia and hypercapnia. Children require higher doses when compared to adults since the elimination half-life is shorter and plasma clearance faster.

## **2. OBJECTIVES OF RESEARCH**

Inguinal hernia repair is one of the most commonly performed surgical procedures in pediatric patients. All inguinal hernias have to be treated surgically because they can lead to serious complications. The anesthesia for the surgery is usually induced via TI or LM. Due to the high frequency of the procedure, it is of utmost importance to manage the airway in a way that would lead to as least number of unwanted effects as possible.

The aim of this study was to compare the perioperative and postoperative respiratory complications between LM airway and TI in children undergoing PIRS for inguinal hernia.

**Hypotheses:**

- 1) LM leads to significantly lower incidence of desaturation, laryngospasm and cough.
- 2) Postoperative incidences of sore throat, bronchospasm and aspiration are expected not to differ between LM and TI.
- 3) Duration of anesthesia is expected to be shorter using LM in comparison to TI.



### **3. MATERIAL AND METHODS**

### **3.1. Patients**

All patients who underwent PIRS for inguinal hernia at the Department of Pediatric Surgery of the University Hospital of Split in the period from October 2015 to February 2019.

#### *Inclusion criteria:*

1. Patients of both genders, up to 17 years of age, with an inguinal hernia treated by the PIRS
2. Patients operated in University Hospital of Split by a specialist in pediatric surgery
3. Follow-up at least 4 weeks after surgery

#### *Exclusion criteria:*

1. Patients older than 17 years of age
2. Conversion to open procedure
3. Patients operated in another institution
4. Patients with incomplete data

### **3.2. Organization of the study**

The study was carried out as a prospective cohort study by corresponding quantitative research and descriptively processed data.

### **3.3. Place of the study**

The research took place at the Department of Pediatric Surgery, University Hospital of Split, Croatia.

### **3.4. Methods of data collection and processing**

The corresponding data was obtained by revising the study protocols and medical records. The data were analyzed using the Microsoft Excel for Windows Version 11.0 (Microsoft Corporation) and SPSS 24.0 (IBM Corp, Armonk, NY) software programs. Distributions of quantitative data were described by medians and ranges, whereas absolute rates and percentages were used to describe categorical data. Differences in median values of quantitative variables between the groups of patients were tested with Mann–Whitney U test. The Chi-square test was used for the statistical analysis of the categorical data. All values of  $P < 0.05$  were considered to indicate statistical significance.

### **3.5. Description of research**

Patients are admitted to hospital on the day of surgery. Medical history and demographic data are recorded in study protocol. Regarding the type of anesthesia the patients were divided into two distinct groups. In Group I LM was used, and in Group II TI was performed. Surgical and anesthesia times, ASA classification, muscle relaxation, level of pneumoperitoneum and complications of anesthesia were compared between the groups. Postoperative follow-up included duration of hospital stay, pain level and postoperative complications. All patients were discharged from hospital the day after surgery.

### **3.5.1. Primary outcome measures**

The primary outcomes were intraoperative desaturation, postoperative laryngospasm and cough. To determine superiority of one airway management technique, we expected consistent and significant differences between the groups in all the listed outcome measures.

### **3.5.2. Secondary outcome measures**

The secondary outcomes were postoperative bronchospasm, sore throat and aspiration.

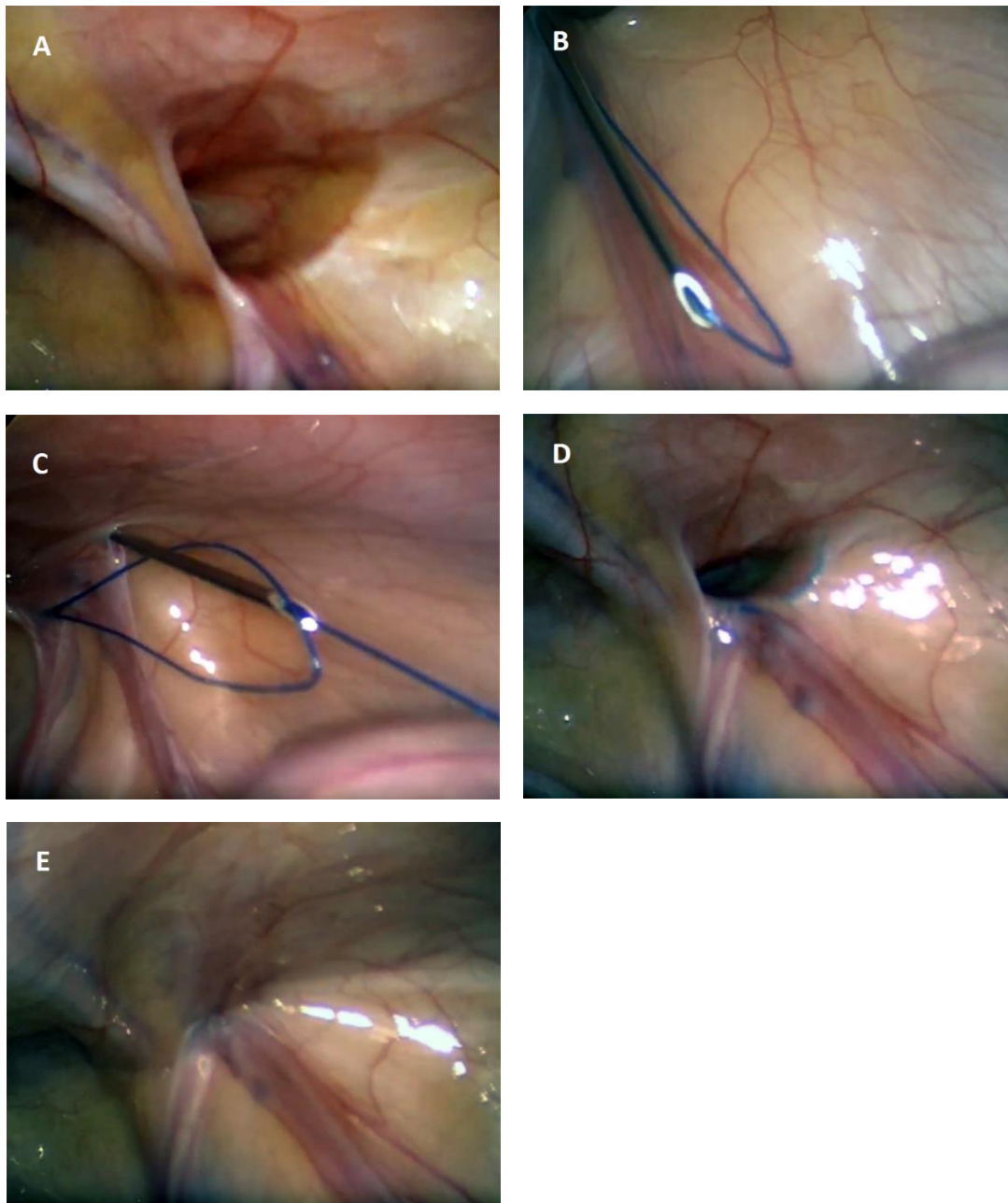
## **3.6. Follow-up**

The patients were followed-up at our outpatient clinic at the first and fourth week after surgery for detection of any complications. Sterile-strip or skin sutures were removed in the first-week visit. Follow-up program consisted of physical examination 6 months after surgery to assess the presence of late complications or recurrence of the hernia.

## **3.7. Surgery**

Through 3-mm supraumbilical incision, a Veress needle is used to achieve pneumoperitoneum of 6–10 mmHg, depending on patients' weight and age. A 3-mm port is inserted through supraumbilical incision. A 3-mm laparoscope is used to visualize open internal inguinal ring on side of hernia (Figure 7A). Mini skin incision of 2 mm is performed in optimal position above the internal ring. A 20G spinal needle (ELDOR CSEN 38.4; Quincke Spinal Needle, Z.R.M.I. Co. Ltd. Jerusalem, Israel) is used for introduction of a nonabsorbable

monofilament nylon loop (Prolene™ 3-0, polypropylene, Ethicon®, Cincinnati, Ohio, USA) at one side of the internal ring, taking care not to enter peritoneal cavity multiple times or damage blood vessels and spermatic cord, but to take as much of the edge of entered side of internal ring (Figure 7B). The loop is introduced into the peritoneal cavity and the spinal needle is taken out with care taken not to pull the loop out. The same needle was introduced at same skin incision but on the other side of the internal ring, again with care taken not to enter peritoneal cavity multiple times but to take as much of the edge of entered side of internal ring. The needle is then passed through the previously introduced loop and the same suture is passed through the needle (Figure 7C). After removal of the needle the loop is withdrawn, catching the second suture, passing it out of the skin incision, tying it, and thus obliterating the internal ring (Figure 7D). Successful repair is defined if occlusion of the hernia is visualized (Figure 7E). Round gauze ball is placed on umbilical wound with sterile drape above it and mini inguinal wound is closed using braided adhesive sterile strips.



*Figure 7. PIRS technique: **A)** right inguinal hernia—open internal inguinal ring; **B)** introduction of a non-absorbable monofilament nylon loop through half of the inguinal ring; **C)** the same needle was introduced at same skin incision but on the other side of the internal ring, and passed through the previously introduced loop and suture is pushed through the needle; **D)** after removal of the needle, the loop was drawn out and the knot passed around internal ring; **E)** closed internal ring*

*Source: Archive of Department of Pediatric Surgery, KBC Split*

## **3.8. Anesthesiology**

### **3.8.1. Larygeal mask introduction**

Adequate mask size is critical to a good placement, so the largest size that fits comfortably in the oral cavity is used. The next step is to inflate the cuff to the minimum pressure that allows ventilation to 20 cm H<sub>2</sub>O, forming an effective seal. An intravenous pathway is established after attaining sufficient anesthetic depth before the LM (Solus, Intersurgical LTD, Berkshire, UK) is inserted because it can precipitate laryngospasm. It is pushed down along the palato-pharyngeal curve until resistance is felt. The cuff is then inflated to the minimum pressure that allows ventilation to 20 cm H<sub>2</sub>O, forming an effective seal.

### **3.8.2. Tracheal intubation**

Patient's position in which intubation is performed is called „sniffing the morning air“. In this way, the axes of the oral cavity, pharynx and trachea are aligned. The head is extended and the neck is flexed. The tracheal tube (Curity, Covidien, Mansfield, USA) is introduced using the laryngoscope, minding the teeth so as not to cause any damage. The laryngoscope is held with the left hand. Pushing down gently on the larynx with the fifth finger of the left hand to provide slight cricoid pressure may help visualizing the vocal cords. The usual sizes of the tubes are as follows: adult male 8.5 mm, adult female 7.5 mm. Choosing the size for children under 10 years of age is governed by the formula: size = age/4 + 4. Correctly placed tube will result in lifting of the patient's thoracic cage when the air is pushed through the tube. Ensuring endotracheal position by the use of a CO<sub>2</sub> detector is a standard of care. The detector should change color (purple to yellow) by 5-6 breaths. Tube position is also checked by auscultation of both chest and abdomen to ensure equal aeration of both lungs. Endotracheal tube is secured with two pieces of 5 to 10mm long adhesive tape placed on lip and around the tube.

## **4. RESULTS**



During the period from October 2015 to February 2019, 135 PIRS procedures were performed in total. LM was used in 94 children (70%) while in the remaining 41 children (30%) TI was used. Both the clinical and demographic data are summarized in Table 2.

*Table 2. The demographic and clinical data of the patients*

	<b>Group I</b> <b>LARYNGEAL</b> <b>MASK AIRWAY</b> (n=94)	<b>Group II</b> <b>TRACHEAL</b> <b>INTUBATION</b> (n=41)	<i>P</i>
<b>Demographic data</b>			
Age (years) (median, IQR)	4 (2, 7)	3.5 (1, 6)	0.435*
Sex (M) (n, %) (F) (n, %)	70 (74%) 24 (26%)	27 (63%) 14 (37%)	0.306**
BMI (kg/m <sup>2</sup> ) (median, IQR)	16.4 (15.2, 17.3)	15.8 (14.2, 16.3)	0.548*
<b>Clinical data</b>			
Duration of surgery (min) (median, IQR)	10 (8, 15)	12 (8, 17)	0.968*
Duration of anaesthesia (min) (median, IQR)	25 (20, 30)	36 (28, 45)	<0.001*
ASA (n, %) ASA I ASA II	90 (96%) 4 (4%)	25 (93%) 2 (7%)	0.506**
Pneumoperitoneum (mmHg) (median, IQR)	8 (8, 8)	8 (8, 8)	0.968**
Complications (n, %)	3 (3%)	14 (34%)	<0.001**

\* Mann Whitney Test , \*\* chi-square test,

ASA=American Society of Anesthesiologists

Classification, BMI=Body Mass Index

The median age for patients in LM group was 4 years (IQR 2, 7 years) and for the intubated patients the median age was 3.5 years (IQR 1, 6 years) ( $P=0.435$ ) (Figure 8).

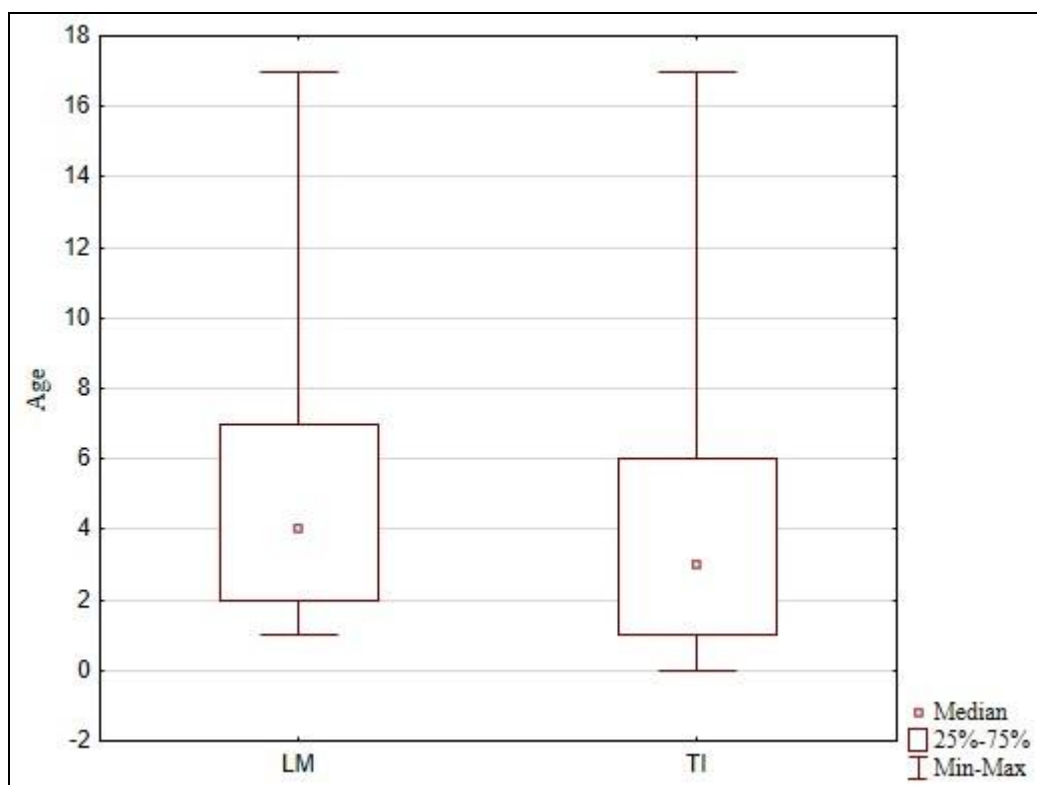


Figure 8. Distribution of patients regarding age between LM (n=94) and TI (n=41) groups

In both groups hernias were more prevalent in males, comprising 70 (74%) cases when using LM and 26 (63%) when TI was performed ( $P=0.306$ ) (Figure 9).

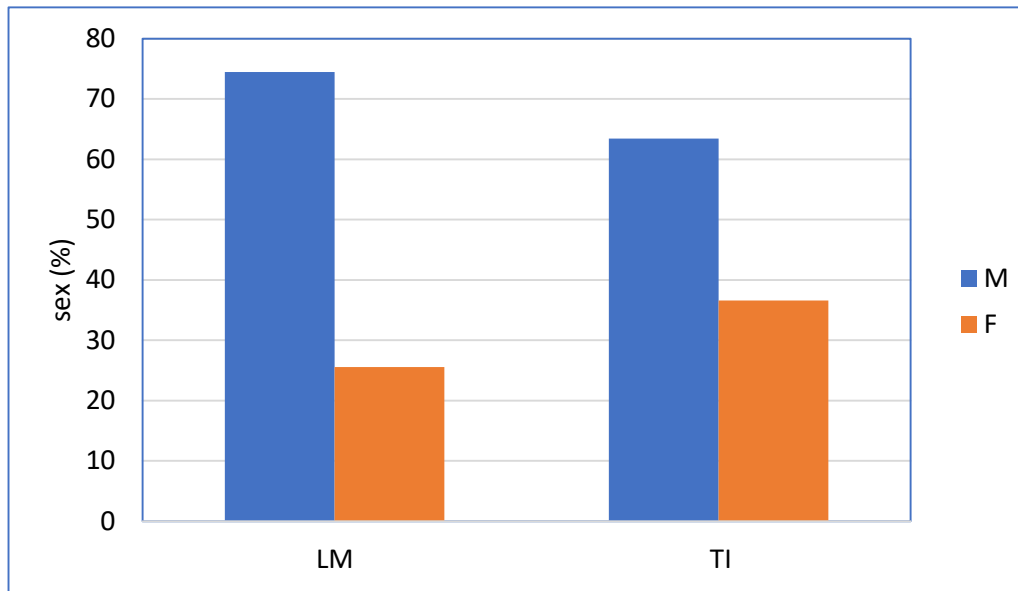


Figure 9. Distribution of patients regarding gender between LM ( $n=94$ ) and TI ( $n=41$ ) groups

The median BMI in LM group was  $16.4 \text{ kg/m}^2$  (IQR 15.2, 17.3) while in TI group the median BMI was  $15.8 \text{ kg/m}^2$  (IQR 14.2, 16.4) ( $P=0.548$ ) (Figure 10).

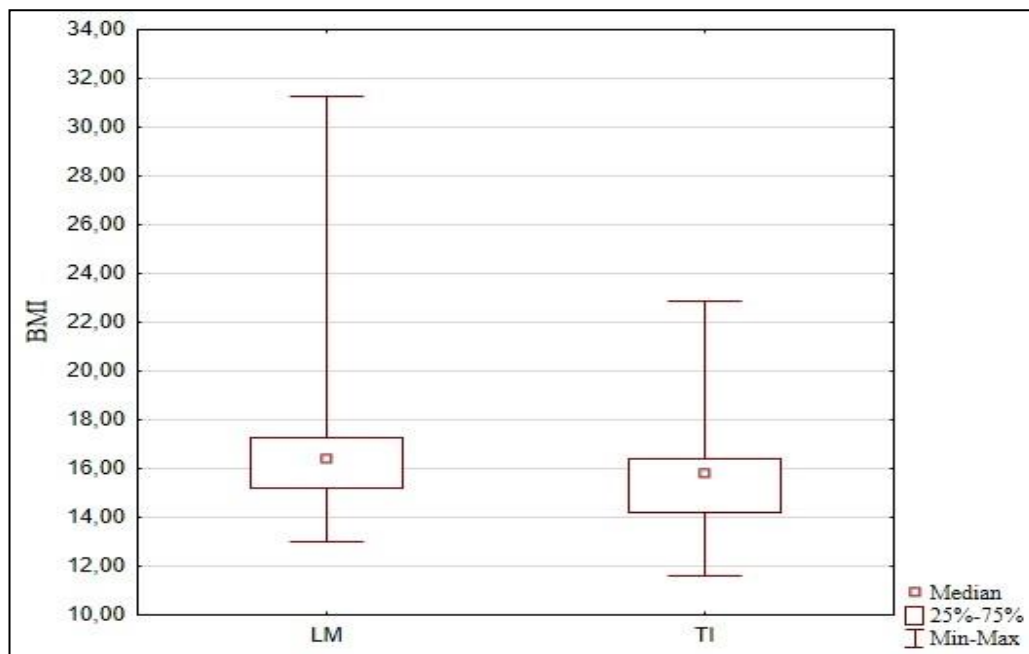


Figure 10. BMI distribution between LM ( $n=94$ ) and TI ( $n=41$ ) groups

The median duration of surgery was 10 min (IQR 8, 15) when LM was used and 12 min (IQR 8, 17) when the patient was intubated ( $P=0.968$ ) (Figure 11).

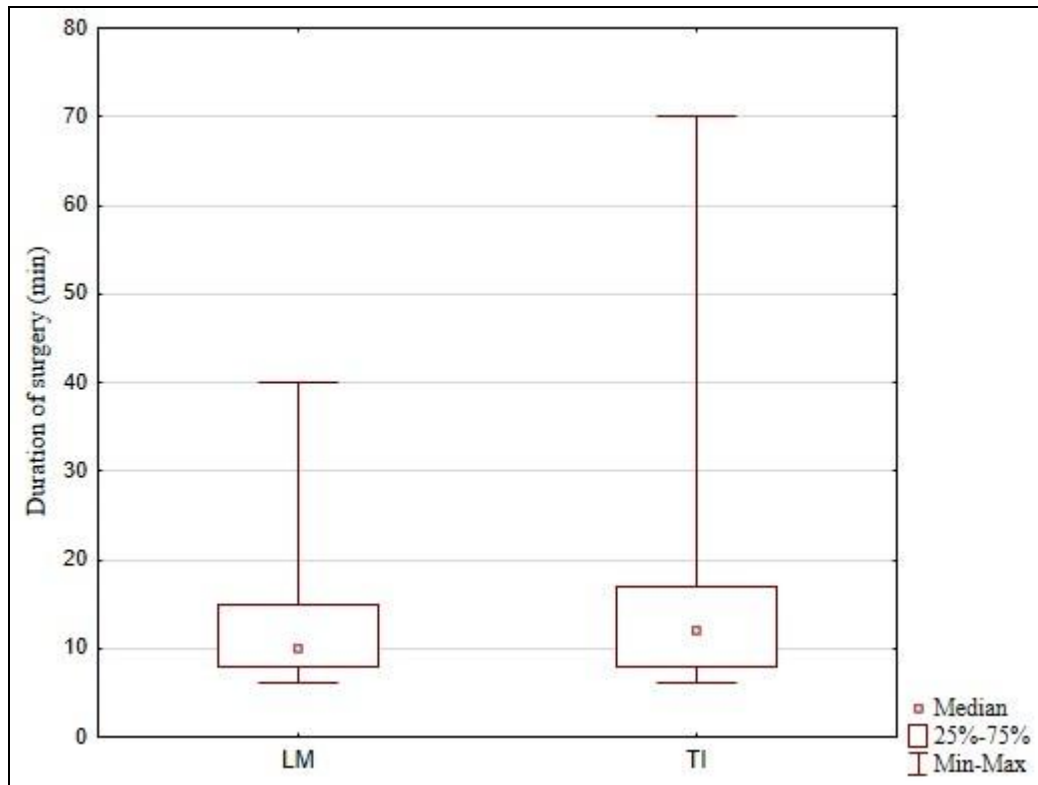


Figure 11. Comparison of duration of surgery between LM ( $n=94$ ) and TI ( $n=41$ ) groups

Duration of anesthesia was significantly shorter in LM group with the median time of 25 min (IQR 20, 30) compared to 36 min (IQR 28, 45) in TI group ( $P<0.001$ ) (Figure 12).

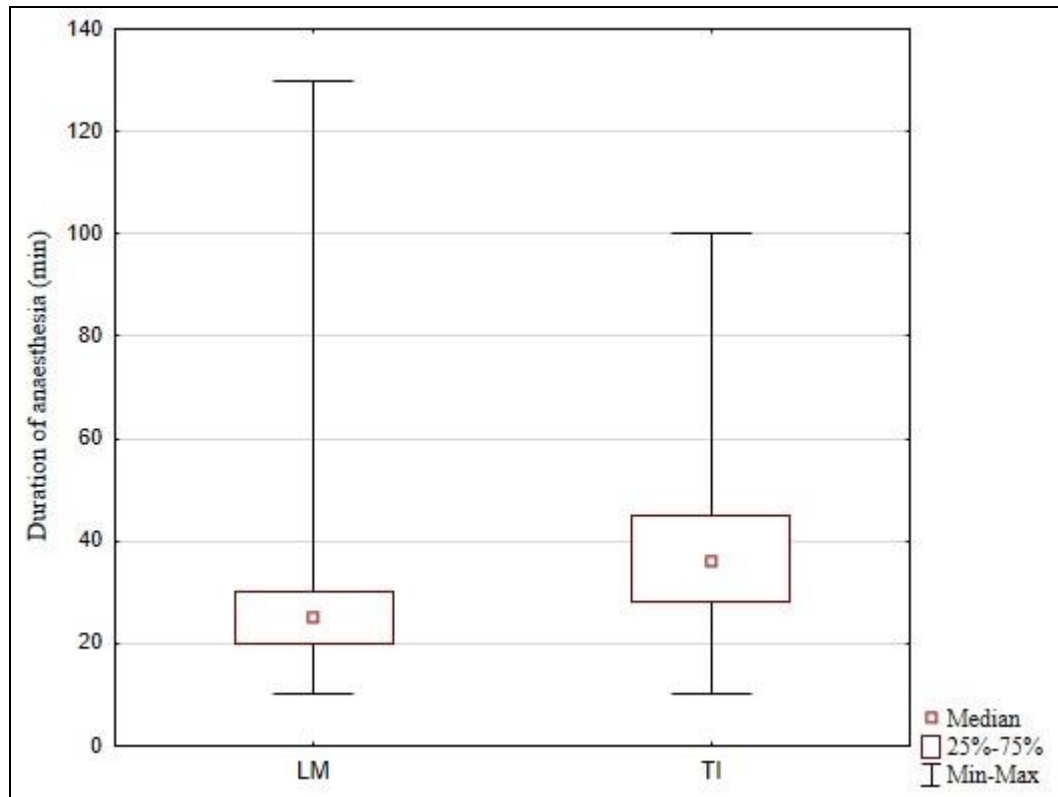


Figure 12. Comparison of duration of anesthesia between LM (n=94) and TI (n=41) groups

Both groups experienced the median level of pneumoperitoneum of 8 mmHg (IQR 8, 8) ( $P=0.968$ ). Number of patients classified as ASA I was 90 (96%) in the LM group and 25 (93%) in the TI group. ASA II patients numbered 4 (4%) in the first group and 2 (7%) in the latter mentioned group ( $P=0.506$ ) (Table 2).

Overall, the type of airway management significantly affected the frequency of certain complications. The incidence of postoperative laryngospasm was significantly lower in group where LM was used, compared to intubated patients ( $n=2$  vs.  $n=5$ ;  $P=0.015$ ). Furthermore, there was a significantly smaller frequency of desaturation ( $n=1$  vs  $n=5$ ;  $P=0.003$ ) and cough ( $n=0$  vs  $n=4$ ;  $P=0.002$ ) in patients using LM. There were no statistically significant differences in groups regarding complications such as sore throat ( $n=1$  vs  $n=1$ ;  $P=0.543$ ), bronchospasm ( $n=0$  vs  $n=1$ ;  $P=0.128$ ) and aspiration ( $n=0$  vs  $n=1$ ;  $P=0.128$ ) (Table 3, Figure 13).

Table 3. A comparison of the respiratory complications between two groups

Complication (n)	Group I	Group II	P*
	LARYNGEAL MASK AIRWAY (n=94)	TRACHEAL INTUBATION (n=41)	
Laryngospasm	2	5	<b>0.015</b>
Desaturation	1	5	<b>0.003</b>
Cough	0	4	<b>0.002</b>
Sore throat	1	1	0.543
Bronchospasm	0	1	0.128
Aspiration	0	1	0.128

\* chi-square test

Note: some patients had two or more complications

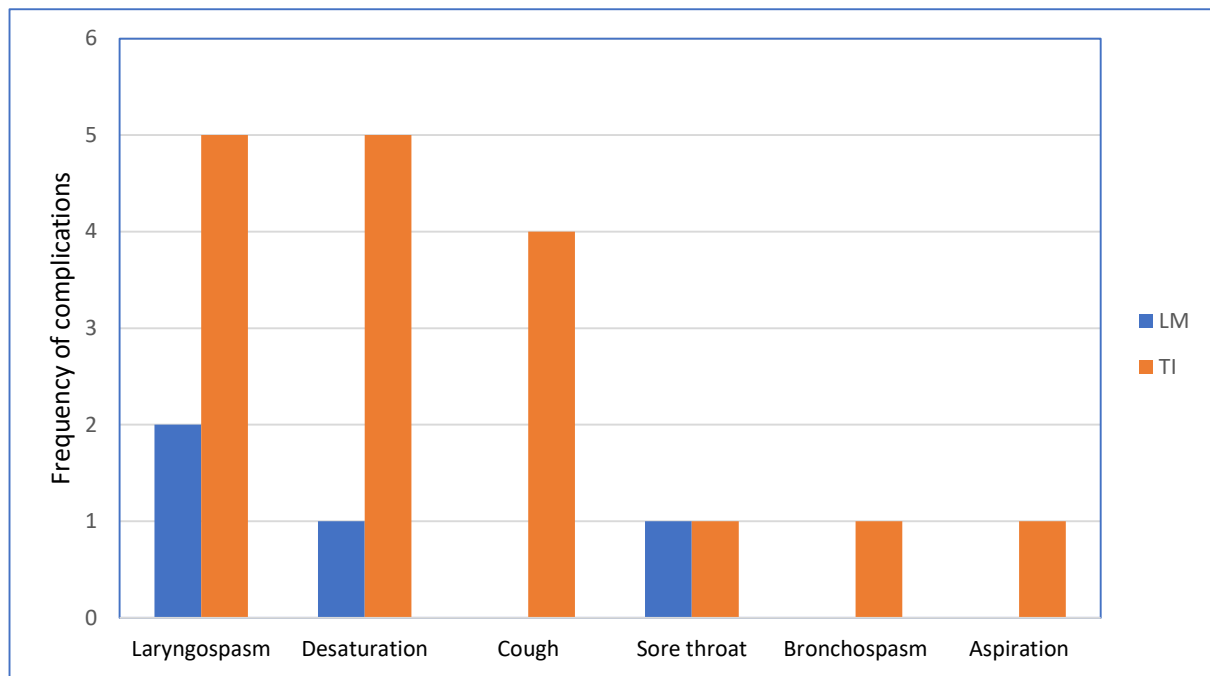


Figure 13. A comparison of the complications between LM (n=94) and TI (n=41) groups

## **5. DISCUSSION**

In this retrospective comparative study, we observed that percutaneous internal ring suturing using LM airway in children is a safe and successful surgical procedure with shorter duration of anesthesia and lesser frequency of both intraoperative and postoperative respiratory complications. In children undergoing short-lasting surgical procedures with low insufflation pressures, safe anesthesia management can be obtained using LM airway with no muscle relaxant. Our results are in agreement with few other studies and meta-analyses (28-32).

Nowadays two main airway management techniques are used. LM is easier to administer and generally used in shorter surgical procedures while TI provides easier airway control and is more commonly used in everyday practice. While both TI and LM airway devices can be used as airway management devices during conventional pediatric inguinal hernia repair, TI is generally preferred when laparoscopic hernia repair is performed. Although there are reports in literature of the safe use of LM airway in pediatric laparoscopic surgery (33-35) its use has not gained popularity (36). LM airway has been golden standard for many years in children for short-lasting surgical procedures where the patient is in the supine position. New LM models have been developed and their use has been increasing. Compared with TI the potential advantages of using an LM airway include rapid insertion without requiring laryngoscopy and a higher first attempt success rate, even among novice provider. Successful TI requires more complex training and evidence suggests that current trainees are not mastering this skill. Resuscitation procedures might be delayed and adverse outcomes might occur if endotracheal intubation cannot be rapidly implemented or if the proper tube position cannot be achieved.

Recently, more minimally invasive laparoscopic techniques for the repair of pediatric inguinal hernia with surgical times of 15–20 min have been reported (18-23). Low insufflation pressures and shorter anesthesia times have led to a review of the need for TI and muscle relaxants in these patients.

LM airway is now widely accepted as a valuable device for airway management during pediatric anesthesia and TI is considered to be safer when compared to LM in general anesthesia practices. Recently, LM has gained wide spread popularity among pediatric



anesthesiologists and is reported to be safely used in all age groups for various surgical procedures (37, 38).

The most common complications of aforementioned airway conduction are laryngospasm, bronchospasm, cough, desaturation, aspiration and a sore throat. With regards to the high rate of inguinal hernia it is of utmost importance to clarify which airway management technique results in fewer complications. The results of meta-analysis indicate that the incidences of postoperative desaturation, laryngospasm and cough are homogeneously decreased when LM airway is used instead of TI (31).

Laryngospasm, very common in pediatric patients, usually occurs when vocal cords are irritated by respiratory secretions or blood. Comparing postoperative laryngospasm incidence during LM airway and TI revealed significantly lower incidence of laryngospasm when using LM airway. This finding is in agreement with a meta-analysis conducted by Luce *et al.* (31) which also showed a number of other complications, like desaturation and sore throat, being less frequent when using LM, further confirming our results.

Aspiration, also a quite common complication, was proven not to differ in frequency when using LM or TI. Several studies (30-32) have also shown no dissimilarity in frequency when using LM. Aspiration is usually caused by increased intraabdominal pressure which leads to increased intragastric pressure. Our study did not follow the intragastric pressure values during surgeries but a study by Ozdamar *et al.* (33) which recorded the pressures both when using LM airway and TI, advocates LM application as a feasible anesthetic device in pediatric laparoscopic surgery.

We have noted that the duration of anesthesia was significantly shorter when using LM. This was unanimous with a study conducted by Ince *et al.* (30). The part of the reason for this lays in the fact that it takes less time to position a LM than it takes to intubate a patient. The abovementioned study showed no significant difference between the duration of surgery confirming our results that also showed no difference in duration no matter LM or TT was used.

It is worth mentioning that no muscular relaxant was used when LM was administered which probably shortened duration of anesthesia. The use of muscle relaxants in laparoscopic surgery offer increased visibility of the surgical field and decrease the risk of complications

because of patient movement while trocars or laparoscopic hand tools are in place. However, the use of muscle relaxants are associated with increased mortality and anesthesia-related complications (39). Recently studies have been reporting the safety of LM use in both adults and children (39, 40). A study by Chen *et al.* (41) asserts that no muscle relaxant is necessary in general anesthesia when using LM airway.

This study used a non-randomized comparison, which might be its biggest limitation. A larger number of patients might have also revealed a different frequency of complications in regards to different methods of anesthetic conduction. It is very important to emphasize that our study population is very specific group of patients, with median age of 4 years using an insufflation pressure of 6-8 mmH<sub>2</sub>O in surgeries lasting 10-12 min. Although we have satisfactory sample size anesthesia related complications are rare and would require a larger sample size to accurately determine. However, we believe that this study will form a basis for further research.

In conclusion, the use of LM airway with no muscle relaxant is a safe alternative to TI in short lasting lower abdominal procedures, although this may not be generalisable for all pediatric age groups or procedures. LM airway use during pediatric anesthesia results in a significant reduced incidence of postoperative desaturation, laryngospasm and cough.

## **6. CONCLUSION**

- 1) The use of LM in pediatric anesthesia leads to significantly lower incidence of postanesthetic complications such as desaturation, laryngospasm and cough.
- 2) There is no significant difference in postoperative incidences of sore throat, bronchospasm and aspiration between LM and TI.
- 3) Duration of anesthesia is significantly shorter when using LM in comparison to TI.
- 4) LM is a valuable device for the management of the pediatric airway for short lasting laparoscopic procedures in children such as hernia repair.

## **7. REFERENCES**

1. Moore KL, Dalley AF, Agur AMR. Abdomen. In: Moore KL, Dalley AF, Agur AMR, editors. Moore clinically oriented anatomy 7th ed. Toronto: Lippincott Williams & Wilkins. 2014. p. 201-15.
2. Vučkov Š, Kvesić A. Izabrana poglavlja iz dječje kirurgije. Rijeka: Medicinski fakultet; 2005.
3. Rowe MI, Copelson LW, Clatworthy HW. The patent processus vaginalis and the inguinal hernia. J Pediatr Surg. 1969;4:102-7.
4. Beard J, Ohene-Yeboah M, deVries C, Schechter W. Hernia and Hydrocele. Disease Control Priorities, Third Edition (Volume 1): Essential Surgery. 2015:151-71.
5. Fitzgibbons R, Forse R. Groin Hernias in Adults. N Engl J Med. 2015;372:756-63.
6. Pogorelić Z, Rikalo M, Jukić M, Katić J, Jurić I, Furlan D et al. Modified Marcy repair for indirect inguinal hernia in children: a 24-year single-center experience of 6826 pediatric patients. Surg Today. 2016;47:108-13.
7. Deveney KE. Hernias and other lesions of abdominal wall. In: Doherty GM, editor. Surgery 14th ed. Boston: McGraw-Hill Education; 2015. p. 768-70.
8. Van Wessem K, Simons M, Plaisier P, Lange J. The etiology of indirect inguinal hernias: congenital and/or acquired. Hernia. 2003;7:76-9.
9. Grosfeld JL. Current concepts in inguinal hernia in infants and children. World J Surg. 1989;13:506-15.
10. Fu Y, Pan M, Hsu Y, Chin T. A nationwide survey of incidence rates and risk factors of binguinal hernia in preterm children. Pediatr Surg Int. 2017;34:91-5.
11. Ein S, Njere I, Ein A. Six thousand three hundred sixty-one pediatric inguinal hernias: a 35-year review. J Pediatr Surg. 2006;41:980-6.
12. Goldstein R, Potts WJ. Inguinal hernia in female infants and children. Ann Surg. 1958;148:819-22.
13. Summers J. Classical herniorrhaphies of Bassini, Halsted and Ferguson. Am J Surg. 1947;73:87-99.

14. Yokomori K, Ohkura M, Kitano Y, Toyoshima H, Tsuchida Y. Modified Marcy repair of large indirect inguinal hernia in infants and children. *J Pediatr Surg.* 1995;30:97-100.
15. Šimunović N. A critical review of the Marcy operation for inguinal hernia in children. *Acta Chir Jugosl.* 1985;32:193-9.
16. Shalaby R, Ibrahim R, Shahin M, Abdelaziz Y, Abdalrazek M, Alsayaad I, et al. Laparoscopic hernia repair versus open herniotomy in children: a controlled randomized study. *Minim Invasive Surg.* 2012;2012:484135.
17. Iuamoto L, Kato J, Meyer A, Blanc P. Laparoscopic totally extraperitoneal (TEP) hernioplasty using two trocars: anatomical landmarks and surgical technique. *Arq Bras Cir Dig.* 2015;28:121-3.
18. Thomas DT, Göcmen KB, Tulgar S, Boga I. Percutaneous internal ring suturing is a safe and effective method for the minimal invasive treatment of pediatric inguinal hernia: experience with 250 cases. *J Pediatr Surg.* 2016;51:1330-5.
19. Patkowski D, Czernik J, Chrzan R, Jaworski W, Apoznański W. Percutaneous internal ring suturing: a simple minimally invasive technique for inguinal hernia repair in children. *J Laparoendosc Adv Surg Tech A.* 2006;16:513-7.
20. Pogorelić Z. Effects of laparoscopic hernia repair by PIRS (percutaneous internal ring suturing) technique on testicular artery blood supply. *J Investig Surg.* 2018;12:1-2.
21. Chen Y, Wang F, Zhong H, Zhao J, Li Y, Shi Z. A systematic review and meta-analysis concerning single-site laparoscopic percutaneous extraperitoneal closure for pediatric inguinal hernia and hydrocele. *Surg Endosc.* 2017;31:4888-901.
22. Wang F, Zhong H, Chen Y, Zhao J, Li Y, Chen J, et al. Single-site laparoscopic percutaneous extraperitoneal closure of the internal ring using an epidural and spinal needle: excellent results in 1464 children with inguinal hernia/hydrocele. *Surg Endosc.* 2017;31:2932-8.
23. Jukić M, Pogorelić Z, Šupe-Domić D, Jerončić A. Comparison of inflammatory stress response between laparoscopic and open approach for pediatric inguinal hernia repair in children. *Surg Endosc.* 2018. doi: 10.1007/s00464-018-06611-y.

24. Barash PG, Cullen BF, Stoelting RK, Cahalan MK, Stock MK. Clinical Anesthesia. 6th ed. Philadelphia: Lippincott Williams & Wilkins; 2009.
25. Morgan GE. Airway Management. In: Morgan GE, Maged MS, Micheal MJ, editors. Clinical Anesthesiology. 4th ed. New York: McGraw-Hill Medical; 2005. p. 91-110.
26. Gormley SMC, Crean MB. Basic principles of anaesthesia for neonates and infants. Br J Anaesth. 2001;1:130-3.
27. Sandberg K, Sjoqvist B, Hjalmarson O, Olsson T. Analysis of alveolar ventilation in the newborn. Arch Dis Child. 1984;59:542-7.
28. Tulgar S, Boga I, Cakiroglu B, Thomas D. Short-lasting pediatric laparoscopic surgery: Are muscle relaxants necessary? Endotracheal intubation vs. laryngeal mask airway. J Pediatr Surg. 2017;52:1705-10.
29. Vora K, Shah V, Patel D, Modi M, Parikh G. Sevoflurane versus propofol in the induction and maintenance of anaesthesia in children with laryngeal mask airway. Sri Lanka Journal of Child Health. 2014;43:77-83.
30. İnce İ, Ahiskalioglu E, Oral A, Aksoy M, Yiğiter M, Celikkaya M, et al. Is neuromuscular blocker necessary in pediatric patients undergoing laparoscopic inguinal hernia repair with percutaneous internal ring suturing. Eur J Pediatr Surg. 2016;27:263-8.
31. Luce V, Harkouk H, Brasher C, Michelet D, Hilly J, Maesani M, et al. Supraglottic airway devices vs tracheal intubation in children: a quantitative meta-analysis of respiratory complications. Paediatr Anaesth. 2014;24:1088-98.
32. Aydogmus M, Turk H, Oba S, Unsal O, Sınıkoglu S. Can Supreme™ laryngeal mask airway be an alternative to endotracheal intubation in laparoscopic surgery. Braz J Anesthesiol. 2014;64:66-70.
33. Ozdamar D, Güvenç BH, Toker K, Solak M, Ekingen G. Comparison of the effect of LMA and ETT on ventilation and intragastric pressure in pediatric laparoscopic procedures. Minerva Anesthesiol. 2010;76:592-9.



34. Mironov PI, Estekhin AM, Mirasov AA. Anaesthetic maintenance with laryngeal mask for a laparoscopic surgery in pediatric patients. *Anesteziol Reanimatol.* 2013;1: 10-4.
35. Sinha A, Sharma B, Sood J. ProSeal as an alternative to endotracheal intubation in pediatric laparoscopy. *Paediatr Anaesth.* 2007;17:327-32.
36. Patel A, Clark SR, Schiffmiller M, Schoenberg C, Tewfik G. A survey of practice patterns in the use of laryngeal mask by pediatric anesthesiologists. *Paediatr Anaesth.* 2015;25:1127-31.
37. Sanket B, Ramavakoda CY, Nishtala MR, Ravishankar CK, Ganigara A. Comparison of second-generation supraglottic airway devices (i-gel versus LMA ProSeal) during elective surgery in children. *AANA J.* 2015;83:275-80.
38. Yao T, Yang X-L, Zhang F, Li N, DU HQ, Wang DX, et al. The feasibility of supreme laryngeal mask airway in gynecological laparoscopy surgery. *Zhonghua Yi Xue Za Zhi.* 2010;90:2048-51.
39. Timmermann A, Bergner UA, Russo SG. Laryngeal mask airway indications: new frontiers for second-generation supraglottic airways. *Curr Opin Anaesthesiol.* 2015;28:717-26.
40. Ledowski T. Muscle relaxation in laparoscopic surgery: what is the evidence for improved operating conditions and patient outcome? A brief review of the literature. *Surg Laparosc Endosc Percutan Tech.* 2015;25:281-5.
41. Chen B, Tan L, Zhang L, Shang Y. Is muscle relaxant necessary in patients undergoing laparoscopic gynecological surgery with a ProSeal LMTM?. *J Clin Anesth.* 2013;25:32-5.

## 8. SUMMARY

**Background:** Rate of perioperative respiratory complications between TI (tracheal intubation) and LM (laryngeal mask) airway remains unclear during pediatric anesthesia. The aim of this study was to compare the perioperative and postoperative respiratory complications between LM and TI in children undergoing percutaneous internal ring suturing (PIRS) for inguinal hernia.

**Methods:** From October 2015 to February 2019, 135 pediatric patients (97 males and 38 females) with median age of 4 years, who underwent PIRS for inguinal hernia were included in study. Patients were divided in two groups. In group I (n=94) LM airway was used, and in group II (n=41) TI was performed. Demographic data, surgical and anesthesia times, ASA (American Society of Anesthesiologists) classification, muscle relaxation, level of pneumoperitoneum and complications of anesthesia were compared between the groups.

**Results:** There were no significant differences between the two groups regarding age ( $P=0.435$ ), sex ( $P=0.306$ ), BMI ( $P=0.548$ ), ASA classification ( $P=0.506$ ), level of pneumoperitoneum ( $P=0.968$ ) and duration of surgery ( $P=0.968$ ). Duration of anesthesia was significantly shorter when LM was used compared to TI (25 min vs 36 min;  $P<0.001$ ). During recovery from anesthesia, the incidences of desaturation (n=1 vs n=5;  $P=0.003$ ), laryngospasm (n=2 vs n=5;  $P=0.015$ ) and cough (n=0 vs n=4;  $P=0.002$ ) were significantly lower when LM airway was used to secure the airway. Postoperative incidences of sore throat (n=1 vs n=1;  $P=0.543$ ), bronchospasm (n=0 vs n=1;  $P=0.128$ ) and aspiration (n=0 vs n=1;  $P=0.128$ ) did not differ between LM and TI.

**Conclusions:** The use of LM in pediatric anesthesia results in a decrease in a number of common postanesthetic complications and significantly shortened patient anesthesia time. It is therefore a valuable device for the management of the pediatric airway for laparoscopic hernia repair in children.

## **9. SUMMARY IN CROATIAN**

## **Korištenje laringealne maske i trahealne intubacije prilikom laparaskopske operacije kile u djece: analiza dišnih komplikacija**

**Cilj istraživanja:** Stopa perioperacijskih respiracijskih komplikacija prilikom korištenja laringealne maske i endotrahealnog tubusa tijekom anestezije u djece ostaje nepoznanica. Cilj ovog istraživanja bio je usporediti perioperacijske i poslijeoperacijske respiracijske komplikacije između anestezije laringealnom maskom i endotrahealnim tubusom u djece podvrgnute laparaskopski asistiranoj operaciji perkutanog šivanja unutarnjeg prstena ingvinalnog kanala (PIRS) zbog preponske kile.

**Ispitanici i metode:** U razdoblju od listopada 2015. do veljače 2019., 135 djece (97 dječaka i 38 djevojčica) medijana dobi od 4 godine, koja su podvrgnuta PIRS operaciji zbog ingvinalne hernije uključeno je u ovo istraživanje. Bolesnici su podijeljeni u dvije skupine. U Skupini I (n=94) tijekom anestezije koristila se laringealna maska, dok se u Skupini II (n=41) koristio endotrahealni tubus. Demografski podaci, vremena trajanja operacije i anestezije, ASA (*American Society of Anesthesiologists*) klasifikacija, relaksacija mišića, razina pneumoperitoneuma i komplikacije anestezije uspoređeni su između dvije ispitivane skupine.

**Rezultati:** Nije bilo statistički značajnih razlika između dvije skupine u dobi ( $P=0,435$ ), spolu ( $P=0,306$ ), BMI-u ( $P=0,548$ ), ASA klasifikaciji ( $P=0,506$ ), razini pneumoperitoneuma ( $P=0,968$ ) i duljini trajanja operacije ( $P=0,968$ ). Duljina trajanja anestezije bila je značajno kraća prilikom korištenja laringealne maske u usporedbi s endotrahealnim tubusom (25 min i 36 min;  $P<0,001$ ). Tijekom oporavka od anestezije, stope desaturacije (n=1 i n=5;  $P=0,003$ ), laringospazma (n=2 i n=5;  $P=0,015$ ) i kašlja (n=0 i n=4;  $P=0,002$ ) bile su značajno niže kada se koristila laringealna maska. Poslijeoperacijske stope grlobolje (n=1 i n=1;  $P=0,543$ ), bronhospazma (n=0 i n=1;  $P=0,128$ ) i aspiracije (n=0 i n=1;  $P=0,128$ ) nisu se razlikovale između ispitivanih skupina.

**Zaključci:** Korištenje laringealne maske tijekom anestezije u djece rezultira smanjenjem broja niza poslijeoperacijskih komplikacija te smanjenjem duljine trajanja anestezije. Laringealna maska pokazala se vrlo korisnom i učinkovitom prilikom laparaskopske hernioplastike u djece.

## **10. CURRICULUM VITAE**

**PERSONAL INFORMATION**

NAME AND SURNAME: Josip Vickov

DATE AND PLACE OF BIRTH: July 20th 1993, Split

NATIONALITY: Croatian

CURRENT ADDRESS: Templarska 14, 21000 Split, Croatia

E-MAIL: josip\_vickov@hotmail.com

**EDUCATION**

1999 – 2007. Osnovna škola „Kamen-Šine“

2007. – 2011. Prva gimnazija Split, jezični smjer

2013. – 2019. Medical Studies in English at the University of Split, School of Medicine

**OTHER**

Languages: English, Italian

Category „B“ driver

Amateur handball player