

Pneumatic vitreolysis using the Drinking bird technique for management of vitreomacular traction : A prospective, non-randomized, open-label, single-arm, interventional pilot study

Kowalski, Martin

Master's thesis / Diplomski rad

2019

Degree Grantor / Ustanova koja je dodijelila akademski / stručni stupanj: **University of Split, School of Medicine / Sveučilište u Splitu, Medicinski fakultet**

Permanent link / Trajna poveznica: <https://urn.nsk.hr/urn:nbn:hr:171:114777>

Rights / Prava: [In copyright / Zaštićeno autorskim pravom.](#)

Download date / Datum preuzimanja: **2024-04-16**



Repository / Repozitorij:

[MEFST Repository](#)



UNIVERSITY OF SPLIT



**UNIVERSITY OF SPLIT
SCHOOL OF MEDICINE**

Martin Kowalski

**PNEUMATIC VITREOLYSIS USING THE DRINKING BIRD
TECHNIQUE FOR MANAGEMENT OF VITREOMACULAR
TRACTION. A PROSPECTIVE, NON-RANDOMIZED,
OPEN-LABEL, SINGLE-ARM, INTERVENTIONAL PILOT STUDY**

Diploma thesis

Academic year:

2018/2019

Mentor:

Assist. Prof. Ljubo Znaor, MD, PhD

Split, July 2019

TABLE OF CONTENTS

ACKNOWLEDGEMENTS

LIST OF ABBREVIATIONS

1. INTRODUCTION	1
1.1. POSTERIOR VITREOUS DETACHMENT	2
1.2. CLASSIFICATION OF VITREOMACULAR INTERFACE DISEASE	3
1.3. DIAGNOSIS OF VMT	6
1.4. MANAGEMENT OF VMT	8
2. OBJECTIVES	11
3. MATERIALS AND METHODS	13
3.1. ETHICAL APPROVAL & PROTOCOL REGISTRATION	14
3.2. PATIENT POPULATION	14
3.3. OUTCOME MEASURES	15
3.4. SURGICAL PROCEDURE	15
3.5. OPHTHALMOLOGIC EXAMINATION AND DATA COLLECTION	15
3.6. STATISTICAL ANALYSIS	16
4. RESULTS	17
5. DISCUSSION	23
6. CONCLUSIONS	27
7. REFERENCES	29
8. SUMMARY	35
9. CROATIAN SUMMARY	37
10. CURRICULUM VITAE	39

ACKNOWLEDGEMENTS

I would like to express my deep gratitude to Assist. Prof. Ljubo Znaor, my mentor, for his inspiring guidance, enthusiastic encouragement and the valuable and constructive suggestions not only for this research work, but also for my further career choices.

I would also like to thank Dr. Ante Basic for his assistance and great support in both the planning and the conduction of this research. My thanks are also extended to Dr. Bosko Jaksic for his assistance in the preparation of this study.

I would like to offer my special thanks to Prof. Kajo Bucan, head of the Department of Ophthalmology at the University hospital of Split, for allowing the conductance of this study at his Department.

Also the help and assistance of the involved nurses during parts of the study conductance and of course the willingness of participants to enroll are to be acknowledged.

I wish to acknowledge the support and encouragement of my fellow colleagues and friends, who made my student times not only more productive, but also more enjoyable making me experience the importance of values, such as companionship and collegiality.

Finally, I wish to thank my parents and family for their exceptional support throughout my studies.

LIST OF ABBREVIATIONS

AMD – Age-related macular degeneration
BCVA – best-corrected visual acuity
C3F8 – perfluoropropane
CFT – central foveal thickness
CME – cystoid macular edema
DR – diabetic retinopathy
ERM – epiretinal membrane
FDA – food and drug administration
FTMH – full-thickness macular hole
ILM – internal limiting membrane
IOP – intraocular pressure
IVTS – international vitreomacular traction study group
LMH – lamellar macular hole
MP – macular puckers
OCT – optical coherence tomography
PPV – pars-plana-vitrectomy
PVD – posterior vitreous detachment
RPE – retinal pigment epithelium
SD-OCT – spectral domain optical coherence tomography
SF6 – sulfur hexafluoride
SLO – scanning laser ophthalmoscope
sVMT – symptomatic vitreomacular traction
VA – visual acuity
VMA – vitreomacular adhesion
VMI – vitreomacular interface
VMT – vitreomacular traction
VMTS – vitreomacular traction syndrome

1. INTRODUCTION

1.1. POSTERIOR VITREOUS DETACHMENT

The cell adhesion proteins laminin and fibronectin fix the posterior vitreous body to the internal limiting membrane (ILM) of the retina (1). Vitreous collagen fibers pass at the vitreous base directly through the ILM communicating with retinal collagen (2). Henrich *et al.* showed that this communication between retina and vitreous body varies at different locations. The attachment is stronger at the vitreous base, optic disc, fovea and along major retinal blood vessels (3). The detachment of vitreous body from the ILM is a common condition in the aging eye, most often resulting in complete vitreoretinal separation.

With increasing age this physiological process of posterior vitreous detachment (PVD) increases as well. Focal perifoveal PVD occurs in half of 30-39 year-old subjects. In at least 60% of the population complete detachment can be shown by the age-range of 80-90 (4-6). The first stage in the development of the full-blown synchysis senilis is an age-related vitreous gel liquefaction leading to the formation of fluid-filled cavities, which subsequently condensate (syneresis) (7). The result is a dehiscence in the cortical gel and/or posterior hyaloid membrane (8). The process of PVD can be divided into 5 stages, which can nicely be observed with the help of OCT. Stage 0 means that there is no dehiscence and no signs of detachment at all. First small areas of detachment occur most commonly in the perifovea, especially in the superior quadrants. These mark the onset of stage 1 PVD. In stage 2 these areas of detachment extend further into the perifovea, but attachment to the fovea itself and the optic nerve head persists. With detachment from the fovea, but still persistent attachment to the optic nerve head and the posterior surface of the eye one grades the OCT-finding as stage 3 PVD. And finally the complete detachment of the vitreous body from fovea, the optic nerve head, and the entire posterior eye surface is categorized as stage 4 PVD (Figure 1) (1).

Patients often don't experience any symptoms, but in up to 27% of cases complications may occur (9). Hence one can characterize PVD as either symptomless and physiologic or symptomatic and anomalous, disturbing a patient's visual perception. The perception of floaters, few small spots becoming dense upon time, is termed myodaeopsia or muscae volitantes in Latin (10). They are especially prominent while looking at something bright and pale, e.g. a white wall or the clear blue sky. Photopsia, often described as a lightning-like arc induced by eye or head movement and prominent in dim conditions, is another common finding. And a third accompanying symptom is sometimes also blurred vision together with a reduction in visual acuity (VA) due to dispersed haemorrhage within the vitreous gel. An incomplete or anomalous dehiscence of central macula and optic nerve head may lead to a range of macular conditions. Spectral Domain Optical coherence

tomography (SD-OCT) comprises the method of choice for differentiation of these diseases of the vitreomacular interface (11, 12).

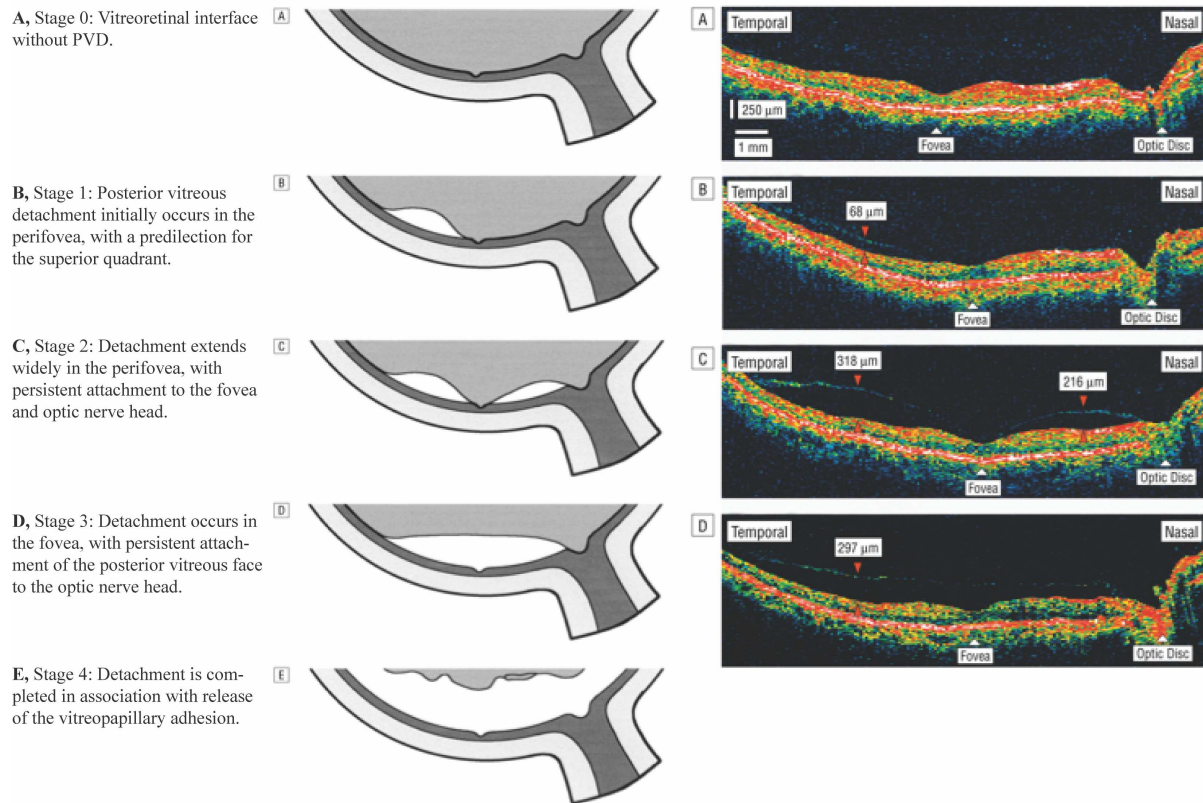


Figure 1. Development of age-related PVD as seen by OCT – schematic and respective OCT-finding. From: Initial Stages of Posterior Vitreous Detachment in Healthy Eyes of Older Persons Evaluated by Optical Coherence Tomography (1)

1.2. CLASSIFICATION OF VITREOMACULAR INTERFACE DISEASE

Vitreomacular traction (VMT) syndrome is a disturbance of the vitreo-retinal interface. Necessary for a diagnosis of VMTS are an incomplete posterior vitreous detachment (PVD), a strong attachment of the hyaloid to the macula as well as a resultant anteroposterior traction exerted by the synergetic vitreous pulling motion at sites adhering to the macula (13). Morphologic changes and functional effects can be the consequence (14). In 2013, the International Vitreomacular Traction Study (IVTS) Group developed an optical coherence tomography (OCT)-based anatomic classification system for diseases of the vitreo-retinal interface (15).

Table 1. Classification of vitreomacular interface disease according to IVTS-Group. From: Duker *et al.* The International Vitreomacular Traction Study Group Classification of Vitreomacular Adhesion, Traction, and Macular Hole (15)

Anatomic State	IVTS Classification System for Vitreomacular Adhesion, Traction, and Macular Hole
VMA	<p>Definition</p> <ul style="list-style-type: none"> Evidence of perifoveal vitreous cortex detachment from the retinal surface Macular attachment of the vitreous cortex within a 3-mm radius of the fovea No detectable change in foveal contour or underlying retinal tissues <p>Classification</p> <ul style="list-style-type: none"> By size of attachment area <ul style="list-style-type: none"> Focal ($\leq 1500 \mu\text{m}$) Broad ($>1500 \mu\text{m}$, parallel to RPE and may include areas of dehiscence) By presence of concurrent retinal conditions <ul style="list-style-type: none"> Isolated Concurrent
VMT	<p>Definition</p> <ul style="list-style-type: none"> Evidence of perifoveal vitreous cortex detachment from the retinal surface Macular attachment of the vitreous cortex within a 3-mm radius of the fovea Association of attachment with distortion of the foveal surface, intraretinal structural changes, and/or elevation of the fovea above the RPE, but no full-thickness interruption of all retinal layers <p>Classification</p> <ul style="list-style-type: none"> By size of attachment area <ul style="list-style-type: none"> Focal ($\leq 1500 \mu\text{m}$) Broad ($>1500 \mu\text{m}$, parallel to RPE and may include areas of dehiscence) By presence of concurrent retinal conditions <ul style="list-style-type: none"> Isolated Concurrent
FTMH	<p>Definition</p> <ul style="list-style-type: none"> Full-thickness foveal lesion that interrupts all macular layers from the ILM to the RPE <p>Classification</p> <ul style="list-style-type: none"> By size (horizontally measured linear width across hole at narrowest point, not ILM) <ul style="list-style-type: none"> Small ($\leq 250 \mu\text{m}$) Medium ($>250 \mu\text{m}$ and $\leq 400 \mu\text{m}$) Large ($>400 \mu\text{m}$) By presence or absence of VMT By cause <ul style="list-style-type: none"> Primary (initiated by VMT) Secondary (directly due to associated disease or trauma known to cause macular hole in the absence of prior VMT)
LMH	<p>Definition</p> <ul style="list-style-type: none"> Irregular foveal contour Defect in the inner fovea (may not have actual loss of tissue) Intraretinal splitting (schisis), typically between the outer plexiform and outer nuclear layers Maintenance of an intact photoreceptor layer
Macular Pseudohole	<p>Definition</p> <ul style="list-style-type: none"> Invaginated or heaped foveal edges Concomitant ERM with central opening Steep macular contour to the central fovea with near-normal central foveal thickness No loss of retinal tissue

Abbreviations: ERM = epiretinal membrane; FTMH = full-thickness macular hole; ILM = internal limiting membrane; IVTS = International Vitreomacular Traction Study; LMH = lamellar macular hole; RPE = retinal pigment epithelium; VMA = vitreomacular adhesion; VMT = vitreomacular traction.

1.2.1. Vitreomacular adhesion (VMA)

Evidence of partial vitreous detachment in the perifoveal area on at least one OCT finding points towards two entities, namely VMA and VMT (16). Both VMA and VMT show the hyaloid attachment to the macula within a radius of at least 3mm from the fovea, as well as an angle between retinal surface and posterior hyaloid, but unlike in VMT, there is no traction and therefore no change in the foveal contour nor any other retinal morphological changes (15). In fact the condition is benign, patients are asymptomatic and a watchful waiting approach is indicated (17).

1.2.2. Vitreomacular Traction (VMT)/Vitreomacular Traction Syndrome (VMTS)

Historically, Irvine described the “vitreous tug syndrome” after cataract surgery in 1953. Following cataract extraction vitreous incarceration at the corneal wound sites would occur leading to cystoid macular edema from vitreomacular traction (18). A few years later in 1967, Jaffe described a distinct “vitreoretinal traction syndrome” in 14 phakic patients (19). Reese *et al.* then studied the changes in VMT occurring at the macula. They incorporated Irvine’s and Jaffe’s descriptions into a spectrum of disease, with aphakia being a risk factor possibly leading to more severe changes through extra traction (14). Finally, Reese *et al.* provided histopathologic proof in 1970, confirming “vitreomacular traction syndrome” (13).

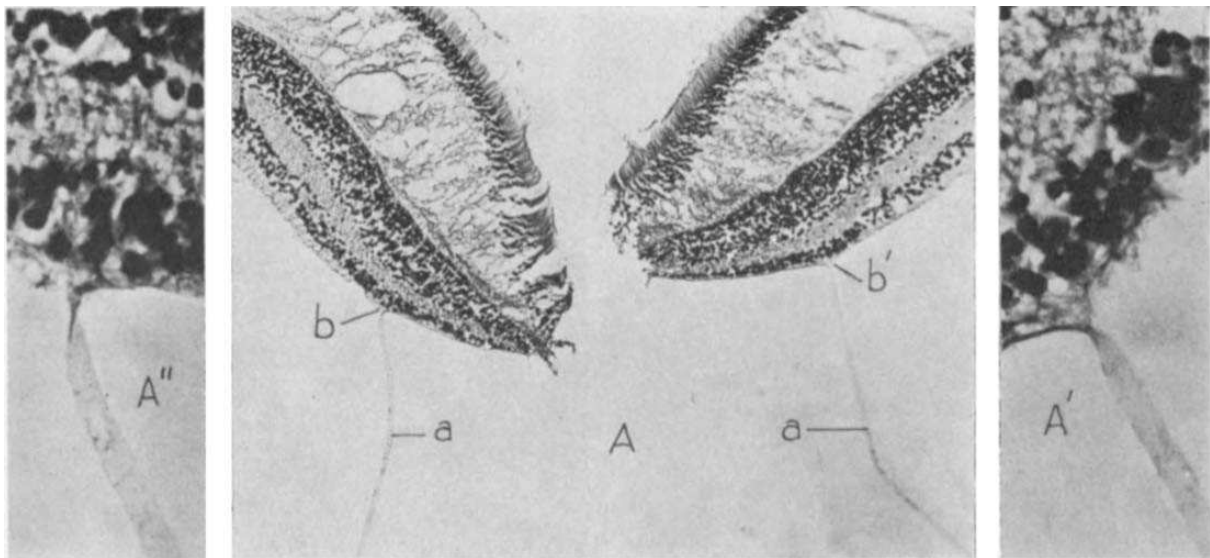


Figure 2. A section through the fovea shows the partially detached posterior hyaloid with persistent attachment to the internal limiting membrane in the foveal region; A: Centre; detached hyaloid membrane (a), still attached to the internal limiting membrane (b & b') at the macula. From: Reese AB, Jones IS, Cooper WC. Vitreomacular traction syndrome confirmed histologically (13)

The IVTS Group defines the presence of retinal changes on OCT with evident perifoveal PVD leading to a distorted foveal surface contour as Vitreomacular Traction (VMT) (15). Traction occurs due to the persistent attachment of the posterior hyaloid to the macula and blood vessels on the posterior surface (20). VMT is, according to the IVTS Group, further sub-classified based on the measured adhesion length of the vitreous cortex to

the macula into focal and broad VMT (15). Focal VMT hereby, means an adhesion length of no more than 1500µm, whereas broad VMT is an adhesion of more than 1500µm (Table 1). The IVTS Group further differentiates isolated VMT, when no other macular comorbidity is found, and concurrent VMT, in which other conditions of the macula, e.g. diabetic macular edema, occur together with VMT (15, 20).

1.3. DIAGNOSIS OF VMT

The Diagnosis of vitreoretinal interface diseases comprises a broad palette of diagnostic methods. Ophthalmoscopy, biomicroscopy, visual function tests (e.g. Amsler test, Watzke-Allen test, laser beam test, microperimetry), ultrasonography in both A and B mode all have their role in the diagnostic workup (17). However most crucial instruments today are modern imaging technologies, such as the very sensitive spectral domain OCT with confocal scanning laser ophthalmoscope (SD-OCT/SLO) (21). Of course also older generations of OCT can be used for a proper diagnosis (16).

1.3.1. Symptoms

Symptoms of VMT comprise mainly a decreased reading vision, but less metamorphosia than in patients with macular puckers (MP) (9, 22). Sometimes patients describe micropsia and photopsia (9, 23). Metamorphopsia is a term for the distortion of perceived images, whereas micropsia stands for the decrease in the image size, usually due to the spreading apart of foveal cones. Traction on the retina from the detaching vitreous causes photopsia meaning the perception of flashing lights (10, 17).

1.3.2. Signs

Binocular stereoscopic biomicroscopy is often challenging, especially in cases with a broad area of attachment (>1500µm). The diagnosis can often only be presumed when findings of retinal surface thickening, wrinkling and distortion, cystoid macular edema, foveal pseudocyst, macular schisis or detachment, and capillary leakage are present. A whitish band or reflex resembling the limits of the attached vitreous may be seen. These changes may be very subtle and the diagnosis can often only be presumed. In fact key to diagnosis are OCT results.

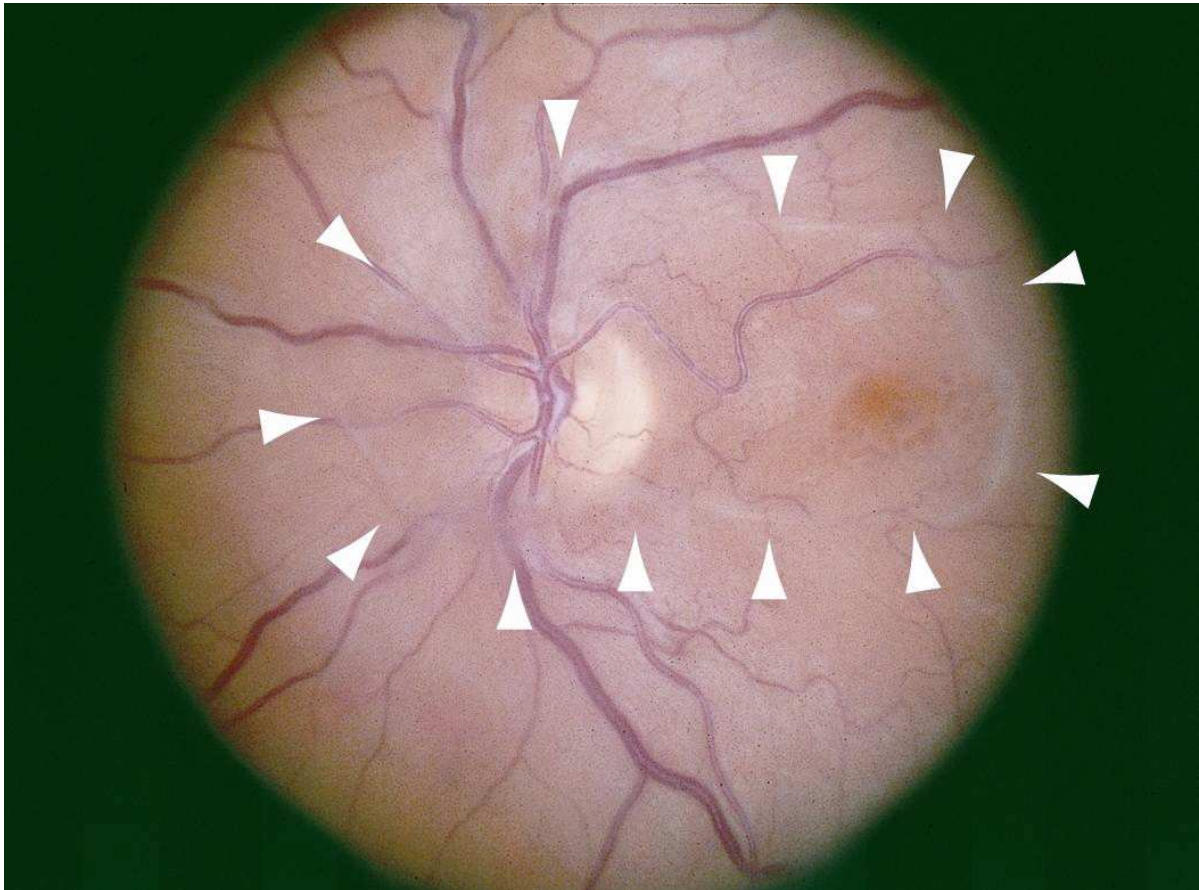


Figure 3. Fundus photograph in a patient with vitreomacular traction syndrome showing a whitish glistening translucent outline of vitreomacular attachment sites (arrowheads) involving the macula and the peripapillary retina. (c) 2013 American Academy of Ophthalmology. Available from: https://eyewiki.aao.org/Vitreomacular_Traction_Syndrome#cite_note-ref11-11.

1.3.3. OCT

Due to the development and use of high-resolution optical coherence tomography (Spectral-Domain-OCT, SD-OCT) a causal connection between persistent vitreomacular adhesions and the development of diverse macular diseases could be established (24). When there is a clinical suspicion of vitreomacular traction syndrome, OCT has been shown to be very helpful not only in establishing a diagnosis, but also in the follow-up of patients, who came to attention (25, 26). Reasonably the IVTS-group based their definitions on OCT-findings.

As already shown and described above, findings show perifoveal PVD with macular attachment of cortex within a foveal radius of 3mm. Distortion of foveal surface, intraretinal changes or foveal elevation above RPE may be present. Focal VMT involves an area of

attachment of <1500µm diameter, and broad VMT an area of >1500µm diameter (8, 12, 15). Concurrent VMT is associated with other macular disease, eg. AMD, DR, etc.. In isolated VMT there is no other macular disease present (15, 16).

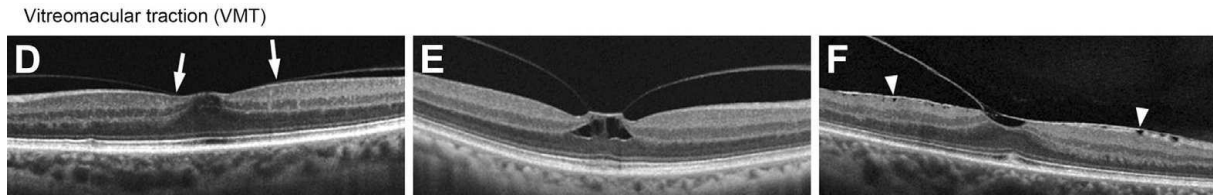


Figure 3. Optical coherence tomography (OCT) scans showing vitreomacular traction (VMT) according to the IVTS Classification System for Vitreomacular Adhesion, Traction, and Macular Hole. (D) Focal VMT; (E) Focal VMT with intrafoveal pseudocyst; (F) Broad VMT From: Duker et al. The International Vitreomacular Traction Study Group Classification of Vitreomacular Adhesion, Traction, and Macular Hole (15)

1.3.4. Differential Diagnosis

Similar clinical features can be observed in early full thickness macular holes, pseudophakic cystoid macular edema (CME), but also other reasons for CME, such as diabetic macular edema or exudative age-related macular degeneration (AMD) have to be considered and excluded if appropriate (27). The fundoscopic appearance (Figure 3) can easily be mistaken for an ERM. OCT brings clarity if one is unsure based on other clinical features and examinations.

1.4. MANAGEMENT OF VMT

Currently observation and watchful-waiting or surgery are the usual approach in the management of vitreomacular pathology (28). Depending on clinical presentation and severity of disease there are several treatment options. As resolution can occur spontaneously an observative and watchful waiting approach can be attempted in asymptomatic patients. However if VMT persists and symptoms are significant or bothersome treatment should be provided as foveal damage may occur (23). In fact for an appropriate patient management a strict differentiation between «symptomatic» VMT and «asymptomatic» VMT is necessary (see above).

1.4.1. Observation

Some of the patients, especially milder cases, will experience spontaneous resolution of their VMT. However literature reveals a varying occurrence of this phenomenon (29-31). Nonetheless a watchful-waiting approach is advisable for patients with VMA and many patients with VMT (17). Even when a surgical approach is considered an observation period of 2-3 months could be beneficial (26). Good prognostic factors for a successful spontaneous resolution rate seem to be younger age, focal VMT, absence of ERM and the presence of subretinal fluid (30).

1.4.2. Pharmacological vitreolysis

The gold standard in the choice of an interventional approach used to be and is still a pars-plana-vitrectomy (PPV) (28, 32). Yet, every surgical intervention brings about many perioperative risks and high costs (33, 34). Despite PPV's high success rate, the risks of surgery lead to the search for non-surgical treatment options for VMT. One such option was the development of pharmacological vitreolysis. In October 2012 the FDA approved Ocriplasmin (JetreaTM, ThromboGenics, Inc. Iselin, NJ) as a non-surgical, pharmacological agent for the treatment of VMT symptoms (35). In Croatia and Europe it is available since March 2013 (36). Again careful patient selection is indispensable and not all patients will benefit from a pharmacological treatment of their disease (37). The potential side-effects of Ocriplasmin include vitreous floaters, zonular instability and transient vision loss (38). Although primary study outcomes on the efficacy of pharmacological vitreolysis have shown statistically significant results compared to placebo, comparing these results to surgical interventions the view of high associated costs for the drug will yield disappointing and weaker clinical utility (39), especially in lower income countries. Studies comparing cost utility of enzymatic vitreolysis and pars-plana-vitrectomy show that ocriplasmin is still less cost-efficient compared to vitrectomy surgery in primary management of VMT (40). In fact there still is a need for searching cheaper and less invasive treatment options.

1.4.3. Pars-plana-vitrectomy (PPV)

Pars-plana-vitrectomy with peeling of all adhering areas and, if present, all epiretinal membranes (ERM) is an efficient and economical method for managing VMT (28, 40). Some authors claim that a simultaneous removal of the Internal Limiting Membrane (ILM) is linked to a reduction in the (re-) occurrence of ERMs (41). Indications of vitrectomy are symptomatic progressions of VMT, characterized by a decrease in visual acuity,

metamorphopsia or double vision (20, 28). Many authors report promising outcomes. An average improvement of visual acuity by two lines, reduction of central macular thickness and improvement of even resolution of metamorphopsia can be expected (23, 33, 42). Again patients with focal VMT had better postoperative improvement than patients with broad VMT (23).

1.4.4. Pneumovitrealysis

Previous studies have shown that intravitreal injections of gas bubbles (pneumatic vitrealysis) can lead to the closure of a macular opening by inducing PVD (43). Additional studies have shown that intravitreal gas bubbles alone can induce PVD in patients with non-proliferative diabetic retinopathy (44) and diabetic macular edema (45). Kim *et al.* have shown that intravitreal gas bubbles in combination with anti-vascular endothelial growth factor drug can induce the resolution of VMT in patients with wet macular degeneration in 4/4 (100%) eyes (46). Nonetheless, there is a lack of literature about the specific treatment of an isolated VMT only with intravitreal gas injection. Rodrigues *et al.* have shown that one intravitreal injection of the gas perfluoropropane (C₃F₈) can cause the resolution of VMT in 5/7 (70%) of eyes with isolated VMT and in 3/6 (50%) in eyes with diabetic macular edema (47). Pneumatic vitrealysis carries the potential of a safe, cheap and effective therapy, which could represent an asset in the management of patients with symptomatic vitreomacular traction.

2. OBJECTIVES

AIM:

The purpose of our study is to estimate the effectiveness and safety of a single sulfur hexafluoride (SF₆) intravitreal injection for patients with vitreomacular traction.

HYPOTHESIS:

The hypothesis is that the single sulfur hexafluoride intravitreal injection resolves vitreomacular traction in a significant number of patients with no side effects.

3. MATERIALS AND METHODS

3.1. ETHICAL APPROVAL & PROTOCOL REGISTRATION

The consent for conduction of this research was obtained from the Ethical Committee of the University Hospital of Split. In accordance with the Medical Code of Ethics, the data obtained in this research was and will be kept and handled strictly confidential. All reports generated on the basis of this study will utilize the data of a sample of patients with a diagnosis of vitreomacular traction fulfilling the eligibility criteria prior to intervention (section 3.2. Patient Population). The purpose of the examinations, procedures, possible advantages, disadvantages and possible side effects of the intervention were explained to all participants, possible questions were answered and a signed informed consent was obtained.

The study protocol was registered at clinicaltrials.gov (NCT03945695).

3.2. PATIENT POPULATION

Patients were selected from the pool of patients coming to the outpatient unit of the Department of Ophthalmology, University Hospital of Split, according to the criteria of inclusion and exclusion as stated below. After obtaining informed consent all patients were assigned into the intervention group and received treatment according to a predefined procedural protocol. Neither participants nor researchers were blinded during the whole course of the study.

3.2.1. Inclusion criteria

Participants needed to be 18 years or older and able to give written informed consent to the procedure. A diagnosis of symptomatic VMT based on clinical and OCT-findings, as described above, was necessary for inclusion.

3.2.2. Exclusion criteria

Patients presenting with any form of retinal tear, macular degeneration, vascular occlusion of the retina, aphakia, high myopia (> -8 diopters), uncontrolled glaucoma, vitreous opacities, retinal ablation, vitrectomy were not eligible for inclusion.

3.3. OUTCOME MEASURES

The primary outcome measure was VMT resolution as determined by OCT. Secondary outcomes were improvement of best-corrected visual acuity (BCVA), foveal outline focusing on vitreomacular adhesion presence and length, central foveal thickness (CFT) one week, 2 weeks and one month post intervention in comparison to preoperative findings. Furthermore, other secondary outcomes were maximum central foveal thickness at the one-month post interventional follow-up visit, time needed for the resolution of VMT, occurrence of any side-effects, such as retinal tears, retinal detachment and treatment failure rate.

3.4. SURGICAL PROCEDURE

Patients were selected according to the inclusion criteria mentioned above. After appropriate anesthesia with topical lidocain and antiseptic preparations of the surgical field with 5% povidone iodine, a paracentesis of the anterior chamber was performed in order to induce hypotony and to prevent hypertony after the injection of the gas bubble. Subsequently an intravitreal injection of 0.2 to 0.3 ml of undiluted filtered sulfur hexafluoride gas (SF₆) into the treated eye via pars plana at 3,5 mm from the limbus. Intraocular pressure of the examined eye was controlled before the intervention and kept at an appropriate level after paracentesis by manual application of pressure over the cornea with the rubber end of an insulin syringe plunger. All patients were required to avoid the supine position and had to lie on one side or the abdomen during sleep until complete resorption of the intraocular gas. During this period they were additionally asked to bend over several times during the day at least up to an angle of 90° or as much as possible, resembling the movement of a bird drinking water. (Hence the name «drinking-bird-technique».)

3.5. OPHTHALMOLOGIC EXAMINATION AND DATA COLLECTION

One of the investigators carried out regular control examinations at one week after the procedure, and thereafter at weeks 2 and 4. During each control examination best-corrected visual acuity, reported on a decimal scale, and intraocular pressure, in mmHg, were measured. Moreover biomicroscopy, indirect ophthalmoscopy, and macular OCT (Cirrus OCT 5000 HD, Zeiss, Jena, Germany) of the treated eye were performed. The following data were also

recorded by the same investigator: patient demographics (age, gender, affected eye, comorbidities), period of time between the intravitreal injection of gas to the separation of the posterior hyaloid membrane. Any adverse events that have occurred after gas injection, including eye complications (eg. retinal tear or ablation, infections, increase in intraocular pressure, uveitis, bleeding and damage to the optic nerve), and systemic complications, were also recorded.

3.6. STATISTICAL ANALYSIS

Descriptive statistics was used for patient demographic data and baseline characteristics. The small sample size made us report continuous variables as medians \pm interquartile range (IQR), minimum and maximum. Frequencies and proportions, as well as mean times to resolution were described for categorical variables.

Statistical analysis was performed using Statistical Package for Social Sciences (SPSS) Statistics, version 25.0 (IBM SPSS Statistics, Armonk, NY, USA).

4. RESULTS

A total number of eleven eyes from nine patients were included in our pilot study. Both gender and sides were equally distributed, with six out of eleven eyes being the right eye, and five out of eleven eyes being the left eye of the patient. In two patients both left and right eyes were affected by VMT and treated with a gap of three weeks between interventions. Interestingly treatment was for both eyes similarly effective in both of the patients, although one of them was affected by broad VMT in one eye and focal VMT in the second eye.

Out of the nine patients five were female and four were male accounting for five out of eleven male eyes and six out of eleven female eyes. Included patients were on average 72 years old, with the youngest being 56 years old and the oldest 84. Majority of patients were affected by a focal VMT, namely in eight out of eleven cases (72.7 %), broad VMT was present in the remaining three eyes (27.3 %). Patient characteristics are given in Table 2.

Table 2. Patient Characteristics: Gender; Eye affected by VMTS and treated by pneumovitrealysis.

	Frequency [in n/N (%)]	Resolution [in n/N (% from own group; % from total)]	Mean time to resolution [in weeks after intervention]
Total	11/11 (100)	2/11 (18.2)	1.5
Male	5/11 (45.5)	1/5 (20; 9)	2
Female	6/11 (54.5)	1/6 (16.7; 9.1)	1
Right eye	6/11 (54.5)	1/6 (16.7; 9.1)	1.5
Left eye	5/11 (45.5)	1/5 (20; 9)	1
Focal	8/11 (72.7)	1/8 (12.5; 9.1)	1
Broad	3/11 (27.3)	1/3 (33.3; 9)	2

Categorization of VMT (focal= $<1500\mu\text{m}$ or broad= $\geq 1500\mu\text{m}$)

In one out of the eleven included eyes resolution occurred on average after 1.5 weeks. In one eye with focal VMT no adhesion was visible on the first control visit, whereas resolution in the eye affected by broad VMT, resolution was only detectable on the second control visit. In a further eye, affected by focal adhesion, macular adhesion length decreased significantly from 267nm to 30nm at one-month post intervention. Unfortunately resolution wasn't achieved. Remaining eyes didn't show a significant decrease despite intravitreal gas injection. In fact after the one-month follow-up period a resolution was achieved in 2 out of 11 eyes (18.2%) (Figure 4 & Table 2). Nonetheless median adhesion length decreased from 620 μm before gas injection to a median adhesion length of 599 after injection in eyes without resolution (Table 6).

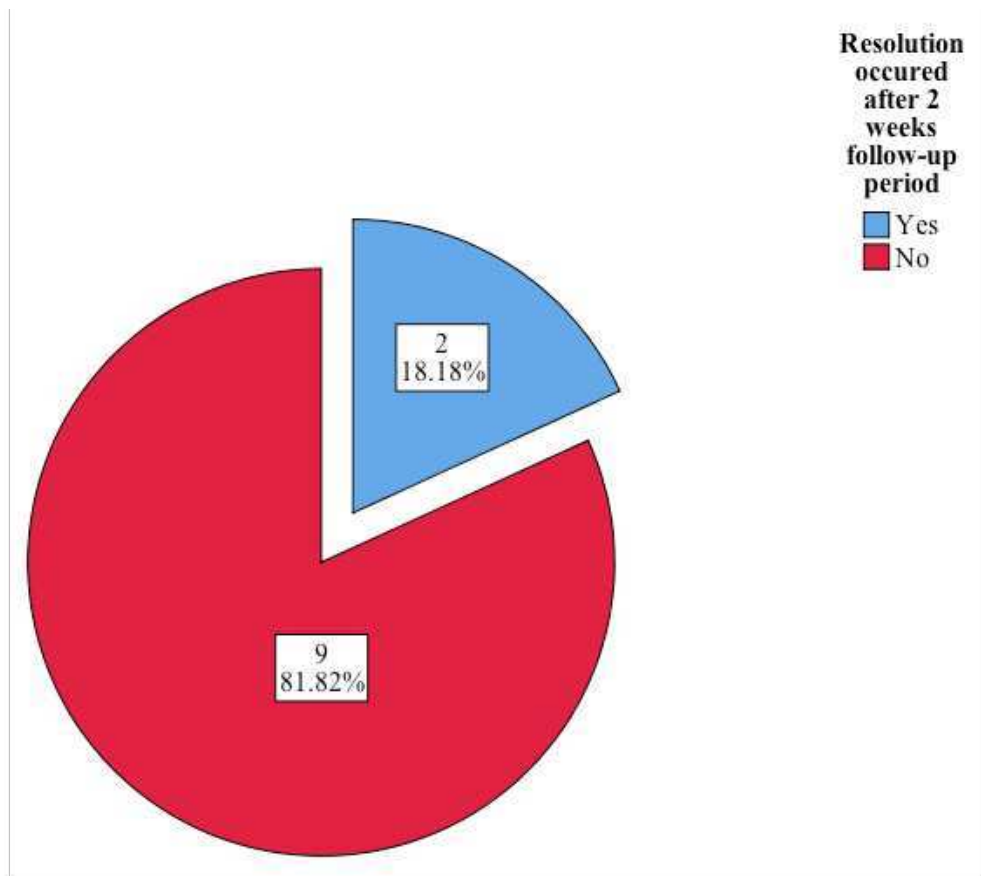


Figure 4. Resolution of VMT at the 3rd control visit (1 month after gas injection).

Improvement in visual acuity was detectable after resolution in the eye with focal VMT, but also in the eye with adhesion decrease. Unfortunately, there was no improvement in VA in the eye with broad VMT during our one-month follow-up period. The largest improvement was reported for one eye with an increase in VA by 0,4 (from previously 0,2 up to 0,6 at 1 month post intervention). Unfortunately median improvement from 0.4 before intervention to 0.5 after intervention in eyes with resolution was less impressive (Table 3 and Table 4). Since the patients didn't have any other symptoms characteristic for sVMT, the researchers cannot report any improvement or worsening. There was no increase in IOP due to the injection of intraocular gas. The investigators rather measured a slight decrease in IOP at the first control visit, which normalized until the end of the one-month follow-up period. The median IOP didn't differ significantly in both groups of eyes with and without resolution (Table 5).

None of the nine patients reported any side effects and they tolerated the injection quite well. Table 3 offers an overview of the preoperative patient characteristics. Mean age of included patients was 69 years. A high variation in preoperative best-corrected visual acuity

could be noted. Based on adhesion length one can see that both focal and broad VMTs were present in our sample (Table 3).

Central foveal thickness was slightly lower in eyes achieving resolution than in eyes without resolution. This difference however was evident even before application of intravitreal gas. Interestingly though a slightly faster decrease in CFT could be noted in eyes achieving resolution (Table 7).

Table 3. Descriptive Statistics for continuous variables – pre-interventional

	N	Median	Interquartile Range	Minimum	Maximum
Age at time of operation	11	69	66-82	56	84
Preoperative Visual acuity	11	0.4	0.2-0.7	0.08	0.7
Preoperative Intraocular Pressure (IOP)	11	16	14-18	13	20
Preoperative Adhesion length as seen on OCT	11	620	326-1620	87	2271
Preoperative CFT as seen on OCT	8	280.5	270.25-298.25	263	337

Table 4. Visual acuity – post-interventional

Resolution occurred during follow-up	Statistical Measure	Visual Acuity on 1st control examination (1 week postop)	Visual Acuity on 2nd control examination (2 weeks postop)	Visual Acuity on 3rd control examination (1 month postop)
Yes (N=2)	Median	0.4	0.4	0.5
	Interquartile Range	0.4-0.4	0.4-0.4	0.4-0.6
	Minimum	0.4	0.4	0.4
	Maximum	0.4	0.4	0.6
No (N=9)	Median	0.3	0.5	0.5
	Interquartile Range	0.2-0.5	0.3-0.6	0.3-0.6
	Minimum	0.04	0.02	0.02
	Maximum	0.7	1.00	0.7

Table 5. Intraocular pressure – post-interventional

Resolution occurred during follow-up	Statistical Measure	IOP on 1st control examination (1 week postop)	IOP on 2nd control examination (2 weeks postop)	IOP on 3rd control examination (1 month postop)
Yes (N=2)	Median	15.0	15.0	15.0
	Interquartile Range	13-17	15-15	15-15
	Minimum	13	15	15
	Maximum	17	15	15
No (N=9)	Median	13.0	13.0	13.0
	Interquartile Range	12-18	12-18	12-18
	Minimum	12	11	12
	Maximum	18	19	21

Table 6. Adhesion length – post-interventional

Resolution occurred during follow-up	Statistical Measure	Adhesion length on 1st control examination (1 week postop) as seen on OCT	Adhesion length on 2nd control examination (2 weeks postop) as seen on OCT	Adhesion length on 3rd control examination (1 month postop) as seen on OCT
Yes (N=2)	Median	865.0	0.0	0.0
	Interquartile Range	0-1730	0-0	0-0
	Minimum	0	0	0
	Maximum	1730	0	0
No (N=9)	Median	601.0	602.0	599.0
	Interquartile Range	385-1080	356-1100	356-1101
	Minimum	45	45	30
	Maximum	2314	2240	2239

Table 7. Central Foveal Thickness (CFT) – post-interventional

Resolution occurred during follow-up	Statistical Measure	CFT on 1st control examination (1 week postop) as seen on OCT	CFT on 2nd control examination (2 weeks postop) as seen on OCT	CFT on 3rd control examination (1 month postop) as seen on OCT
Yes (N=2)	Median	266.0	264.0	260.0
	Interquartile Range	258-274	263-265	253-267
	Minimum	258	263	253
	Maximum	274	265	267
No (N=7)	Median	333.0	332.0	330.0
	Interquartile Range	308.5-389	276.5-426.5	288-388.5
	Minimum	260	248	262
	Maximum	446	648	621

5. DISCUSSION

Our pilot study assessed the efficacy of an intravitreal injection of sulfhexafluoride (SF6) gas for the management of patients with symptomatic vitreomacular traction. Treatment was successful in about a fifth of included eyes after a one-month follow-up period. The success rate of exactly 18.2% was slightly lower than expected.

Earlier reports described higher resolution rates with a similar methodology. Chan *et al.* first described the procedure in 1995 including 18 patients in his study (48). No information on adhesion length was provided. Chan *et al.* used a different expansile gas, namely perfluoropropane (C3F8) and achieved VMT release in 96% of cases. In a later study Jorge *et al.* achieved an impressive 100% VMT-release in 6 patients with stage II macular holes (49). Again adhesion length wasn't reported. Rodrigues *et al.* reported a resolution of 40% in 15 eyes affected by focal VMT at a one-month post intravitreal gas injection with expansile perfluoropropane (C3F8) (47).

In 2017 Steinle *et al.* and Chan *et al.* independently conducted larger retrospective studies looking at 30 eyes affected by focal VMT and 50 eyes, respectively, with a 73% and 86% VMT-release after one month follow-up (50, 51).

In view of these previous reports, our results are in favor of the observation that the utilization of a long-acting gas generally yields better resolution rates than a short-acting one.(52) This observation was very well elaborated by Čokl and Petrovič, who compared 29 eyes receiving C3F8 with 28 eyes receiving an injection of SF6. Resolution rate in the C3F8 group was 62%, whereas as resolution rate of 21.4% was achieved in the SF6 group (53).

A reason for these results favoring C3F8 could be the prolonged resorption time of C3F8 compared to SF6, giving it more time to act and have an effect (54). The ability to expand and even quadruple prolongs time of action even more (51). In fact, what matters more is resorption time rather than bubble size (55).

Still the possibility of good results after SF6 injection cannot be completely ruled out. Ochoa-Contreras *et al.* injected 0.5 mL of SF6 in 12 eyes of patients with nonproliferative diabetic retinopathy and achieved an impressive resolution rate of 100% (44).

Later also Buzzacco *et al.* reported very successful results for sulfurhexafluoride injections. In a case series in 2017 they achieved a resolution in 87% of their included patients. Unfortunately with only six patients their sample size was even smaller than in our study, also no clear inclusion and exclusion criteria were applied, which made the patient population quite heterogeneous (56).

Day *et al.* conducted another successful study quite similar to ours. They included eight eyes affected by focal and one eye affected by broad VMT. A resolution in 55.6% of cases was achieved (57).

And finally a bigger study was conducted by Javed *et al.* in 2018, which was most comparable to our own. They included a total of 21 patients and reached a significant resolution of 42.9% after a one-month follow-up period. Unfortunately there was no mention of adhesion length in the sample population (55). These remarkable results show that pneumatic vitreolysis using sulfurhexafluoride can be similarly effective in selected patients with focal VMT. Our results coincide with these observations.

Furthermore a shorter resorption time of SF₆ means that patients can return earlier to normal activities and travel, a point to consider in people working in environments with changing air pressures. Also the additional strain on a non-detaching VMT is reduced, minimizing the risk of unwanted side effects, such as retinal tears.

In view of the low cost, convenience and easy availability of applying intravitreal gas in patients with symptomatic VMT, the investigators believe that it has the potential of becoming a good initial management in part of the affected patient population. Especially in countries with a lower health care budget and with less available surgical expertise, pneumovitreolysis serves as a worthwhile initial alternative to the much more costly ocriplasmin treatment and the more invasive and more demanding PPV.

For the same reasons an implementation in standard procedure of care, possibly second-line after watchful-waiting, could be worthwhile even in higher income regions. Not only for economical and organizational reasons, but also to spare patients, in whom it is successful, possible side-effects of enzymatic vitreolysis and the discomfort of a substantial ophthalmic surgery.

Due to the fact that this study served as an evaluation of feasibility of the proposed treatment and in order to get investigators familiarized with the treatment implementation a small sample size was used. The investigators therefore cannot make large-scale inferences about treatment effect. Furthermore, patients were followed rather shortly and it is possible that there are changes, perhaps even additional resolutions, after a longer post-interventional period. Another drawback was the fact that patients were performing their exercises scheduled at home and not in a more controlled environment. In fact, although the researchers made sure that patients understood how to perform the “drinking-bird”-movement and they were asked and reminded at every follow-up visit, actual compliance cannot be assured.

A benefit of conducting studies in Dalmatia is that one can easily obtain a very homogenous treatment naïve sample population. This geographical and cultural peculiarity is an advantage and strength of this study.

Another consideration originated in the observation that majority of resolutions were noted at the first post-interventional check-up. This very short time to resolution raised the question if mere mechanical manipulation alone was enough to cause the detachment of the adherent vitreous. In future trials it would be interesting to have a treatment-arm with only sham injections, to test if the effect of manipulation alone is enough to induce resolution and how much of a benefit the intravitreal gas injection brings to the procedure success rate. Such a study could furthermore compare the added effectiveness of different gases.

As already noted above future studies should implement bigger sample sizes of at least 44 patients in order to yield sufficiently powered results.

6. CONCLUSIONS

Pneumovitreolysis with SF6 seems to be a safe, economical and effective minimally invasive first-line approach in the management of symptomatic vitreomacular traction. A consideration of including it into standard management guidelines, especially for cases of focal sVMT is worthwhile. Of course, further large-scale studies are necessary to confirm these preliminary findings. Furthermore, appropriate reporting guidelines for studies evaluating treatment of VMT should be designed in the interest of better comparability.

7. REFERENCES

1. Fincham GS, James S, Spickett C, Hollingshead M, Thrasivoulou C, Poulson AV, et al. Posterior vitreous detachment and the posterior hyaloid membrane. *Ophthalmology*. 2018;125:227-36.
2. Wang J, McLeod D, Henson DB, Bishop PN. Age-dependent changes in the basal retinovitreous adhesion. *Invest Ophthalmol Vis Sci*. 2003;44:1793-800.
3. Henrich PB, Monnier CA, Halfter W, Haritoglou C, Strauss RW, Lim RY, et al. Nanoscale topographic and biomechanical studies of the human internal limiting membrane. *Invest Ophthalmol Vis Sci*. 2012;53:2561-70.
4. Menzler J, Neubauer AS, Haritoglou C, Jackson TL. Incidence and prevalence of vitreomacular traction with and without macular hole in germany. *Clin Ophthalmol*. 2019;13:177-88.
5. Rodman JA, Shechtman D, Sutton BM, Pizzimenti JJ, Bittner AK. Prevalence of vitreomacular adhesion in patients without maculopathy older than 40 years. *Retina*. 2018;38:2056-63.
6. Shao L, Xu L, You QS, Wang YX, Chen CX, Yang H, et al. Prevalence and associations of incomplete posterior vitreous detachment in adult chinese: The beijing eye study. *PLoS One*. 2013;8:e58498.
7. Lumi X, Hawlina M, Glavac D, Facsko A, Moe MC, Kaarniranta K, et al. Ageing of the vitreous: From acute onset floaters and flashes to retinal detachment. *Ageing Res Rev*. 2015;21:71-7.
8. Tsukahara M, Mori K, Gehlbach PL, Mori K. Posterior vitreous detachment as observed by wide-angle oct imaging. *Ophthalmology*. 2018;125:1372-83.
9. Johnson MW. Posterior vitreous detachment: Evolution and complications of its early stages. *Am J Ophthalmol*. 2010;149:371-82.
10. Cline D, Hofstetter HW, Griffin JR. Dictionary of visual science. 4th ed. Boston: Butterworth-Heinemann; 1997.
11. Chang LK, Fine HF, Spaide RF, Koizumi H, Grossniklaus HE. Ultrastructural correlation of spectral-domain optical coherence tomographic findings in vitreomacular traction syndrome. *Am J Ophthalmol*. 2008;146:121-7.
12. Steel DH, Downey L, Greiner K, Heimann H, Jackson TL, Koshy Z, et al. The design and validation of an optical coherence tomography-based classification system for focal vitreomacular traction. *Eye (Lond)*. 2016;30:314-24.
13. Reese AB, Jones IS, Cooper WC. Vitreomacular traction syndrome confirmed histologically. *Am J Ophthalmol*. 1970;69:975-7.

14. Reese AB, Jones IS, Cooper WC. Macular changes secondary to vitreous traction. *Am J Ophthalmol*. 1967;64:Suppl:544-9.
15. Duker JS, Kaiser PK, Binder S, de Smet MD, Gaudric A, Reichel E, et al. The international vitreomacular traction study group classification of vitreomacular adhesion, traction, and macular hole. *Ophthalmology*. 2013;120:2611-9.
16. Stalmans P, Duker JS, Kaiser PK, Heier JS, Dugel PU, Gandorfer A, et al. Oct-based interpretation of the vitreomacular interface and indications for pharmacologic vitreolysis. *Retina*. 2013;33:2003-11.
17. Bowling B. Kanski's clinical ophthalmology: A systematic approach. 8th ed. London: Elsevier; 2015.
18. Irvine SR. A newly defined vitreous syndrome following cataract surgery. *Am J Ophthalmol*. 1953;36:599-619.
19. Jaffe NS. Vitreous traction at the posterior pole of the fundus due to alterations in the vitreous posterior. *Trans Am Acad Ophthalmol Otolaryngol*. 1967;71:642-52.
20. Garcia-Layana A, Garcia-Arumi J, Ruiz-Moreno JM, Arias-Barquet L, Cabrera-Lopez F, Figueroa MS. A review of current management of vitreomacular traction and macular hole. *J Ophthalmol*. 2015;2015:809640.
21. Tammewar AM, Bartsch DU, Kozak I, Rosen R, Falkenstein IA, Garcia P, et al. Imaging vitreomacular interface abnormalities in the coronal plane by simultaneous combined scanning laser and optical coherence tomography. *Br J Ophthalmol*. 2009;93:366-72.
22. Sebag JW, MY. Combined spectral-domain optical coherence tomography/scanning laser ophthalmoscopy imaging of vitreous and the vitreo-retinal interface, medical retina, focus on retinal imaging. In: Holz FS, RF, editor. *Essentials in ophthalmology*. Berlin, Heidelberg: Springer Verlag; 2010. p. 157-68.
23. Sonmez K, Capone A, Jr., Trese MT, Williams GA. Vitreomacular traction syndrome: Impact of anatomical configuration on anatomical and visual outcomes. *Retina*. 2008;28:1207-14.
24. Forte R, Pascotto F, de Crecchio G. Visualization of vitreomacular tractions with en face optical coherence tomography. *Eye (Lond)*. 2007;21:1391-4.
25. Bottos JM, Elizalde J, Rodrigues EB, Maia M. Current concepts in vitreomacular traction syndrome. *Curr Opin Ophthalmol*. 2012;23:195-201.
26. Shao L, Wei W. Vitreomacular traction syndrome. *Chin Med J (Engl)*. 2014;127:1566-71.

27. Bottos J, Elizalde J, Arevalo JF, Rodrigues EB, Maia M. Vitreomacular traction syndrome. *J Ophthalmic Vis Res.* 2012;7:148-61.
28. Folk JC, Adelman RA, Flaxel CJ, Hyman L, Pulido JS, Olsen TW. Idiopathic epiretinal membrane and vitreomacular traction preferred practice pattern((r)) guidelines. *Ophthalmology.* 2016;123:152-81.
29. Zhang Z, Dong F, Zhao C, Dai R, Yu W, Zheng L, et al. Natural course of vitreomacular traction syndrome observed by spectral-domain optical coherence tomography. *Can J Ophthalmol.* 2015;50:172-9.
30. Ziemssen F, Bartz-Schmidt KU, Dimopoulos S. Knowledge of vitreomacular traction (vmt) scenarios: Is doing nothing still a beneficial alternative and, if so, when? *Graefes Arch Clin Exp Ophthalmol.* 2016;254:615-6.
31. Dimopoulos S, Bartz-Schmidt KU, Gelissen F, Januschowski K, Ziemssen F. Rate and timing of spontaneous resolution in a vitreomacular traction group: Should the role of watchful waiting be re-evaluated as an alternative to ocriplasmin therapy? *Br J Ophthalmol.* 2015;99:350-3.
32. Steel DH, Lotery AJ. Idiopathic vitreomacular traction and macular hole: A comprehensive review of pathophysiology, diagnosis, and treatment. *Eye (Lond).* 2013;27.
33. Jackson TL, Nicod E, Angelis A, Grimaldi F, Prevost AT, Simpson AR, et al. Pars plana vitrectomy for vitreomacular traction syndrome: A systematic review and metaanalysis of safety and efficacy. *Retina.* 2013;33:2012-7.
34. Nicod E, Jackson TL, Grimaldi F, Angelis A, Costen M, Haynes R, et al. Direct cost of pars plana vitrectomy for the treatment of macular hole, epiretinal membrane and vitreomacular traction: A bottom-up approach. *Eur J Health Econ.* 2016;17:991-9.
35. Neffendorf JE, Kirthi V, Pringle E, Jackson TL. Ocriplasmin for symptomatic vitreomacular adhesion. *Cochrane Database Syst Rev.* 2017;10:Cd011874.
36. ema.europa.eu [Internet]. London: European Medicines Agency: 08/01/2019 Jetrea - EMEA/H/C/002381 - N/0044 - Jetrea: European Public Assessment Report - Product Information. [updated 2019 March 4; cited 2002 Jul 9]. Available from: <https://www.ema.europa.eu/en/medicines/human/EPAR/jetrea/>.
37. Muqit MMK, Hamilton R, Ho J, Tucker S, Buck H. Intravitreal ocriplasmin for the treatment of vitreomacular traction and macular hole- a study of efficacy and safety based on nice guidance. *PLoS One.* 2018;13:e0197072.
38. Shaikh M, Miller JB, Papakostas TD, Husain D. The efficacy and safety profile of ocriplasmin in vitreomacular interface disorders. *Semin Ophthalmol.* 2017;32:52-5.

39. Garcia-Perez L, Abreu-Gonzalez R, Perez-Ramos J, Garcia-Perez S, Serrano-Aguilar P. Review of economic studies and budget impact analysis of ocriplasmin as a treatment of vitreomacular traction. *Arch Soc Esp Oftalmol*. 2016;91:257-64.
40. Chang JS, Smiddy WE. Cost evaluation of surgical and pharmaceutical options in treatment for vitreomacular adhesions and macular holes. *Ophthalmology*. 2014;121:1720-6.
41. Azuma K, Ueta T, Eguchi S, Aihara M. Effects of internal limiting membrane peeling combined with removal of idiopathic epiretinal membrane: A systematic review of literature and meta-analysis. *Retina*. 2017;37:1813-9.
42. Witkin AJ, Patron ME, Castro LC, Reichel E, Rogers AH, Bauman CR, et al. Anatomic and visual outcomes of vitrectomy for vitreomacular traction syndrome. *Ophthalmic Surg Lasers Imaging*. 2010;41:425-31.
43. Neffendorf JE, Simpson ARH, Steel DHW, Desai R, McHugh DA, Pringle E, et al. Intravitreal gas for symptomatic vitreomacular adhesion: A synthesis of the literature. *Acta Ophthalmol*. 2018;96:685-91.
44. Ochoa-Contreras D, Delsol-Coronado L, Buitrago ME, Velasco-Barona C, Quiroz-Mercado H. Induced posterior vitreous detachment by intravitreal sulfur hexafluoride (sf6) injection in patients with nonproliferative diabetic retinopathy. *Acta Ophthalmol Scand*. 2000;78:687-8.
45. McHugh D, Gupta B, Saeed M. Intravitreal gas injection for the treatment of diabetic macular edema. *Clin Ophthalmol*. 2011;5:1543-8.
46. Kim YM, Lee SJ, Koh HJ. Gas-assisted release of vitreomacular adhesion in wet age-related macular degeneration. *Retina*. 2011;31:2123-4.
47. Rodrigues IA, Stangos AN, McHugh DA, Jackson TL. Intravitreal injection of expansile perfluoropropane (c(3)f(8)) for the treatment of vitreomacular traction. *Am J Ophthalmol*. 2013;155:270-6.
48. Chan CK, Wessels IF, Friedrichsen EJ. Treatment of idiopathic macular holes by induced posterior vitreous detachment. *Ophthalmology*. 1995;102:757-67.
49. Jorge R, Costa RA, Cardillo JA, Uno F, Bonomo PP, Farah ME. Optical coherence tomography evaluation of idiopathic macular hole treatment by gas-assisted posterior vitreous detachment. *Am J Ophthalmol*. 2006;142:869-71.
50. Steinle NC, Dhoot DS, Quezada Ruiz C, Castellarin AA, Pieramici DJ, See RF, et al. Treatment of vitreomacular traction with intravitreal perfluoropropane (c3f8) injection. *Retina*. 2017;37:643-50.

51. Chan CK, Crosson JN, Mein CE, Daher N. Pneumatic vitreolysis for relief of vitreomacular traction. *Retina*. 2017;37:1820-31.
52. Chan CK, Mein CE, Crosson JN. Pneumatic vitreolysis for management of symptomatic focal vitreomacular traction. *J Ophthalmic Vis Res*. 2017;12:419-23.
53. Cokl N, Globocnik Petrovic M. Intravitreal injection of perfluoropropane is more efficacious than sulfur hexafluoride in releasing vitreomacular traction. *Acta Clin Croat*. 2018;57:327-34.
54. Chan CK, Lin SG, Nuthi AS, Salib DM. Pneumatic retinopexy for the repair of retinal detachments: A comprehensive review (1986-2007). *Surv Ophthalmol*. 2008;53:443-78.
55. Javed RMM, Khan AA, Tayyab H, Chaudhry N. Sf6 assisted pneumatic vitreolysis in cases of vitreomacular traction syndrome. *PJO*. 2018;34:139-44.
56. Buzzacco DM, Patel SS. Treatment of symptomatic vitreomacular adhesion with expansile sulfur hexafluoride (sf6) gas. *Open Ophthalmol J*. 2017;11:80-3.
57. Day S, Martinez JA, Nixon PA, Levitan M, Dooner JW, Wong RW, et al. Intravitreal sulfur hexafluoride injection for the treatment of vitreomacular traction syndrome. *Retina*. 2016;36:733-7.

8. SUMMARY

Objectives: The aim of this study was to prove that pneumatic vitreolysis using the drinking bird technique is a safe and effective method for treatment of vitreomacular tractions.

Materials and methods: Eleven patients who came to Department of Ophthalmology, University Hospital of Split, with OCT confirmed vitreomacular traction. Patients were treated with pneumatic vitreolysis using sulfur hexafluoride gas, after that they would do the “drinking bird” technique for the next two weeks. Patients were followed-up for 1 month.

Results: Eleven eyes of nine patients affected by symptomatic vitreomacular traction (VMT) were included in this pilot study. Three out of eleven patients had broad ($\geq 1500\mu\text{m}$) VMT (N=3/11); Eight out of eleven patients had focal ($\leq 1500\mu\text{m}$) VMT (N=8/11). One week after the procedure, resolution of VMT had occurred in one out of eleven patients (N=1/11). Two weeks after treatment resolution had occurred in two out of eleven patients (N=2/11). Resolution had occurred in 12.5 percent of patients (N=1/8) with focal and thirty-three percent of patients with broad VMT (N=1/3). Eyes with focal VMT had a shorter time to resolution (mean time to resolution 1 week) than the eye with broad VMT (mean time to resolution 2 weeks). The improvement of the best-corrected visual acuity occurred in two out of three patients with traction resolution. Visual acuity improved in all eyes with achieved resolution from a mean pre-interventional VA of 0,4 on decimal scale to 0,5 post-intervention. In none of the patients did intraocular pressure go beyond normal limits. In eyes without resolution macular adhesion length didn't significantly decrease despite intravitreal gas injection. No complications following the procedure were recorded.

Conclusions: Pneumatic vitreolysis using the “drinking bird” technique is a safe and effective alternative for the treatment of vitreomacular traction.

9. CROATIAN SUMMARY

Naslov: Pneumatska vitreoliza uz pomoć “drinking bird” tehnike u liječenju vitreomakularnih trakcija

Ciljevi: Cilj ovog istraživanja je ispitati sigurnost i učinkovitost pneumatske vitreolize uz pomoć “drinking bird” tehnike u liječenju vitreomakularnih trakcija.

Bolesnici i metode: Jedanaest bolesnika koji su došli u Kliniku za očne bolesti, KBC Split, s potvrđenom dijagnozom vitreomakularne trakcije. Bolesnici su bili podvrgnuti pneumatskoj vitreolizi s plinom sumporovim heksafloridom te su nakon zahvata iduća dva tjedna izvodili povremene nakolone gornjeg dijela tijela prema naprijed. Bolesnici su bili praćeni kroz mjesec dana.

Rezultati: Tri bolesnika su imali široku vitreomakularnu trakciju, a osam bolesnika su imali usku vitreomakularnu trakciju. Na prvoj kontroli, tjedan dana nakon zahvata, rezolucija vitreomakularne trakcije nastupila je u jednom od ukupno jedanaest bolesniku (N=1/11). Nakon dva tjedna dva bolesnika imali su rezoluciju vitreomakularne trakcije. Rezolucija je nastupila u trinaest posto bolesnika s uskom i trideset tri posto sa širokom vitreomakularnom trakcijom. Do poboljšanja najbolje korigirane vidne oštine došlo je u pedeset posto bolesnika u kojih je nastupila rezolucija trakcije. Niti jedan bolesnik nije imao postoperativno poviđenje intraokularnog tlaka. Nikakve komplikacije nakon zahvata nisu bile zabilježene.

Zaključci: Pneumatska vitreoliza uz pomoć “drinking bird” tehnike je sigurna i valjana alternativa za liječenje vitreomakularnih trakcija.

10. CURRICULUM VITAE

PERSONAL INFORMATION

Address: Ringental 13, 89537 Giengen, Germany

Birth date: October, 11 1992; Birth place: Heidenheim an der Brenz, Germany

Email: martinkowalski1@gmx.de

EDUCATION

2013 – Present MD, Medical Studies in English, University of Split School of Medicine, Croatia

2003 – 2012 General University Entrance Qualification, Margarete-Steiff-Gymnasium, Giengen an der Brenz, Germany

2009 – 2010 Rotary International Youth Exchange Program, Taipei, Taiwan

TRAINING

2019 Clinical Internship, Centre for Ophthalmology of the University Hospital Tübingen, Tübingen, Germany

2019 Research internship, Lee Kong Chian School of Medicine (LKC Medicine), Centre for Population Health Sciences (CePHaS), Singapore

2017 Student exchange, Shimane University, Department of Psychiatry, Izumo, Japan

2016 Clinical Internship, Primary health care centre «Dom Zdravlja Tomislavgrad», Tomislavgrad, Bosnia and Herzegovina

2015 Clinical Internship, Pediatric Department of the Clinical centre Heidenheim, Heidenheim, Germany

PUBLICATIONS IN PEER-REVIEWED JOURNALS

Riado Minguez D, **Kowalski M**, Vallve Odena M, Longin Pontzen D, Jelcic Kadic A, Jeric M, *et al.* Methodological and reporting quality of systematic reviews published in the highest ranking journals in the field of pain. *Anesthesia & Analgesia*. 2017. doi: 10.1213/ANE.0000000000002227.

Kozina, S., **Kowalski, M.**, Vlastelica, M., Mastelić, T., & Borovac, J. A. Traumatic Memory of One's Son Gone Missing in War: Content Analysis Using Krippendorff's Alpha. *SAGE Open*. 2019. doi: <https://doi.org/10.1177/2158244019839627>.

SCHOLARSHIPS: Scholarship holder of the German Academic Scholarship Foundation