

# Gene expression pattern of Greb1l in the fetal and postnatal kidneys of Dab1<sup>-/-</sup> mice

---

**Balić, Andrea**

**Master's thesis / Diplomski rad**

**2021**

*Degree Grantor / Ustanova koja je dodijelila akademski / stručni stupanj:* **University of Split, School of Medicine / Sveučilište u Splitu, Medicinski fakultet**

*Permanent link / Trajna poveznica:* <https://um.nsk.hr/um:nbn:hr:171:810832>

*Rights / Prava:* [In copyright](#)/[Zaštićeno autorskim pravom.](#)

*Download date / Datum preuzimanja:* **2024-09-26**



*Repository / Repozitorij:*

[MEFST Repository](#)



**UNIVERSITY OF SPLIT  
SCHOOL OF MEDICINE**

**ANDREA BALIĆ**

**GENE EXPRESSION PATTERN OF GREB1L IN THE FETAL  
AND POSTNATAL KIDNEYS OF DAB1<sup>-/-</sup> MICE**

**DIPLOMA THESIS**

**Academic year:**

**2020/2021**

**Mentor:**

**Prof. Katarina Vukojević, MD, PhD, MSc**

**Split, July 2021**

## TABLE OF CONTENTS

<b>1. INTRODUCTION</b> .....	1
1.1. Embryonal development of the kidney .....	2
1.1.1. Kidney systems .....	2
1.1.2. Collecting system.....	2
1.1.3. Excretory system.....	3
1.2. Histology and Anatomy .....	3
1.2.1. Renal Corpuscles and Blood Filtration .....	4
1.2.2. Proximal Convoluted Tubule .....	5
1.2.3. Loop of Henle .....	6
1.2.4. Distal Convoluted Tubule and Juxtaglomerular Apparatus .....	7
1.2.5. Juxtaglomerular apparatus .....	7
1.2.6. Collecting Ducts.....	8
1.3. Congenital anomalies of the kidney and urinary tract .....	8
1.4. GREB1L .....	9
1.4.1. Retinoic acid signaling pathway .....	10
1.4.2. The role of retinoic acid signaling in the kidney.....	10
1.4.3. GREB1L and kidney.....	11
1.5. Disabled-1 protein, <i>yotari</i> mice and <i>reeler</i> mice .....	13
1.5.1. DAB1 in the kidney .....	14
<b>2. OBJECTIVES</b> .....	15
<b>3. MATERIALS AND METHODS</b> .....	17
<b>3.1. Ethics</b> .....	18
<b>3.2. Experimental animals</b> .....	18
<b>3.3. Tissue collection and immunohistochemistry</b> .....	18
<b>3.4. Statistics</b> .....	19
<b>4. RESULTS</b> .....	20
<b>5. DISCUSSION</b> .....	26
<b>6. CONCLUSION</b> .....	30
<b>7. REFERENCES</b> .....	32
<b>8. SUMMARY</b> .....	36
<b>9. CROATIAN SUMMARY</b> .....	38
<b>10. CURRICULUM VITAE</b> .....	40

## ACKNOWLEDGEMENT

*I would first like to thank my mentor Professor Katarina Vukojević, MD, PhD, who helped me with my thesis and has given me the opportunity for research.*

*I would also like to thank Mirela Lozić for spending many hours with me, helping me with my laboratory and microscopy work required for this thesis, and for always being available when needed.*

*I would like to give special thanks to my dearest friend and colleague, Nikolina Đurđević, for her patient support and unforgettable moments over our study years.*

*But most of all, I would like to thank my father, Dražen Balić; mother, Maja Balić; grandfather, Andrija Balić; grandmother, Nediljka Balić; and my boyfriend, Marin Bolonić for their support and understanding over my study years and for making all this come true.*

## **LIST OF ABBREVIATIONS**

PCT- proximal convoluted tubule

DCT- distal convoluted tubule

ACE- angiotensin converting enzyme

ADH- antidiuretic hormone

CAKUT- congenital anomalies of the kidney and urinary tract

UTI- urinary tract disorder

URA- unilateral kidney agenesis

BRA- bilateral kidney agenesis

PKD- polycystic kidney disease

VUR- vesicourethral reflux

GREB1L- growth regulation by estrogen in breast cancer like-1

GREB1- growth regulation by estrogen in breast cancer 1

RA- retinoic acid

RAR- retinoic acid receptor

RXR- retinoic x receptor

GFP-fused- Green fluorescent protein-fused

MRKH- Mayer-Rokitansky-Kuster-Hauser

DAB1- Disabled-1 adaptor protein

PGK-neocassette- Phosphoglycerate kinase neocassette

PI-PTB- Phosphotyrosine binding domain

PBS- Phosphate buffer saline

PFA- Paraformaldehyde

DAPI- 4',6-diamidino-2-phenylindole

## **1. INTRODUCTION**

## 1.1. Embryonal development of the kidney

### 1.1.1. Kidney systems

During embryonal development of the kidney, we have three different systems that are formed: pronephros, mesonephros, and metanephros from cranial-to-caudal order. Pronephros is involving and is nonfunctional, mesonephros is active only during the early fetal period, and metanephros is the one responsible for the formation of the permanent kidney. Pronephros consists of 7 to 10 solid cell groups (nephrotomes) in the cervical region at the beginning of the fourth week. By the end of the fourth week pronephros disappears. In mesonephros the first excretory tubules appear, in the fourth week of development during pronephric system regression. The excretory tubules lengthen rapidly, forming an S-shaped loop, and glomerulus will be formed at their medial extremity from acquired tuft of capillaries. Bowman's capsule is formed from the tubules around the glomerulus, together making a renal corpuscle. Along the lateral side of mesonephros, tubule enters the longitudinal collecting duct known as the mesonephric or Wolffian duct. While cranial tubules and glomeruli mostly disappear by the end of the second month, caudal tubules are still differentiating. Metanephros, the last kidney system which is also known as the permanent kidney, appears in the fifth week. Its excretory units are formed from the metanephric mesoderm in the same manner as in the mesonephric system (1).

### 1.1.2. Collecting system

An outgrowth of the mesonephric duct known as ureteric bud, which is responsible for the development of the collecting ducts of the permanent kidney. Afterwards, the bud dilates, forming the primitive renal pelvis, which will later form the future major calyces by splitting into cranial and caudal portions. Two new buds are formed by each calyx, subdividing until twelve or more generations of tubules have formed. Minor calyces of the renal pelvis are formed when the tubules of the second order enlarge and then absorb those of the third and fourth generations. Later during further development, collecting tubules of the fifth and subsequent generations elongate and converge on the minor calyx, forming the renal pyramid. The ureteric bud gives rise to the renal pelvis, the ureter, 1 to 3 million collecting tubules and the major and minor calyces (1).

### 1.1.3. Excretory system

Metanephric tissue cap is covering each newly formed collecting tubule at its distal end. Cells of the tissue cap form small vesicles, so called renal vesicles, under the inductive influence of the tubule. The renal vesicles give rise to small S-shaped tubules. At one end of the S capillaries grow into the pocket and differentiate into glomeruli. Tubules and glomeruli together form nephros. Each proximal end of nephron forms Bowman's capsule, which is deeply indented by a glomerulus, while distal end connects with one of the collecting tubules, establishing a pathway from Bowman's capsule to the collecting unit. Lengthening of the excretory tubule is responsible for the formation of the proximal convoluted tubule (PCT), distal convoluted tubule (DCT) and loop of Henle. Nephrons continue to form until birth, and at that time there are approximately 1 million present in each kidney (1).

## 1.2. Histology and Anatomy

Each kidney consists of convex lateral surface and concave medial border, the hilum, where nerves enter, the ureter exits, and lymph vessels and blood enter and exit. They are both covered by a thin fibrous capsule. The upper end of the ureter expands within the hilum as the renal pelvis, which then divides into two to three major calyces, from which smaller branches, the minor calyces arise. The renal pelvis and calyces are surrounded by the area containing adipose tissue (2).

The kidney consists of an outer cortex and an inner medulla. Cortex is a darker region that has many corpuscles and cross sections of tubules, while medulla consists of renal pyramids, formed by 8-12 conical structures, separated by renal columns, which are extensions from the cortex. Each renal pyramid and cortical tissue at its base and along its sides together form a renal lobe. Medullary rays, striated extensions from the medulla into the cortex, together with attached cortical tissue are considered lobules. The tip of each pyramid, renal papilla, projects into a minor calyx, which collects urine formed by tubules (2).

Nephrons are functional units of each kidney. There is around 1 million functional units, consisting of simple, single layered epithelium along its entire length. Each nephron contains: renal corpuscle, where large amounts of fluid are filtered from the blood, and of long tubules which consist of: proximal tubule, a thin descending and a thin ascending limb of loop of Henle,



distal tubule and collecting tubules and ducts, in which urine is formed from the filtered fluid on its way to the pelvis of the kidney. Cortical nephrons are those nephrons that have glomeruli located in the outer cortex; having short loops of Henle penetrating short distance into the medulla. Juxtamedullary nephrons are those that have glomeruli deep in the renal cortex near the medulla; long loops of Henle dip deeply into the medulla (3).

### 1.2.1. Renal Corpuscles and Blood Filtration

Renal corpuscle is at the beginning of each nephron, containing a tuft of glomerular capillaries called the glomerulus, which is surrounded by glomerular (Bowman) capsule, an epithelial double-walled capsule. Glomerular capillaries are closely enveloped with the internal (visceral) layer of Bowman's capsule. The surface of the capsule is formed by the outer parietal layer. Capsular (urinary) space is between the two capsular layers, which is responsible for receiving the fluid filtered through the capillary wall and visceral layer. Each renal corpuscle has a vascular pole and a tubular pole. Vascular pole is where the afferent arteriole enters and the efferent arteriole leaves. Tubular pole is where the proximal convoluted tubule begins (2).

The outer parietal layer of a glomerular capsule has a simple squamous epithelium, which is supported externally by a basal lamina. At its tubular pole, epithelium changes to the simple cuboidal epithelium that continues and later forms the proximal tubule. The visceral layer of a renal corpuscle consists of stellate epithelial cells, podocytes, which compose the apparatus for renal filtration together with the capillary endothelial cells. Every podocyte has its own cell body, from which primary processes extend and curve around a length of glomerular capillary. Each primary process gives rise to secondary processes (pedicles). The pedicles cover most of the capillary surface and are in direct contact with the basal lamina (2).

Elongated spaces are between the interlocked pedicles, also called filtration slit pores that are 30 nm wide. Slit diaphragms are spanning adjacent pedicles and bridging the slit pores. Slit diaphragms are specialized tight junctions composed of nephrins, glycoproteins, proteoglycans and other proteins important for renal function. These proteoglycans and glycoproteins together form many openings within the slit diaphragm, with a surface that is of negative charge (2).

Thick glomerular basement membrane is located between the fenestrated endothelial cells of the capillaries and the covering podocytes. Basement membrane is of considerable

importance for filtration barrier that separates the blood from the capsular space. It was formed by fusion of the podocyte and capillary produced basal lamina. This fused basement membrane has laminin and fibronectin that bind integrins of both the podocyte and endothelial cell membrane. Large proteoglycans and the meshwork of cross-linked type IV collagen restrict passage of large proteins. Amino acids are reabsorbed in the proximal tubule, while smaller proteins filtered from plasma are degraded (2).

Capillaries of each glomerulus are situated between the afferent and efferent arteriole, the muscle which causes increased hydrostatic pressure in these vessels, which favors filtration of plasma across the glomerular filter. Glomerular capillaries, when compared to other capillaries, have high hydrostatic pressure. Degree of constriction of each arteriole is regulated by hormonal and neuronal inputs (2). The total glomerular filtration area of an adult is 500 cm<sup>2</sup>, and GFR at 125 mL/min or 180 L/d. The kidneys filter the entire blood volume 60 times every day, considering that the total amount of circulating plasma is 3 L. 20% of the blood plasma entering a glomerulus is filtered into the capsular space. Apart from containing very little protein, the initial glomerular filtrate has a chemical composition similar to that of plasma. Glomerular filtration is relatively nonselective, except the plasma proteins or substances bound to them essentially all solutes in the plasma are filtered (3).

Renal corpuscles also contain mesangial cells. They resemble vascular pericytes in having contractile properties, they also produce components of an external lamina. They often stain more darkly than podocytes, by which are distinguished from podocytes. They and their surrounding consist of the mesangium, which fills interstices between capillaries that lack podocytes. They are responsible for many functions, such as: physical support of capillaries within the glomerulus, secretion of cytokines, prostaglandins and factors for immune defense and repair in the glomerulus, adjusted contractions in response to blood pressure changes, phagocytosis of protein aggregates that stick to glomerular filter (3).

### 1.2.2. Proximal Convulated Tubule

At the tubular pole of the renal corpuscle, the simple squamous epithelium of the capsule's parietal layer is continuous with the simple cuboidal epithelium of the proximal convoluted tubule (PCT) (2). These long tubules fill most of the cortex. PCT is responsible for both secretion and reabsorption. Most of the water, sodium and chloride, as well as glucose, amino acids, and vitamins that are filtered from plasma are reabsorbed in PCT. It secretes

organic acids and bases by its transporters, this way clearing out creatinine and bile salts, urate and catecholamines as well as potentially harmful drugs or toxins, being of great importance in a drug clearance (3).

The cells of the proximal tubules have acidophilic cytoplasm due to abundant mitochondria and central nuclei, this way supporting powerful active transport process (3). The cell apex consists of many long microvilli, together forming brush border in the lumen, facilitating reabsorption. Because of the large cells, transverse section of each PCT contains only 3-5 nuclei (2).

The apical cytoplasm of PCT cells near the base of the microvilli, consists of many pits and vesicles that are indicating active endocytosis and pinocytosis. PCT cells also have many membrane invaginations and lateral interdigitations with neighboring cells. Along the basal invaginations where long mitochondria is concentrated is responsible for the supply of ATP for the membrane proteins involved in active transport (2).

### 1.2.3. Loop of Henle

Loop of Henle is a U-shaped structure that consists of thin and thick descending limb and thin ascending limb (3). Both thin descending and ascending limbs are composed of simple squamous epithelia. Both thin walls consist of squamous cells with only few mitochondria, with prominent lumen. The thin ascending limb becomes the thick ascending limb, which is composed of simple cuboidal epithelium and many mitochondria, extending as far as the macula densa near nephron's glomerulus in the outer medulla (2).

The loop of Henle with surrounding interstitial connective tissue are responsible for adjusting the salt content of the filtrate. Cuboidal cells form thick ascending limb transport sodium and chloride ions from the tubules into the hyaluronate-rich interstitium by an active transport, making it hyperosmotic (2). This way the filtrate is concentrated by passive withdrawal of water from the thin descending part of the loop, highly permeable to water, and moderately permeable to urea and sodium. Both ascending limbs are impermeable to water, the thick segment of the loop of Henle only absorbing NaCl and potassium by an active transport due to high metabolic activity (3). The thick ascending limb of the loop of Henle is the site where "loop" diuretics take action. This flow of blood in opposite direction in the descending and ascending loops of the vasa recta helps to maintain the hyperosmotic

interstitium. The interstitial osmolarity is about four times that of the blood at the pyramid tips (2).

#### 1.2.4. Distal Convoluted Tubule and Juxtaglomerular Apparatus

As the ascending limb of the nephron enters the cortex, it is straight and forms the macula densa, and as it bends becomes distal convoluted tubule (DCT). Much less tubular reabsorption occurs here, most of the ions are being reabsorbed here, sodium, potassium and chloride. It is impermeable to water and urea, being referred to as diluting segment (3). The simple cuboidal cells of the distal tubules are smaller than those in proximal tubules, they have no brush border and have more empty lumens. Since distal tubule cells are smaller and flatter, more nuclei are seen in sections. They also have fewer mitochondria, which makes them less acidophilic (2). It is the site where thiazide diuretics take action, used for treatment of hypertension and heart failure. The rate of  $\text{Na}^+$  absorption and K secretion in distal tubule is regulated by aldosterone, secreted by the zona glomerulosa cells of the adrenal cortex (3).

#### 1.2.5. Juxtaglomerular apparatus

Juxtaglomerular apparatus is a part of specialized sensory structure, utilizing feedback mechanism to keep the rate of glomerular filtration relatively constant. Juxtaglomerular cells release renin, which then cleaves the plasma protein angiotensinogen into angiotensin I, an inactive decapeptide. Angiotensin converting enzyme (ACE) on lung capillaries converts this to angiotensin II, which then stimulates adrenals to secrete aldosterone. Aldosterone promotes sodium and water reabsorption, this way helping to increase the blood pressure (2).

### 1.2.6. Collecting Ducts

The connecting tubule, the last part of each nephron, extends from each nephron and several join together in the cortical medullary rays to form collecting ducts. Collecting ducts are formed of simple cuboidal epithelium, and these merge further as larger, straight collecting ducts in the outer medulla, running to the tips of the medullary pyramids becoming columnar cells. Several collecting ducts merge further as a papillary duct in the apex of the pyramid, which later delivers urine to the minor calyx.

The medullary collecting ducts are the final site for water reabsorption. Collecting ducts are mainly composed of principal cells, which are particularly rich in aquaporins. Aquaporins function as specific channels for water molecules, so called integral membrane pore proteins (2).

Antidiuretic hormone (ADH), also called vasopressin is released from the posterior pituitary gland, makes collecting ducts more permeable to water, as the body becomes dehydrated and osmolarity of fluids increases above normal (3). As ADH is binding its receptor, it stimulates insertion of aquaporins into the apical membrane, causing water movement through the cell. The high osmolarity of the interstitium is drawing blood passively from the collecting ducts, thus concentrating the filtrate (2). The water immediately enters the blood through vasa recta. Thus, ADH secretion determines whether the kidney excretes concentrate or dilute urine (3).

### 1.3. Congenital anomalies of the kidney and urinary tract

Congenital anomalies of the kidney and urinary tract (CAKUT) are a broad spectrum of different structural malformations that happen at birth, and are the leading cause of end stage renal disease in both pediatric and adult population. They are characterized by defects in embryonic kidney development. CAKUT causes 20% of all congenital malformations, being the most common form of malformations at birth (4,5). Exposure to environmental risk factors or the dysfunction of genes can cause disturbances to normal nephrogenesis and lead to CAKUT (4). It is mostly presented by recurrent urinary tract infections (UTI) and/or obstruction (6). We have many different phenotypes belonging to CAKUT, such as: kidney dysplasia/kidney hypoplasia, meaning that kidneys are either congenitally small, malformed,

or both (4,6). Renal agenesis is one of the most severe examples of CAKUT. It is the complete absence of renal tissue at birth, which can be either unilateral or bilateral (6). While unilateral renal agenesis (URA) leads to hypertension, proteinuria and early renal failure, it is compatible with life (7). Bilateral Renal Agenesis (BRA) is almost invariably fatal at birth (6,7). Polycystic kidney disease (PKD) is the most common inherited disease, mostly caused by PKD1 gene mutations. PKD is characterized by fluid-filled cysts on the kidneys, causing them to enlarge and further compromising the renal function. There is also multicystic renal dysplasia due to abnormal nephron development, and there is minimal or nonfunctional renal tissue. Vesicourethral reflux (VUR) causes retrograde flow of urine from bladder up to ureter (6). Megaureter, an abnormal dilation of ureter, ectopic ureter, duplex collecting system and horseshoe kidney also belong to CAKUT. Posterior urethral valves are the most common cause of bladder outlet obstruction in males, and ureteropelvic junction obstruction is the most common CAKUT malformation (4,6). CAKUT may also appear either as a part of a systemic condition or as an isolated feature. There can also be extrarenal manifestations (5).

#### 1.4. GREB1L

Growth regulation by estrogen in breast cancer like-1 (GREB1L) is part of a chromatin complex with steroid hormone and retinoic acid receptors, and has a role as a coactivator in retinoic acid-mediated transcription (8). Initially GREB1L was discovered as a paralog of growth regulation by estrogen in breast cancer 1 (GREB1) which has high correlation with both androgen and estrogen receptor expression in prostate and breast cancer cell lines and primary tumors. Its expression was upregulated in treatment of a human breast carcinoma cell line upon estrogen treatment. Greb1 acting as a coactivator of the estrogen receptor with both GREB1L and Retinoic acid receptor (Rar) components resides in a chromatin complex. GREB1L is upregulated in a cell line model of retinoic acid signaling (7).

#### 1.4.1. Retinoic acid signaling pathway

Retinoic acid (RA) is derived from vitamin A (retinol), and is shown by various studies to have an important role in formation of most organs and tissues, including the kidney (7, 9). Retinoids are a group of compounds composed of three basic parts: a polar carbon-oxygen functional group, a trimethylated cyclohexene ring which is a bulky hydrophobic group and a conjugated tetraene side chain that functions as a linker unit (10). RA is synthesized from an inactive precursor, retinol, by enzymes belonging to the retinaldehyde dehydrogenase and retinol dehydrogenase families. The first step in RA synthesis is mediated by retinol dehydrogenase, which converts retinol to retinaldehyde. Enzymes that convert retinaldehyde to retinoic acid at many sites of active RA signaling, are selectively expressed in the embryo, where they are crucial for regulating the availability and synthesis of RA (9). These enzymes belong to the Raldh family. Raldh2 was shown to be responsible for most RA synthesis in the embryo. In stromal mesenchyme of the outer cortex of the embryonic kidney Raldh2 was localized, while Raldh3 was expressed in the ureteric bud. Once in cells, RA binds nuclear receptors called retinoic acid receptors (Rars) and retinoic x receptors (RXR), which are DNA-binding transcriptional regulators via retinoid response elements (9, 10). The Rar receptor family has 8 members encoded by 3 genes - Rarb, Rarg, Rara that are expressed during development, inactivation of which result in embryonic abnormalities. Any mutations in genes encoding RAR can cause a renal agenesis phenotype (7, 9). Furthermore, aberrantly expressed RXR-related genes found in a mouse model of PKD, suggests that aberrant RXR signaling is connected with PKD cytogenesis. Interestingly, human promotor for PKD1 is activated by RA, the gene when mutated is responsible for 85% of clinical cases (10).

#### 1.4.2. The role of retinoic acid signaling in the kidney

RA signaling is involved in the specification and development of the genitourinary system, including the early pronephric kidney morphogenesis and metanephros development. Moreover, in the developing metanephros, retinoic acid can promote ureteric bud outgrowth, by regulating Ret gene expression (7,9). Binding of Ret to its ligand, Gdnf, induces a program of epithelial cell remodeling that controls primary branch formation and branching morphogenesis within the kidney. RA signaling pathway has well understood defined role in renal development, for example signaling between the ureteric bud epithelium is forming

collecting duct system and ureter, while metanephric mesenchyme and stromal mesenchyme are differentiating into the nephron and into the renal interstitium, respectively (9). Gestational vitamin A deficiency shown by pregnant mice model led to reduction in nephron number and severe renal defects in the fetus. Retinoids were also shown to have an anti-fibrotic and cytoprotective effects in the kidneys. Thus, conversion of retinoids to RA is essential for regulation of a wide range of biological processes, such as development, proliferation and differentiation (10). As *Greb11* is residing in a chromatin complex with RAR members, and being a coactivator of RAR, leads to conclusion that proper activation of *Greb11* expression by retinoic acid signaling is crucial for proper kidney development, dysregulation of which leads to urinary tract malformations (7,11).

#### 1.4.3. GREB1L and kidney

Analysis of human fetal tissue showed expression of GREB1L in kidney, while in adults the highest expression was in vagina, cervix, and epididymis (11). When referring to the kidney and its development however, previous studies have shown *Greb11* expression during all stages of nephrogenesis, the strongest being in the nephrogenic zone in the cortical region of the kidney. GREB1L was also found expressed in the S-form of a nephron, developmental stage undergoing intense cellular growth and morphogenesis, corresponding to early nephrogenesis, thus playing a major role in mediating cell growth and early kidney development (12). For example, dissection of the urogenital system in *Greb11*<sup>-/-</sup> embryos showed absence of the kidneys. Furthermore, its role in tubulomorphogenesis was shown by selecting a clone with a homozygous deletion, and a control in which no mutation was identified. Results have shown that a control was able to form tubule-like structures, while homozygous deletion showed no tubule formation, but only small spherical structures. When homozygous deletion phenotype was rescued by transfection of a Green fluorescent protein-fused (GFP-fused) human GREB1L, GFP-positive cells formed elongated structures as in the first steps of tubulomorphogenesis, thus demonstrating that GREB1L is also involved in tubulogenesis (11). This is translated in humans as heterozygous loss-of-function (with maternal bias in transmission) of *GREB1L* function that is associated with CAKUT phenotypes, most of the time being renal dysplasia/hypoplasia, renal agenesis, and vesicoureteral reflux, proving that heterozygous loss-of-function of *GREB1L* function mutations in humans cause BRA, a phenotype also showed by *Greb11*<sup>-/-</sup> mice (8,11). Haploinsufficiency of *GREB1L* revealed non- syndromic inner ear malformations as the primary cause of the disease (12).



*GREB1L* was also found to be connected to other non-renal defects, such as abnormal number of ribs, heart defects, hepatic fibrosis and enlarged thymus. Additionally, *GREB1L* mutation was also observed in genital tract defects with different severities in females, from unilateral fallopian tube or ovarian agenesis to uterus agenesis phenotype and Mayer-Rokitansky-Küster-Hauser (MRKH) syndrome, showing that *GREB1L* also affects the early steps of female genital development apart from the kidney. The previous examples were also confirmed with the absence of kidneys and genital tracts in E13.5 knockout mice embryos (8). Additionally, *GREB1L* was also observed in PCT of 1.5-year-old human kidney, and significantly more expressed in the glomeruli during human fetal development, highlighting the importance of higher expression of *GREB1L* in the glomeruli of nephrons during final nephrogenesis. Since there was kidney expression of *GREB1L* in the postnatal period, this is implicating the importance for maintenance of kidney homeostasis, and not only for the onset of CAKUT in the case of mutation (12). In conclusion, all of the previous studies above emphasize the key role of *GREB1L* not only in early fetal kidney differentiation and genital tract development, but also in the maintenance of kidney homeostasis later in life (11,12).

### 1.5. Disabled-1 protein, *yotari* mice and *reeler* mice

Disabled-1 (Dab1) is an adaptor protein that contains three main domains: N-terminal protein interaction/phosphotyrosine binding domain, C-terminal serine/threonine-rich region, and a tyrosine rich region. Dab1 is a cytoplasmic protein which has a role in regulating lamination and neuronal migration during brain development. Dab1 also plays an important role in Reelin signaling pathway, as Dab1 tyrosine phosphorylation is induced by binding of Reelin to its receptors. Phosphorylated Dab1 activates multiple signaling cascades, resulting in precise neuronal positioning (13). Reelin is secreted by Cajal-Retzius cells in the marginal zone in the brain, and has an important role in the development of the mammalian cerebral cortex. This process is severely disturbed in mouse mutant *Reeler* (14). Main feature of *Reeler* mice is that in laminated brain structures neurons are aberrantly positioned. *Reeler* mouse are characterized by tremor, ataxia and a reeling gait. This was further supported by the *Reeler* and *Dab1*<sup>-/-</sup> or *yotari* mice models (13).

*Yotari*, an autosomal recessive mouse mutation, exhibits pathological and behavioral phenotype identical to *Reeler*, but the mutation is not identical. *Yotari* mouse presents with ataxia, tremor and early death around weaning (15,16). *Reeler* mice arise from mutations in the *Reelin* gene, where Reelin plays a critical role in regulation of final migratory phase of histogenesis (16,17). *Reeler* phenotype is connected with failure of brain lamination which is controlled by *Reelin* (17). *Yotari* arise from mutations in *mDab1*, a mouse gene related to a drosophila gene disabled, which is an adaptor molecule functioning in neural development. mDab1 is a phosphoprotein that functions as an intracellular adaptor in protein kinase pathways, and is tyrosine phosphorylated during mouse embryogenesis (18,19). It was thought at first that *yotari* expresses little or no mDab1 protein and a mutated form of mDab1 messenger RNA, but new studies have shown that the *yotari* mouse is in fact producing an aberrant mDab1 protein, due to lack of phosphorylation of mDab1 (19). As mDab1 is expressed in neuronal populations exposed to *Reelin*, this all leads to conclusion that *Reelin* and *mDab1* function as signaling molecules that regulate cell positioning during brain development (20).

### 1.5.1. DAB1 in the kidney

During fetal kidney development, DAB1 has shown strong expression in both DTC and PCT. DAB1 has decreased expression in the postnatal period, which appears that DAB1 has a more important role in the fetal period than in the postnatal period. High DAB1 expression in DCT proves its role in tubular formation (21). Thus, DAB1 is proven to regulate the formation and function of kidney structures during human fetal kidney development (22). *Yotari* mouse model expresses smaller kidneys, with thinner cortex and reduced diameter of nephron segments. This all reveals that *Dab1* functional inactivation leads to CAKUT phenotype and a loss of functional kidney tissue of *yotari* mouse (23).

There were many previous studies that have proven the role of *Greb11* for normal kidney development, but at the moment there are no studies conducted on the function of *Greb11* in *Dab1*<sup>-/-</sup> mice.

## **2. OBJECTIVES**

The aim of this study was to analyze the expression and localization of Greb11 in the nephrons of *yotari* (*Dab1*<sup>-/-</sup>) and *wildtype* (*Dab1*<sup>+/+</sup>) mice in order to further develop their suggested importance not only in mammal kidneys overall, but also the significance they may have particularly in the *yotari* mouse nephron.

#### Hypotheses

Greb11 marker will have significantly different expression pattern in the kidney structures of *yotari* and *wildtype* genotypes.

### **3. MATERIALS AND METHODS**

### 3.1. Ethics

The experimental protocol was approved by the Ethics Committee of the University of Split School of Medicine and conducted according to the Croatian Animal Welfare Act.

### 3.2. Experimental animals

Two groups of pups were observed according to their *Dabl* gene status: *yotari* (*Dabl*<sup>-</sup>) and *wildtype* (*Dabl*<sup>+/+</sup>) controls. The *yotari* mice were produced by PGK-neo cassette which resulted in target disruption of the first 47 codons of the gene coding for the protein-interlacing domain (PI-PTB). In standard polycarbonate cages at least one mouse from each group was group-housed and raised. Their environment was a temperature controlled (23±2°C) room with a 12-h light/dark cycle, and their access to water and food was *ad libitum*.

### 3.3. Tissue collection and immunohistochemistry

Pregnant and nonpregnant mice from both groups were anesthetized deeply with pentobarbital on the 13.5<sup>th</sup> gestational day and on 4<sup>th</sup> and 14<sup>th</sup> postnatal day, respectively. Afterwards they were transcardially perfused with phosphate buffer saline (PBS, pH 7.2) and 4% paraformaldehyde (PFA) in 0.1 M PBS. The removed fetuses and kidneys were then embedded in paraffin and cut transversely into 7 micrometer thick sections. Within each *yotari* and *wildtype* group, 4 fetal slides and 5 postnatal slides consisting of 11 fetal sections and 7 postnatal kidney sections, respectively, were then allocated for each group to be further processed and analyzed. After the deparaffinization of the samples with xylene, the sections were rehydrated with ethanol and water, and then quickly rinsed with distilled water. Next, after heating the samples in sodium citrate buffer (pH 6.0) for 30 min in the Epitope Retrieval Steamer, we allowed them to cool down at room temperature, and then washed them in PBS, lastly, we separated the samples with a PAP pen hydrophobic pencil. Then we incubated the sections with primary antibodies after cooling to room temperature.

Rabbit polyclonal Anti-Greb11 (Invitrogen PA5-60651) was diluted 1:100 in Dako REAL antibody diluent (Dako Denmark A/S, Glostrup, Denmark), and then applied to the sections. The primary antibodies were left overnight in a humidified chamber at room temperature, and then the sections were rinsed with PBS, and then incubated for 1h in a humidified chamber with secondary antibodies: Alexa Fluor 488 AffiniPure Donkey Polyclonal Anti-Rabbit IgG (Jackson IR, 711-545-152) for Greb11 primary antibody-stained samples.

In the next step we rinsed the sections a final time with PBS, and stained cell nuclei with 40,6-Diamidine-20-phenylindole dihydrochloride (DAPI) using multicolour fluorescent techniques. Further, stained kidney sections were viewed and photographed using a BX51 microscope (Olympus, Tokyo, Japan) equipped with a DP71 digital camera (Olympus), The images were then processed with Cella Imaging Software for Life Sciences Microscopy (Olympus). Different structures of the each fetal and kidney section were analyzed: renal vesicle, ureteric bud, metanephric mesenchyme in the fetal sections, and glomeruli, proximal (PCT) and distal convoluted tubules (DCT) in both fetal and postnatal kidney samples (Figures 1-3). For each of the fetal and postnatal kidney sections, 5 images with non-overlapping fields were photographed at x40 objective magnification, with each field constituting one microimage.

Using ImageJ software (National Institutes of Health, Bethesda, MD, USA), we performed the analysis of glomeruli, DCTs and PCTs by counting the number of positive or immunoreactive Greb11 cells as well as negative cells. Greb11 immunoreactive cells were determined by the color staining intensity (red) in different kidney structures (Figure 1-3). In the last step we compared the percentage of Greb11 positive cells in the three kidney structures (glomeruli, PCT and DCT) both within and between the *yotari* and *wildtype* groups.

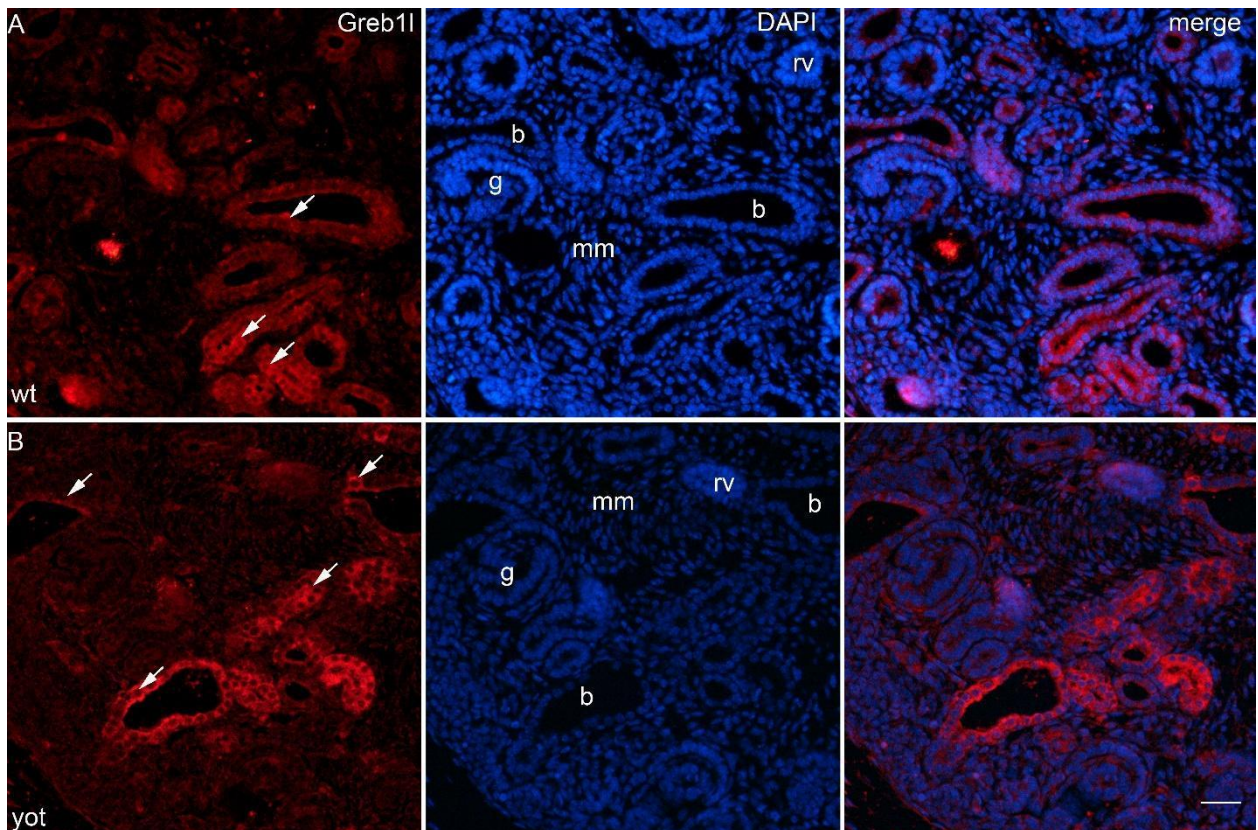
### **3.4. Statistics**

The Kolmogorov-Smirnov-test was applied for testing the data distribution, after which statistical analysis was performed using a Kruskal-Wallis-test in GraphPad (GraphPad Software, La Jolla, CA, USA) to examine differences in the 3 structures (glomeruli, PCT and DCT) within each mouse group. Comparison of the kidney structures between the *yotari* and *wildtype* groups was performed using a t-test. The percentage of positive cells was expressed as the mean  $\pm$  standard deviation (SD). Statistical significance was set at  $p < 0.05$ .

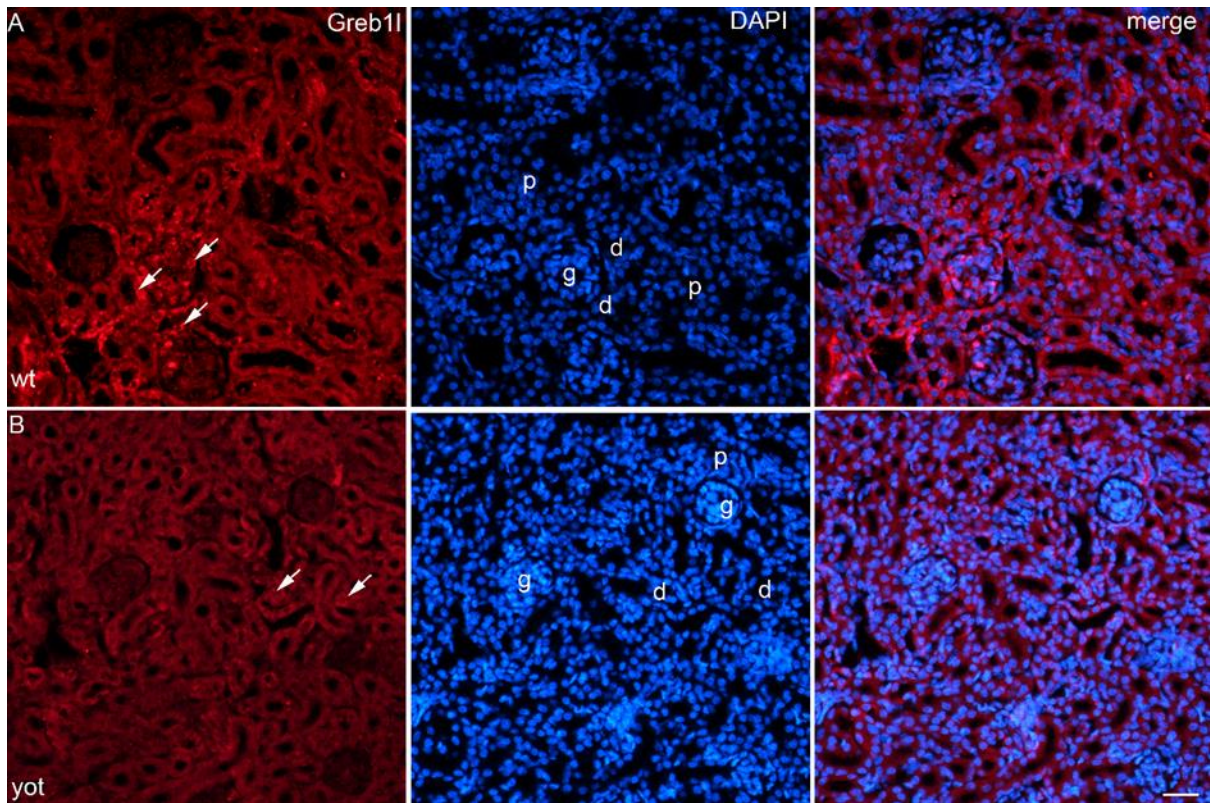


## **4. RESULTS**

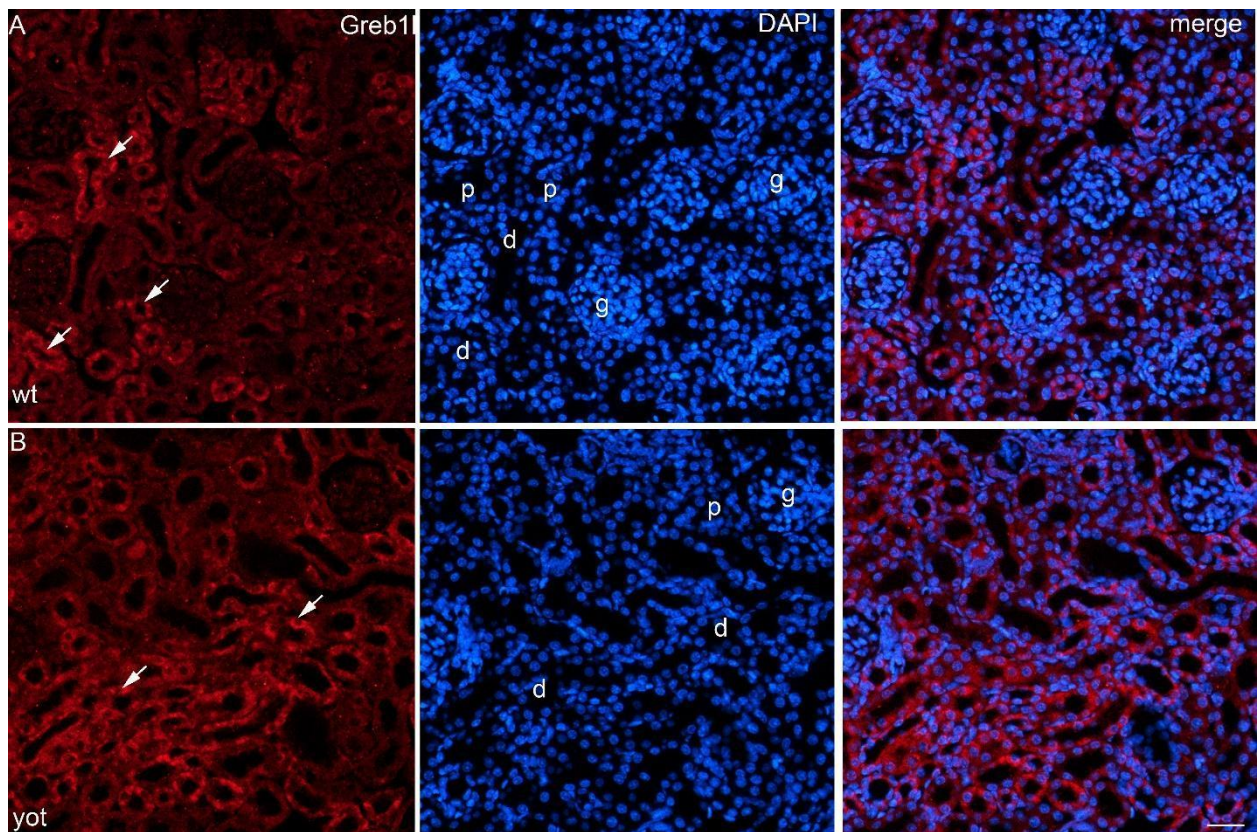
By immunofluorescence staining, localization of positive expression of Greb11 in three different nephron structures (PCT, DCT, and glomeruli) of 13.5 day old embryonal kidney samples, 4 and 14 day old postnatal kidney samples of both, *yotari* and *wildtype* mice is shown. We compared the percentages of positive cells with Greb11 expression between each group. *Figures 1-3* show examples of the localization and intensity of expression of Greb11 in the samples.



**Figure 1:** Immunofluorescence staining with Greb11 antibodies (arrowheads) and DAPI (blue stained nucleus) of 13.5<sup>th</sup> embryonal day of *wildtype* (wt) (figure A) and *yotari* (yot) (figure B) mouse embryonal kidney samples. Nuclear DNA DAPI staining merged with Greb11 immunofluorescence in the third column is shown in parallel (merge). Legend: rv - renal vesicle, b - ureteric bud, mm - metanephric mesenchyme, g - glomerulus, p - proximal convoluted tubule, d - distal convoluted tubule. The scale bar is 20  $\mu$ m and refers to all images.



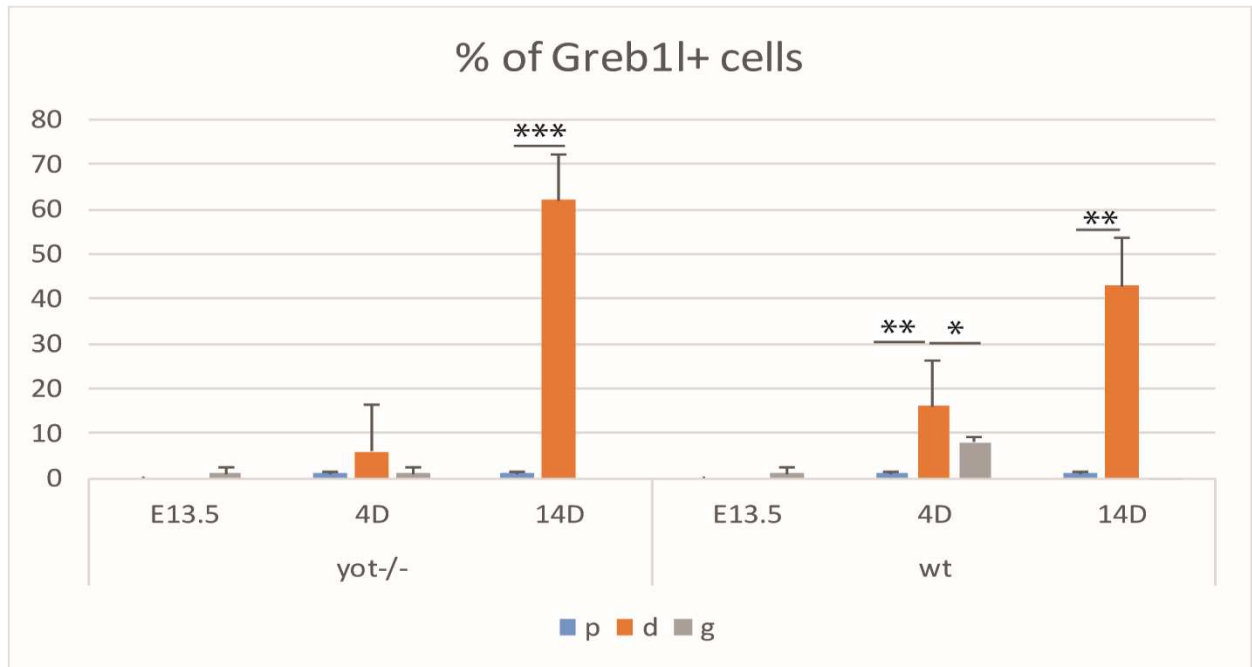
**Figure 2:** Immunofluorescence staining with Greb11 antibodies (arrowheads) and DAPI (blue stained nucleus) of 4<sup>th</sup> postnatal day of *wildtype* (wt) (figure A) and *yotari* (yot) (figure B) mouse kidney samples. Nuclear DNA DAPI staining merged with Greb11 immunofluorescence in the third column is shown in parallel (merge). Legend: g - glomerulus, p - proximal convoluted tubule, d - distal convoluted tubule. The scale bar is 20  $\mu$ m and refers to all images.



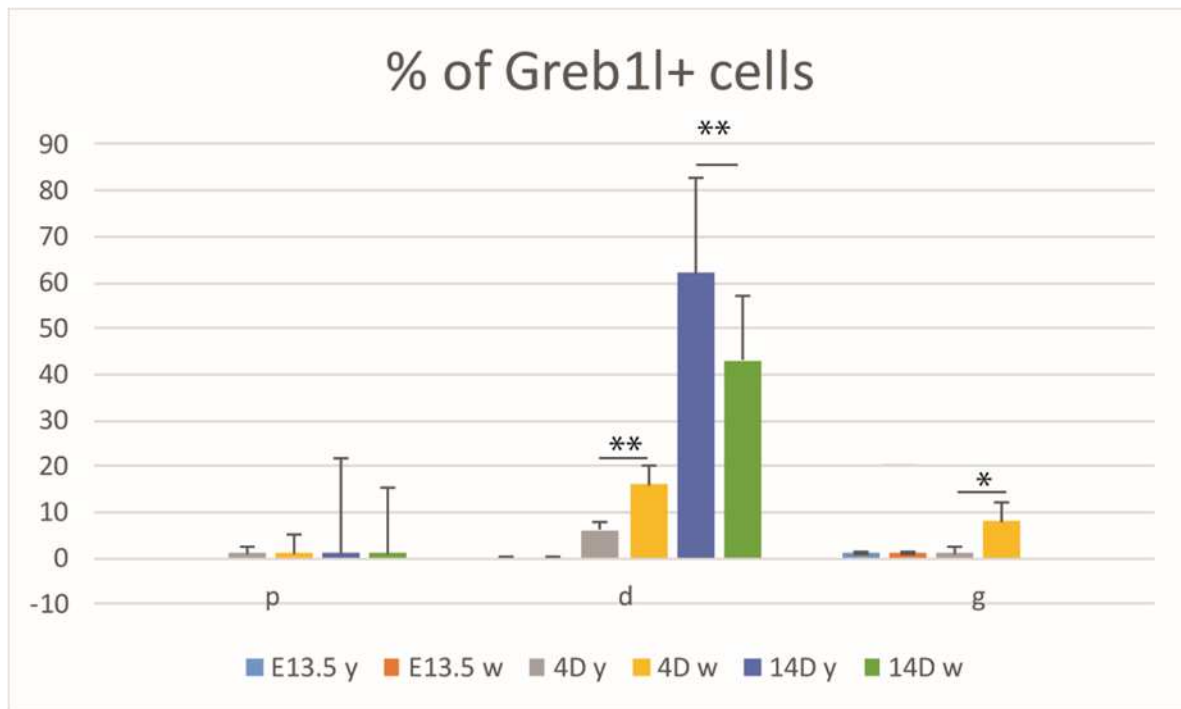
**Figure 3:** Immunofluorescence staining with Greb11 antibodies (arrowheads) and DAPI (blue stained nucleus) of 14<sup>th</sup> postnatal day of *wildtype* (wt) (figure A) and *yotari* (yot) (figure B) mouse kidney samples. Nuclear DNA DAPI staining merged with Greb11 immunofluorescence in the third column is shown in parallel (merge). Legend: g - glomerulus, p - proximal convoluted tubule, d - distal convoluted tubule. The scale bar is 20  $\mu$ m and refers to all images.

In embryonal day E13.5 glomeruli of both, *yotari* and *wildtype* group express 1% of Greb11 immunoreactive cells, and no positive cells in PCTs and DCTs, showing no statistical significance within the two groups (Figure 4). On postnatal day 4D, PCTs express equal percentage of 1% positively stained cells in both *yotari* and *wildtype* groups, also showing no statistically significant difference. On the contrary, DCT is shown to express 6% in *yotari* and 16% in *wildtype* group, while glomeruli express 1% in *yotari* and 8% in *wildtype* group. This data indicates no statistical significance in the *yotari* group, while *wildtype* group has shown significantly higher percentage of Greb11 in DCT compared to PCT ( $p < 0.01$ ), and smaller but still significant difference between DCT and glomeruli ( $p < 0.05$ ) (Figure 4). Finally, in the 14D postnatal day in the Greb11 stained *yotari* and *wildtype* group, the structure with most immunoreactive cells was the DCT with 62%, and 43%, respectively. The PCT with 1% expression and glomeruli with no expression is observed in both *yotari* and *wildtype* groups.

The *yotari* group has shown the most statistically significant positive cells in the DCT compared to PCT ( $p < 0.001$ ), and less, but still high significance in *wildtype* group between DCT and PCT ( $p < 0.01$ ) (Figure 4).



**Figure 4:** The distribution of percentages of Greb1 positive cells in the proximal convoluted tubules (p;blue), distal convoluted tubules (d;orange), and glomeruli (g;grey) in 13.5<sup>th</sup> embryonal day (E13.5), 4<sup>th</sup> postnatal day (4D) and 14<sup>th</sup> postnatal day (14D) kidneys of *wildtype* (wt) and *yotari* (*yot*<sup>-/-</sup>) mice genotypes. Data is presented as the mean  $\pm$  standard deviation (SD) (vertical line). Significant differences between the p, d, and g within each mice group are indicated by \* $p < 0.05$ , \*\* $p < 0.01$ , \*\*\* $p < 0.001$  (Kolmogorov-Smirnov-test for data distribution followed by Kruskal-Wallis-test).



**Figure 5:** The distribution of percentages of Greb1l positive cells in the proximal convoluted tubules (p), distal convoluted tubules (d), and glomeruli (g) in E13.5 embryonal day and 4D and 14D postnatal kidneys of *wildtype* (w) and *yotari* (y) genotypes. Significant differences between the p, d, and g in different genotypes are indicated by \* $p < 0.05$ , \*\* $p < 0.01$  (Kolmogorov-Smirnov-test for data distribution followed by a t-test).

When comparing the percentages of positively expressed cells between groups of the Greb1l immunofluorescence-stained samples there was no statistically significant difference between the percentages of positively expressed cells in the glomeruli, PCT and DCT of *yotari* and *wildtype* samples in E13.5 (Figure 5). In the DCT in the 4D postnatal day, the *wildtype* group had a statistically significant higher percentage of positive Greb1l expressing cells when compared against the *yotari* group ( $p < 0.05$ ) (Figure 5). Moreover, with regard to glomeruli in the 4D postnatal day, there was also higher percentage of positive cells with statistical significance in the *wildtype* group when compared to *yotari* ( $p < 0.01$ ) (Figure5). Lastly, there were the most statistically significant higher percentage of immunoreactive cells in the DCT of *yotari* mice in comparison to *wildtype* groups in the 14D postnatal day ( $p < 0.01$ ) (Figure 5).

## **5. DISCUSSION**

The aim of this study was to determine the expression pattern of *Greb11* in the kidneys of *yotari* and *wildtype* mice in E13.5, 4D and 14D nephrons, in order to further distinguish their role in kidney structure and function. After researching current literature, this study is one of the first which has looked into the expression of *Greb11* in the nephrons of *yotari* mice.

In both mouse groups in 14D old nephron, the DCT showed the highest percentage of positive *Greb11* expression, where *yotari* group showed higher expression than the *wildtype* group. The expression of *Greb11* in PCT and glomeruli in both groups was almost non-existent. This finding differs from the previous studies shown in other literature where *GREB1L* was found to be mostly expressed in PCT and weakest in DCT at different stages of embryonal development in human kidneys (12). Since *Dab1* was found to have an important role in fetal kidney structure with high expression in DCT during kidney development, and no importance in postnatal stages, gives us the possible explanation why there are higher positive *Greb11* cells present in the *yotari* group at 14D (21). As to why there is positive expression of *Greb11* in DCT cells in both mouse groups in this study cannot be fully understood from this study alone, but *Greb11* might be more important for the function of DCT during later embryonal or postnatal stages in mice and differs from that in humans. Thus, this discovery of higher *Greb11* expression in the *yotari* mouse DCT could be a starting point for further studies to develop. Since both this study's result and that of the previous mentioned study differ in results, further investigation using *yotari* mouse models of *Greb11* are required to fully establish this hypothesis.

Some levels of expression of *Greb11* were also found in the DCT in 4D old nephron in both groups, with the higher percentage in that of the *wildtype* kidney samples. There was also expression found in the glomeruli of the *wildtype* group, while in *yotari* it was almost non-existent. There was almost no *Greb11* expression in the PCT of both genotypes. This finding highlights the role of *Greb11* in signaling cascades of DCT cells in both mouse groups, and possible importance of *Greb11* expression in the glomeruli of *wildtype* in the postnatal stage. Since *Dab1* has an important role in early nephrogenesis and less at later stages, as previously mentioned we expected expression of *Greb11* in DCT of *yotari* mouse (21). Although this has not been anticipated yet in other literature using mouse models, *GREB1L* has been found to be expressed in the DCT and glomeruli at different stages of human embryonic nephron development (12).



Finally, in E13.5 kidneys in both mouse groups, all the structures had the least percentage of Greb11 immunoreactive cells. Immunoreactive cells in the glomerulus were almost non-existent, while PCT and DCT had no expression at all in both *wildtype* and *yotari* genotypes. This was surprising, especially when considering the *wildtype* samples, as previous studies have found that the peak expression of Greb11 in mice is at E13-16, and that Greb11 is important for the first steps of tubulomorphogenesis (11,12). The study on human kidneys has shown low expression of GREB1L in the glomeruli in early weeks of human fetal development, while during later more mature stages of human fetal development, GREB1L had the highest expression in the glomeruli (12). As this study only stained E13.5 mouse kidney samples, it is plausible that the importance of Greb11 in mouse nephrons development is more established in these structures at later embryonal or more mature stages of glomerular and tubular function as shown in human kidneys, or its importance in mouse glomerular and tubular expression for its differentiation and function may be completely different and therefore requires further studies. Possible explanation for no expression of Greb11 in PCT and DCT in *yotari* mice model is that *Dab1* has a proven role in tubular formation and is more expressed in the fetal period, and since there is nonfunctional *Dab1* and no tubular formation, we expect no Greb11 expression in these structures (21). Since there is a significant difference in this study's results and that of the previous mentioned studies, further investigation using *yotari* mouse models of Greb11 are required to fully establish this hypothesis.

Although this study is a sufficient starting point for Greb11 expression in the mouse kidney overall, not to mention in the unexplored *yotari* kidney, limitations should be highlighted. Firstly, only four fetal and five postnatal prepared slides, each from a separate sacrificed mouse, with eleven fetal sections and seven kidney sections was used in total, which possibly limits the power of the results. Future investigations should include samples taken from more animals in order to avoid possible type II error. Secondly, after analysis of all embryonal samples, the old lamp for color intensity was changed with the new one, which had stronger intensity and subsequently changed the appearance of prenatal kidney samples. This could give the false positive results during image analysis on postnatal kidney samples. Lastly, only one investigator analyzed the images when counting positive cells, increasing the likelihood of human error. These limitations should be taken into the account for future studies by using at least two independent investigators to analyze the images.

To conclude everything, an immunohistochemistry study of Greb11 expression in E13.5, 4D and 14D nephrons of *yotari* and *wildtype* mouse genotypes was carried out. The

results showed that the DCT of the 14D kidney had prominent expression of *Greb11* in both genotypes, suggesting a possible important role of *Greb11* in DCT at this stage. Since our result was completely opposite to the previous studies done on human kidneys, further studies are needed to be conducted in these mice to confirm this hypothesis. Since there was almost no expression of *Greb11* in other structures of the 14D kidney, we can conclude that *Greb11* is not important in these structures at this stage and this could also be a starting point for the future studies. Continuing on, both mouse groups have shown expression of *Greb11* in DCT and glomeruli of 4D kidney, with higher expression in both structures in the *wildtype* group. There was almost no expression of *Greb11* in PCT of 4D kidney in both genotypes. This could be an indication that *Greb11* has a more important role in kidneys of the *wildtype* group at this stage, because *GREB1L* has been found to be expressed in the DCTs and glomeruli at different stages of human embryonic nephron development as found in the *wildtype* group. But to confirm these suggestions, it is necessary to perform further investigations because this has not been anticipated yet in other literature using mouse models. Interestingly, decreased *Greb11* expression in PCT and DCT in both mouse groups of E13.5 kidneys, and only fair expression in glomeruli in both mice was unexpected since previous literature confirms peak expression of *Greb11* in mice is at E13-16, and *Greb11* importance for the first steps of tubulomorphogenesis. Possible explanation is with the study on human kidneys that has shown low expression of *GREB1L* in the glomeruli in early weeks of human fetal development, while during later, more mature stages of human fetal development, *GREB1L* had the highest expression in the glomeruli. Thus, the importance of *Greb11* in development of mice nephrons might be more established in these structures at later embryonal or more mature stages of glomerular and tubular function, as was shown on human kidneys, or its importance in mouse glomerular and tubular expression for its differentiation and function may be completely different, and therefore requires further study. As previously mentioned, possible explanation for no expression of *Greb11* in PCT and DCT in *yotari* mice model is that *Dab1* has proven role in tubular formation and is more expressed in fetal period, and since there is nonfunctional *Dab1* and no tubular formation, we expect no *Greb11* expression in these structures. But again, further studies using *yotari* mice models are needed to confirm this hypothesis. With everything said, it seems how kidney development pattern in *yotari* mice group is delayed in comparison to *wildtype* group, which could be a possible explanation for the discrepancy.

## **6. CONCLUSION**

1. The DCT had the highest expression of *Greb11* in 14D kidneys across both genotypes.
2. In the DCT of 14D kidney, *Greb11* was significantly more expressed in the *yotari* group, implicating that *Greb11* might play an important role in DCT during postnatal stages in this group.
3. *Greb11* expression was barely present in PCT and glomeruli in 14D in both mice genotypes, showing no significant importance at this stage.
4. Faint *Greb11* expression was found in DCT of 4D in both mouse genotypes, with significantly higher expression in the *wildtype* group, thus highlighting the possible importance of *Greb11* expression in the DCT of *wildtype* in the postnatal stage, possibly supported by studies done in human kidneys.
5. There was significantly higher expression of *Greb11* in glomeruli of 4D kidneys in the *wildtype* group, implicating a possible importance of *Greb11* expression in the glomeruli of *wildtype* in the postnatal stage, also partially supported by the study done on human kidneys.
6. There was barely any expression of *Greb11* in the PCT of both mice groups in 4D kidneys, with no significant difference, suggesting that *Greb11* has no importance in PCTs at this stage.
7. No *Greb11* expression was present in the PCT and DCT on E13.5 in both mouse groups, with no significant difference, which leads to the possible conclusion that *Greb11* expression is more important at later embryonal, or more mature stages of tubular function as shown in previous studies done on human kidneys.
8. There was fair expression of *Greb11* in the glomeruli of E13.5 kidneys in both mouse groups, with no significant difference, which might implicate that *Greb11* expression is more important at later embryonal, or more mature stages of glomerular function as shown in previous literature.
9. *Yotari* mice showed significant expression of *Greb11* in the DCT of 14D kidney, while *wildtype* showed significantly highest expression of *Greb11* in DCT and glomeruli of 4D kidney, and finally only fair expression of *Greb11* was present in E13.5 kidney of both mice groups with no statistical significance.
10. Overall, kidney development pattern in *yotari* mice seems to be delayed in comparison to *wildtype* group, which might be an explanation for the discrepancy.

## **7. REFERENCES**

1. Sadler TW. Urogenital system. In: Taylor C, Pecarich L, editors. Langman's medical embryology. 13th ed. London: Wolters Kluwer; 2015. p. 250-3.
2. Mescher LA. The urinary system. In: Lange, editor. Junqueira's basic histology. 13th ed. London: McGraw-Hill Education; 2013. p. 385-3.
3. Guyton A, Hall J. Textbook of medical physiology. 12th ed. Philadelphia: Elsevier, Inc; 2011.
4. Nicolaou N, Renkema KY, Bongers EM, Giles RH, Knoers NV. Genetic, environmental, and epigenetic factors involved in CAKUT. *Nat Rev Nephrol.* 2015;11(12):720-31.
5. Capone VP, Morello W, Taroni F, Montini G. Genetics of congenital anomalies of the kidney and urinary tract: The current state of play. *Int J Mol Sci.* 2017;18:796.
6. Marcdante K, Kliegman R. Congenital and developmental abnormalities of the urinary tract. In: Marcdante K, Kliegman R, editors. Nelson essentials of pediatrics. 8th ed. Philadelphia: Elsevier, Inc; 2019. p. 629-30.
7. Brophy PD, Rasmussen M, Parida M, Bonde G, Darbro BW, Hong X et al. A gene implicated in activation of retinoic acid receptor targets is a novel renal agenesis gene in humans. *Genetics.* 2017;207:215-28.
8. Jacquinet A, Boujemla B, Fasquelle C, Thiry J, Josse C, Lumaka A et al. GREB1L variants in familial and sporadic hereditary urogenital dysplasia and Mayer-Rokitansky-Kuster-Hauser syndrome. *Clin Genet.* 2020;98:126-37.
9. Rosselot C, Spraggon L, Chia I, Batourina E, Riccio P, Lu B et al. Non-cell-autonomous retinoid signaling is crucial for renal development. *Development.* 2010;137:283-92.
10. Das BC, Thapa P, Karki R, Das S, Mahapatra S, Liu TC et al. Retinoic acid signaling pathways in development and diseases. *Bioorg Med Chem.* 2014;22:673-83.
11. De Tomasi L, David P, Humbert C, Silbermann F, Arrondel C, Tores F et al. Mutations in greb1l cause bilateral kidney agenesis in humans and mice. *Am J Hum Genet.* 2017;101:803-14.

12. Lasić V, Kosović I, Jurić M, Racetin A, Čurčić J, Šolić I et al. GREB1L, CRELD2 and ITGA10 expression in the human developmental and postnatal kidneys: an immunohistochemical study. *Acta Histochem.* 2021;123:151679.
13. Gao Z, Godbout R. Reelin-Disabled-1 signaling in neuronal migration: Splicing takes the stage. *Cell Mol Life Sci.* 2013;70:2319–29.
14. Bock HH, May P. Canonical and non-canonical reelin signaling. *Front Cell Neurosci.* 2016;10:1–20
15. Yoneshima H, Nagata E, Matsumoto M, Yamada M, Nakajima K, Miyata T, et al. A novel neurological mutant mouse, yotari, which exhibits reeler-like phenotype but expresses CR-50 antigen/Reelin. *Neurosci Res.* 1997;29:217–23.
16. Rakic P, Caviness VS. Cortical development: View from neurological mutants two decades later. *Neuron.* 1995;14:1101–4.
17. D’Arcangelo G, Miao GG, Chen SC, Scares HD, Morgan JI, Curran T. A protein related to extracellular matrix proteins deleted in the mouse mutant reeler. *Nature.* 1995;374:719-23.
18. Howell BW, Gertler FB, Cooper JA. Mouse disabled (mDab1): A Src binding protein implicated in neuronal development. *EMBO J.* 1997;16:121–32.
19. Onoue A, Takeuchi M, Kohno T, Hattori M. Aberrant fragment of Dab1 protein is present in yotari mouse. *Neurosci Res.* 2014;88:23–7.
20. M Sheldon, D S Rice, G D’Arcangelo, H Yoneshima, K Nakajima, K Mikoshiba et al. Scrambler and Yotari Disrupt the Disabled Gene and Produce a Reeler-Like Phenotype in Mice. *Nature* 1997;389:730-3.
21. H Yoneshima, E Nagata, M Matsumoto, M Yamada, K Nakajima, T Miyata et al. A Novel Neurological Mutant Mouse, Yotari, Which Exhibits Reeler-Like Phenotype but Expresses CR-50 antigen/reelin. *Neurosci Res* 1997;29:217-23.
22. Racetin A, Jurić M, Filipović N, Šolić I, Kosović I, Durdov MG, et al. Expression and localization of DAB1 and Reelin during normal human kidney development. *Croat Med J.* 2019;60:521–31.

23. Racetin A, Filipović N, Lozić M, Ogata M, Gudelj Ensor L, Kelam N, et al. A Homozygous  $Dab1^{-/-}$  Is a Potential Novel Cause of Autosomal Recessive Congenital Anomalies of the Mice Kidney and Urinary Tract. *Biomolecules*. 2021;11:609.



## **8. SUMMARY**

**Objectives:** The expression and localization of Greb11 in the nephrons of *yotari* (*Dab1*<sup>-/-</sup>) and *wildtype* (*Dab1*<sup>+/+</sup>) mice was analyzed to further develop its suggested importance in mammal kidneys overall, but also its significance particularly in *yotari* mice nephrons.

**Materials and methods:** *yotari* and *wildtype* mice were sacrificed on the 13.5<sup>th</sup> embryonal day, and 4<sup>th</sup> and 14<sup>th</sup> postnatal day. Paraffin embedded kidney tissue sections were analyzed by immunofluorescence using Greb11 antibodies. Kidney structures were then examined by fluorescence microscope. The percentages of positive cells between each group were compared and analyzed by a Kruskal-Wallis-test, followed by a t-test.

**Results:** In 14D kidneys of both genotypes, DCT was the structure with the highest percentage of Greb11 immunoreactive cells, particularly in the *yotari* group ( $p < 0.01$ ). The highest percentage of positive Greb11 cell expression of the 4D kidney was in the *wildtype* genotype for both DCT and glomeruli ( $p < 0.01$ ). Minimal positive Greb11 cell expression of E13.5 kidney was in the glomeruli of both genotypes, with no statistical significance. No Greb11 positive cells were observed in PCT and DCT at this stage in both genotypes.

**Conclusion:** The expression pattern of Greb11 in the nephron structures of the two mouse genotypes implicates the potential importance of Greb11 in DCT in 14D kidney, especially in *yotari* mice. Overall, the *wildtype* 4D nephron showed significantly higher expression of Greb11 in DCT and glomeruli, suggesting its potential importance at this stage of kidney development. Lastly, there was almost non-existent Greb11 expression in all structures of both genotypes in E13.5 kidney, implicating that Greb11 expression pattern is more important in later stages of kidney development. Overall, it seems how kidney developmental pattern in *yotari* mice is delayed in comparison to *wildtype* group, which is a possible explanation for the discrepancy.

## **9. CROATIAN SUMMARY**

**Naslov:** PRIKAZ IZRAŽAJA GREB11 U EMBRIONALNOM I POSTNATALNOM BUBREGU  $DAB1^{-/-}$  MIŠEVA

**Cilj:** Analizirali smo izražaj i lokalizaciju Greb11 u nefronima yotari miševa ( $Dab1^{-/-}$ ) i divljeg tipa ( $Dab^{+/+}$ ) kako bi se dalje utvrdio njegov predloženi značaj u bubrezima sisavaca općenito, kao i njegov značaj posebno u bubrezima yotari miševa.

**Materijali i metode:** yotari miševi i miševi divljeg tipa žrtvovani su 13.5-og embrionalnog dana, te četvrtog i četrnaestog postnatalnog dana. Parafinski rezovi bubrežnog tkiva analizirani su imunofluorescencijom pomoću Greb11 protutijela. Bubrežne strukture ispitivane su fluorescencijskim mikroskopom. Postotak pozitivnih stanica između svake skupine uspoređen je i analiziran pomoću Kruskal-Wallis testa, a zatim t-testa.

**Rezultati:** U 14 dana starom bubregu u oba genotipa, DCT je bio struktura s najvećim postotkom Greb11 imunoreaktivnih stanica, posebno u yotari grupi ( $p < 0,01$ ). Najveći postotak pozitivne Greb11 ekspresije u 4 dana starom bubregu bila je u genotipu divljeg tipa za DCT i glomerul ( $p < 0,01$ ). Minimalna pozitivna ekspresija Greb11-a u 13.5 dana starom embrionalnom bubregu bila je u glomerulu u oba genotipa, bez statističke značajnosti. Greb11 ekspresija nije bila prisutna u PCT-u i DCT-u u ovoj fazi u oba genotipa.

**Zaključak:** Izražaj Greb11-a u nefronskim strukturama kod oba genotipa miševa implicira potencijalnu važnost Greb11-a u DCT-u u 14 dana starom bubregu, posebno u yotari miševima. Sveukupno, divlji tip u 4 dana starom bubregu pokazao je signifikantno veću ekspresiju Greb11-a u DCT-u i glomerulu, predlažući svoj potencijal u ovoj fazi razvoja bubrega. Na kraju, skoro nepostojeća Greb11 ekspresija bila je u svim strukturama u oba genotipa 13.5 dana starog embrionalnog bubrega, što implicira da je Greb11 ekspresija važnija u kasnijim fazama bubrežnog razvoja. Sveukupno, čini se da je bubrežni razvoj u yotari miševima kasniji od grupe divljeg tipa, što je moguće objašnjenje za nesložnost.

## **10. CURRICULUM VITAE**

Personal Data:

Name and Surname: Andrea Balić  
Date and place of birth: May 25th, 1996 in Zagreb, Croatia  
Citizenship: Croatian  
Address: Dvornikova 10, Radunica, 21000 Split  
E-mail: [abalic2505@gmail.com](mailto:abalic2505@gmail.com)

Education:

2015 - 2021 The University of Split School of Medicine  
2012 - 2015 American School of Macedonia, Skopje (North Macedonia)  
2011 - 2012 Gornjogradska Gymnasium, Zagreb  
2003 - 2011 Elementary School Tituš Brezovački, Zagreb

Other activities:

2020-2021: University of Split School of Medicine, Department of Clinical skills, Clinical skill demonstrator in course Clinical skills II to younger medical student generations.  
2019-2020 Assistant to Local Officer for Human Rights and Peace (LORP), CroMSIC Split, IFMSA, Split.  
2016-2020 Volunteered in public measurement of blood pressure and blood sugar through CroMSIC (Croatian Medical Student's International Committee) Split medical student organization, which is a part of IFMSA – International Federation of Medical Student's Associations.  
2016-2017: University of Split School of Medicine, Department of Anatomy, Anatomy demonstrator in Anatomy course to younger medical student generations.

Languages: Native- Croatian  
C1- English  
B2- German