

SUNCT syndrome in University hospital of Split

Kröger, Gabriella Maria

Master's thesis / Diplomski rad

2021

Degree Grantor / Ustanova koja je dodijelila akademski / stručni stupanj: **University of Split, School of Medicine / Sveučilište u Splitu, Medicinski fakultet**

Permanent link / Trajna poveznica: <https://um.nsk.hr/um:nbn:hr:171:781244>

Rights / Prava: [In copyright](#) / [Zaštićeno autorskim pravom.](#)

Download date / Datum preuzimanja: **2024-05-13**



Repository / Repozitorij:

[MEFST Repository](#)



UNIVERSITY OF SPLIT



**UNIVERSITY OF SPLIT
SCHOOL OF MEDICINE**

GABRIELLA KRÖGER

SUNCT SYNDROME IN UNIVERSITY HOSPITAL OF SPLIT

DIPLOMA THESIS

Academic year:

2020/2021

Mentor:

Prof. Marina Titlić, MD, PhD

Split, July 2021

Table of contents

1. INTRODUCTION.....	1
1.1 SUNCT.....	2
1.1.1 Trigeminal autonomic cephalalgias.....	2
1.1.2 Differences between SUNCT and SUNA.....	2
1.1.3 International Classification of Headache Disorders.....	3
1.1.4 Epidemiology.....	4
1.1.5 Signs and symptoms.....	4
1.1.6 Duration and frequency.....	4
1.1.7 Triggers.....	4
1.2 Diagnostics.....	5
1.2.1 Diagnostic criteria.....	5
1.2.2 Differential diagnosis.....	6
1.3 Pathophysiology.....	8
1.4 Treatment options.....	8
1.4.1 Pharmacological treatment.....	8
1.4.2 Surgical treatment.....	9
1.4.3 Alternative therapeutic options – case reports.....	10
2. OBJECTIVES.....	13
3. MATERIALS AND METHODS.....	15
4. RESULTS.....	17
5. DISCUSSION.....	24
6. CONCLUSION.....	27
7. REFERECNCES.....	29
8. SUMMARY.....	33
9. CROATIAN SUMMARY.....	35
10. CURRICULUM VITAE.....	37

*First of all I want to thank my mentor Prof. Marina Titlić for
her support and help in writing this diploma thesis.*

*Some special words of gratefulness to my friends in Split for everything
we shared during our studies in both hard times and happiness.*

*I also want to thank my parents and my sister for all
their love and endless support during these years.*

*Finally, I want to thank Stefan for being the best support I could ever have wished for.
Without you this would have been impossible.*

Abbreviations

SUNCT – Short-lasting unilateral neuralgiform headache with conjunctival injections and tearing

TCAs – Trigeminal autonomic cephalalgias

ICHD-3 – International Classification of Headache Disorders third edition

SUNHA – Short-lasting unilateral neuralgiform headache attacks

SUNA – Short-lasting unilateral neuralgiform headache with cranial autonomic symptoms

VRS – Verbal Rating Scale

ONS – Occipital nerve stimulation

MVD – Microvascular decompression

1. INTRODUCTION

1.1 SUNCT

SUNCT is a rare form of primary headache that was first described by Sjaastad et al. in 1978 (1). It is characterized by a short-lasting, unilateral neuralgiform headache occurring along with conjunctival injections and tearing (2). Primarily it is referred to as a form of primary headache, although secondary forms have been reported and linked to intracranial lesions of the pituitary gland and posterior fossa. Secondary forms have also been reported following viral meningitis, meningoencephalitis and traumatic head injuries (3,4).

1.1.1 Trigeminal autonomic cephalalgias

SUNCT belongs to the group of trigeminal autonomic cephalalgias (TACs), with cluster headache being the most common form of TAC (5). The hallmarks of these primary headaches are the characteristic and prominent ipsilateral parasympathetic autonomic symptoms (6). The autonomic symptoms mainly involve conjunctival injections, tearing, ptosis, nasal congestion and rhinorrhea (5). The pathophysiology of TACs is believed to be related to an abnormal activation of hypothalamus with resultant excessive activation of the trigeminal autonomic reflex (7).

1.1.2 Differences between SUNCT and SUNA

SUNCT and SUNA are very similar in their presentation with episodic and unilateral stabbing type of headache that occurs in association with autonomic symptoms (1). The main difference between the two is that SUNCT present with both tearing and conjunctival injection, while in SUNA there is either lacrimation or conjunctival injection and not both (5).

Both SUNA and SUNCT have three types of attacks; single stabs, groups of stabs or saw-tooth pattern stabs. Single stab type is most common in SUNCT, while groups of stabs are the most prevalent in SUNA (8).

In the third revision of the International Classification of Headache Disorders from 2013, SUNCT and SUNA are to be considered subtypes of short-lasting unilateral neuralgiform headache attacks (SUNHA) (6).

1.1.3 International Classification of Headache Disorders 3rd edition

Table 1. Classification of trigeminal autonomic cephalalgias according to ICHD-3

Classification of trigeminal autonomic cephalalgias (TACs):
1. Cluster headache
1.1 Episodic cluster headache
1.2 Chronic cluster headache
2. Paroxysmal hemicrania
2.1 Episodic paroxysmal hemicrania
2.2 Chronic paroxysmal hemicrania
3. Short-lasting unilateral neuralgiform headache attacks (SUNHA)
3.1 Short-lasting unilateral neuralgiform headache attacks with conjunctival injection and tearing (SUNCT)
3.1.1 Episodic SUNCT
3.1.2 Chronic SUNCT
3.2 Short-lasting unilateral neuralgiform headache attacks with cranial autonomic symptoms (SUNA)
3.2.1 Episodic SUNA
3.2.2 Chronic SUNA
4. Hemicrania continua
4.1 Hemicrania continua, remitting subtype
4.2 Hemicrania continua, unremitting subtype
5. Probable trigeminal autonomic cephalalgia
5.1 Probable cluster headache
5.2 Probable paroxysmal hemicrania
5.3 Probable short-lasting unilateral neuralgiform headache attacks
5.4 Probable hemicrania continua

1.1.4 Epidemiology

The incidence and prevalence of SUNCT is uncertain but it is considered to be one of the rarest types of headache (2). Due to challenges in diagnostics it has tended to go unrecognized in common neurological practice (1). An Australian study has estimated the prevalence of SUNCT to 6.6/100,000 and an incidence of 1.2/100 000 (2). Typical onset of SUNCT occurs in the 5th decade of life with 48 years being the mean age of onset. A male predominance is seen in SUNCT with a male to female ratio of 2:1 (9).

1.1.5 Signs and symptoms

SUNCT is featured by severe, unilateral headache in the orbital, periorbital or temporal area with autonomic symptoms involving conjunctival injections and tearing. The character of the pain is described as sharp, shooting or burning and rated 10/10 in severity on the VRS scale (2,9). Other symptoms may include rhinorrhea, nasal obstruction, sweating of the forehead, ipsilateral ptosis, ipsilateral eyelid edema and facial flushing (1,9). A majority of patients also report agitation during SUNCT attacks (9).

1.1.6 Duration, frequency and pattern

The duration of the attacks typically last between 1-600 seconds with an average of 10-60 seconds (2,9). Frequency of attacks varies greatly, from less than 1 per day up to 30 attacks per hour (10). The mean frequency of attacks was demonstrated to be 28 times per day in a systematic study (1). SUNCT may be classified as either episodic or chronic, with the former being characterized by pain-free periods of at least 1 month. The chronic form of SUNCT with attacks lasting for more than a year or with remission of less than 1 month, tend to be more prevalent (2).

SUNCT attacks may follow different patterns, for example the “saw-tooth” pattern, meaning that one attack occur after the other with no relief of pain in between. The other patterns are the so called “single stabs” and “grouped stabs” in which the pain subsides between each attack (5).

1.1.7 Triggers

The headache attacks seen in SUNCT can be either triggered or spontaneous while a mixture of spontaneous and triggered attacks is most common (10). Certain movements of the neck may precipitate an attack as well as cutaneous stimulation (1,2). The most common triggers are touch, chewing and eating as well as washing the face, brushing teeth and talking.

Some patients have reported precipitating factors such as viral infections, severe stress, withdrawal from analgesic medication and cabin pressure changes a few weeks before the attacks (9). No circadian periodicity has been linked to SUNCT (2).

1.2 Diagnostics

In common neurological practice SUNCT often goes unrecognized and the mean time of diagnosis is 6.7 years (1,2). Brain MRI is indicated in the workup of SUNCT due to the possible underlying structural abnormalities such as vascular compression and intracranial lesions (11). Blood tests to assess the pituitary function are also indicated due to the possible secondary cases caused pituitary gland lesions (2). However, neurological examinations tend to be normal and no specific abnormalities can be found in most patients (9).

1.2.1 Diagnostic criteria

Table 2. Diagnostic criteria of SUNCT

A. At least 20 attacks fulfilling criteria B-E
B. Moderate or severe unilateral head pain, with orbital, supraorbital or temporal and/or other trigeminal distribution, lasting for 1-600 seconds and occurring as single stabs, series of stabs or in a saw-tooth pattern
C. At least one of the following cranial autonomic symptoms or signs, ipsilateral to the pain
1. Conjunctival injections and/or lacrimation
2. Nasal congestion and/or rhinorrhea
3. Eyelid edema
4. Forehead and facial sweating
5. Forehead and facial flushing
6. Sensation of fullness in the ear
7. Miosis and/or ptosis
D. Attacks have a frequency of at least one a day for more than half of the time when the disorder is active
E. No better accounted for by another ICHD-3 diagnosis

1.2.2 Differential diagnosis

It may be difficult to differentiate SUNHA from trigeminal neuralgia as they share some common features, such as the short-lasting duration and the high frequency of attacks (12). In trigeminal neuralgia the site of pain is mainly located in the distribution of V2 and V3 branches of the trigeminal nerve, whereas in SUNHA the site of pain is typically located in the distribution of V1 and V2 branches.

Trigeminal neuralgia tends to present with few or no autonomic features, unlike SUNHA which involve prominent autonomic symptoms (2). Another distinction are the presence of refractory periods that are seen in trigeminal neuralgia but absent in SUNHA, meaning that a patient with SUNHA may experience an attack immediately after another (9) (table 3).

Specific features in duration and frequency of each TCA may help in making the diagnosis. Longer duration of headache attacks point toward cluster headache or paroxysmal hemicrania, with cluster headache typically lasting 15-180 minutes and paroxysmal hemicrania lasting 2-30 minutes. A continuous pattern of pain is more indicative of hemicrania continua. Both paroxysmal hemicrania and hemicrania continua share the so called “indomethacin effect”, referring to the complete resolution of symptoms following indomethacin administration (2,12) (Table 4).

Table 3. Differentiating features of SUNHA and trigeminal neuralgia (2):

Feature	SUNHA	Trigeminal neuralgia
Female:male	1:1.5	1:2
Site of pain	V1/V2 > V3	V2/V3 > V1
Severity of pain	Moderate to severe	Very severe
Duration	1-600 seconds	1-120 seconds
Autonomic features	Prominent	Sparse or none
Cutaneous triggers	Yes	Yes
Refractory period	Absent	Present

Table 4. Clinical features of TCAs (2):

Feature	SUNCT/SUNA	Cluster headache	Paroxysmal hemicrania	Hemicrania continua
Female:male	1:1.5	1.2:5-7	1:1	1.6:1
Type of pain	Sharp, shooting, burning	Stabbing, boring	Throbbing, stabbing, boring	Throbbing, ache, sharp, pressure
Severity	Severe	Severe	Moderate-severe	Moderate background with severe exacerbations
Duration	1-600 seconds	15-180 minutes	2-30 minutes	Continuous
Frequency	1-200 per day	1-8 per day	5-40 per day	Continuous
Circadian periodicity (%)	Absent	70	45	Absent
Autonomic features	Yes	Yes	Yes	Yes
Restlessness or agitation (%)	65	90	80	70
Triggers				
Alcohol	No	Yes	Occasional	No
Cutaneous	Yes	No	No	No
Indomethacin effect	No	No	Complete resolution	Complete resolution

1.3 Pathophysiology

Due to the prominent autonomic symptoms demonstrated in TACs, it has been proposed that the mechanism behind the syndrome may be a disinhibition of the trigeminal autonomic reflex (13). Activation of the posterior hypothalamus during SUNCT and SUNA attacks has been detected during functional neuroimaging studies and its role in trigeminovascular nociceptive and autonomic pathways may explain the symptoms (2,14,15). The overlapping symptoms seen in SUNCT and trigeminal neuralgia implicate that the two may share certain pathogenic mechanisms, such as vascular compression causing demyelination of the trigeminal sensory root.

The role of posterior fossa abnormalities, are important for the development of secondary forms of SUNCT (16,17). Cases reports of pituitary gland adenomas, post-traumatic head injuries and medullary infarction with subsequent development of SUNCT have been described (17,18).

1.4 Treatment options

SUNCT was previously regarded as treatment resistant but today there are different treatment options both in the acute setting and prophylactically (19). Due to the short-lasting duration of SUNCT the main focus of therapy is to prevent future attacks. Microvascular decompression (MVD) of the trigeminal nerve has been tried as a surgical approach for SUNCT since some patients have been found to have ipsilateral vascular loops in association with the trigeminal nerve (17,11). Another surgical option is occipital nerve stimulation (ONS), which also have showed beneficial results (20).

1.4.1 Pharmacological treatment

Two of the largest available studies regarding treatment of SUNCT and SUNA demonstrated that parenteral lidocaine appears to have the best evidence for short-term relief of SUNCT attacks with an effectiveness of 94-100% (8,19,21). Some evidence also suggests that the beneficial effects of lidocaine may last up to a few weeks. Consideration must however be taken to the potential adverse effects related to lidocaine which occurred in 54% of patients participating in the study. Adverse effects of lidocaine include psychiatric disturbances and cardiac arrhythmias. A 12-lead ECG and regular blood pressure controls during the entire treatment period is recommended (21). Sumatriptan, high-flow oxygen, indomethacin injections, dihydroergotamine and corticosteroids are often tried in the acute

setting due to their success in other primary headache types but seem to be of little or no value in both SUNCT and SUNA (21).

Lamotrigine, topiramate, gabapentin, verapamil and indomethacin are common pharmacological agents tried as prophylaxis in SUNCT, with lamotrigine showing favorable response compared to the other drugs (19,22). A cohort study consisting of 161 patients demonstrated that 56% of patients responded to lamotrigine (22). Lamotrigine seem to have an ability to reduce the frequency of headache attacks rather than suppressing them entirely. In dosage of 100-600 mg/day it has demonstrated to be effective in 62% of patients. In the same study topiramate and gabapentin showed a response rate of 48% respectively 38% (21). Neither verapamil, valproate, beta-blockers nor tricyclics have demonstrated any beneficial response rates in SUNCT (8).

1.4.2 Surgical treatment

Only a few clinical trials with a small amount of patients have been conducted regarding the surgical treatment options. However, bilateral occipital nerve stimulation (ONS) and microvascular decompression (MVD) of the trigeminal nerve are two methods that have demonstrated promising results in medically unresponsive SUNCT patients (11,20,23).

In a study involving six SUNCT patients and three SUNA patients who received occipital nerve stimulators, eight out of nine patients (89%) experienced significant improvement of their headaches, health-related quality of life, disability and affective score after the surgery. The patients could either stop or decrease their medications and results were sustained at the median 38 months follow-up (20).

In another study with SUNCT and SUNA patients resistant to standard medical therapy and with aberrant vascular loops in contact with or compressing the trigeminal nerve, complete cessation of symptoms was achieved in six out of nine patients (67%) after microvascular decompression of the trigeminal nerve (23). In a study involving two Japanese male patients with aberrant arterial loops of either superior cerebellar artery or vertebral artery, both patients experienced complete cessation of symptoms after MVD. Results were sustained at two years follow-up (24). Both studies suggest that the most common vascular abnormalities involve either the superior cerebellar artery, inferior cerebellar artery or the vertebral artery (20).

1.4.3. Alternative therapeutic options – case reports

Gamma-knife radiosurgery

Case report: A 50-year old male patient presented with unilateral episodic stabbing facial pain located in V1-V2 trigeminal nerve branch distribution. The patient was first diagnosed with trigeminal neuralgia and unsuccessfully treated with carbamazepine and pregabalin. Further diagnostic evaluation demonstrated associated lacrimation and conjunctival injection, which lead to the diagnosis of SUNCT and the patient was started on lamotrigine.

Due to side effects involving skin rash, lamotrigine was substituted for topiramate and gabapentin without success.

Surgical treatment was attempted as a last resort in which the trigeminal nerve and sphenopalatine ganglion was targeted with gamma-knife at a dose of 80 Gy. During the first day of surgery the patient became pain free. No spontaneous attacks but short attacks triggered by cutaneous stimulation of the periorbital region were noted at follow-up 4 months post-surgery.

Previous case reports in which two patients received gamma-knife radiosurgery targeting only the trigeminal nerve demonstrated unsuccessful results. However, targeting both trigeminal nerve and sphenopalatine ganglion appears to be important for a successful response (25).

Case report: A 63-year old woman presented with episodic paroxysmal pain in the distribution of V3 trigeminal nerve branch in association with lacrimation and conjunctival injection. She had unsuccessful responses with different pharmacological drug combinations and her quality of life was severely affected. Gamma-knife surgery with 80 Gy targeting the trigeminal nerve and sphenopalatine ganglion was attempted. The surgery was successful and the severity and frequency of attacks diminished gradually. The patient was almost pain free and could resume with her normal life at 37 months follow-up (26).

Case report: An 82-year old male patient presented with SUNCT syndrome intractable to medical therapy. Gamma-knife radiosurgery was attempted and a dose of 80 Gy was delivered to both the trigeminal nerve and the sphenopalatine ganglion. Two weeks after the surgery the patient was completely pain free. At 39-months follow-up the results were sustained (27).

Ketamine injection

Case: A 58-year old man presented with intense, stabbing and burning right-sided periorbital pain associated with lacrimation and redness of the eye. The attacks lasted around 30-40 seconds with spontaneous resolution. Prophylactic pharmacological therapy with lamotrigine, gabapentin, pregabalin, phenytoin and amitriptyline were all tried without success. The severity of the attacks increased and the patient had around 100 episodes per day. Subcutaneous sub-anesthetic ketamine infusions were attempted with gradual increase of ketamine up to 6 mg/hour. After three days the patient was completely pain free without any side effects. The ketamine infusions were continued for three more days and after that the patient received sublingual ketamine lozenges 25 mg three times daily. In addition to the ketamine lozenges, the patient was discharged with tapentadol SR 50 mg twice daily, pregabalin 150 mg twice daily, amitriptyline 10 mg for night, clonazepam 0.5 mg for night and lamotrigine 25 mg twice daily.

The patient's quality of life dramatically increased and he was able to go back to work and did not experience any more spontaneous SUNCT attacks. Lamotrigine, pregabalin, tapentadol, amitriptyline and clonazepam were all gradually stopped and 25 mg ketamine lozenge twice daily was sufficient for the patient to be pain free (28).

Zonisamide

Case: A patient presented with symptoms characteristic of SUNCT in which pharmacological drug therapy with carbamazepine (600 mg/day) was started. The drug was successful in eliminating the painful symptoms; however side effects in terms of severe rash occurred. Sodium-channel blocker zonisamide (300 mg/day) was initiated due to its lower risk of causing skin rash compared to carbamazepine.

Complete cessation of SUNCT attacks was accomplished with zonisamide blood serum levels of 19 microgram/ml and this case report is the first in which zonisamide was used to successfully treat SUNCT (29).

Botulinum toxin A

Case: A patient with a 20 year history of medically intractable SUNCT attacks. An attempt to infiltrating onabotulinum toxin A at four points throughout the orbit was made. Botulinum toxin caused a dramatic effect. Every three months infiltrations were made and at follow-up after 18 months the effectiveness was sustained. The patient experienced no side effects (30).

Case: A 12-year old boy presented with severe paroxysmal unilateral periorbital pain and left upper toothache that had lasted for 20 days. The pain was associated with ipsilateral lacrimation, redness of the eye, rhinorrhea and facial flushing. The patient experienced around 10 attacks per day that subsided spontaneously after approximately 60 seconds.

Carbamazepine (200 mg/three times daily) was initiated without successful response and side effects involving skin rash that lead to discontinuation of carbamazepine. A trial of various drug combinations including gabapentin, pregabalin, indomethacin, flunarizine, ibuprofen, topiramate, methylprednisolone, lidocaine as well as pure oxygen were tried without success.

Subcutaneous botulinum toxin A (100 U diluted in 2 ml 0.9% saline) was administered in the ipsilateral orbit, temporal area, cheek and gum. The pain gradually improved after four days and after seven days there was complete cessation of pain and the boy could be discharged. At 17 months follow-up the results were sustained. The authors suggest botulinum toxin A as a first-line option in children above the age of 12 years who experience a first episode of SUNCT (31).

2. OBJECTIVES

The aim of this study is to retrospectively examine the incidence of patients diagnosed with SUNCT syndrome in University Hospital of Split during the time period from the 1st of January 2010 until 31st of December 2019.

Hypothesis: based on previous studies that have examined the incidence and prevalence of SUNCT syndrome, the hypothesis is that this type of headache will be a rare occurrence in the patients included in this study.

3. MATERIALS AND METHODS

This is a retrospective study examining the incidence of patients diagnosed with SUNCT syndrome in the general surgery and neurology outpatient clinic in University Hospital of Split during the time period from the 1st of January 2010 until 31st of December 2019. The following parameters will be also examined:

- Average age of patients at time of diagnosis
- Gender distribution of the patients
- Distribution of chronic and episodic forms

Study population

Inclusion criteria: All patients who were examined for the first time in the general surgery and neurology outpatient clinic in University Hospital of Split during a ten year period were included in the analysis. Further selection of patients presenting with some form of headache was made.

Exclusion criteria: Patients who presented in the general surgery and neurology outpatient clinic for follow-up examinations were excluded from the study.

Place of the study

The research was conducted at the general surgery and neurology outpatient clinic in University Hospital of Split.

Data analysis and presentation

Medical history of the patients and data in this study was analyzed and presented by using Microsoft Excel version 2016 (Microsoft Excel Software, Redmond, Washington, USA) and Microsoft Word Processing Software 2016 (Microsoft Word Software, Redmond, Washington, USA).

4. RESULTS

During the time period from 1st of January 2010 until 31st of December 2019 on average 34 ± 2 patients per week were examined in the general surgery and neurology outpatient clinic in the University Hospital of Split. A total number of neurologic examinations were performed on $16\,320 \pm 13.8$ patients. Out of these patients, 7 344 (45%) were first-time visits and 8 976 (55%) were follow-up examinations, as presented in Figure 5.




Figure 5. Distribution of first-time visits and follow-up examinations.

A majority of the patients who were examined for the first time experienced painful symptoms dominated by lumboischialgia (46%), headache (37%) and other symptoms (17%), as presented in Figure 6.

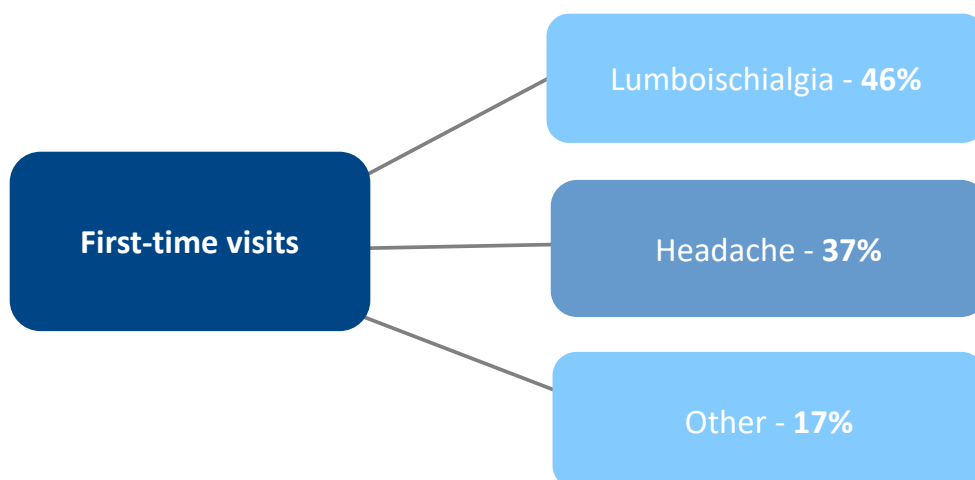


Figure 6. First-time visits referrals for neurological examinations.

From the total number of patients who were examined in the general surgery and neurology outpatient clinic for the first time, 2 717±9 (37%) patients experienced some form of headache. The patients with headache were classified according to the International Classification of Headache Disorders (ICHD) into two groups: primary or secondary headaches.

In all patients that were examined for headache, 2 255 (83%) patients had primary headache and 299 (11%) patients were classified as having secondary headache. In 163 (6%) patients the pain was located in the head and/or neck regions and was categorised as neuralgia.

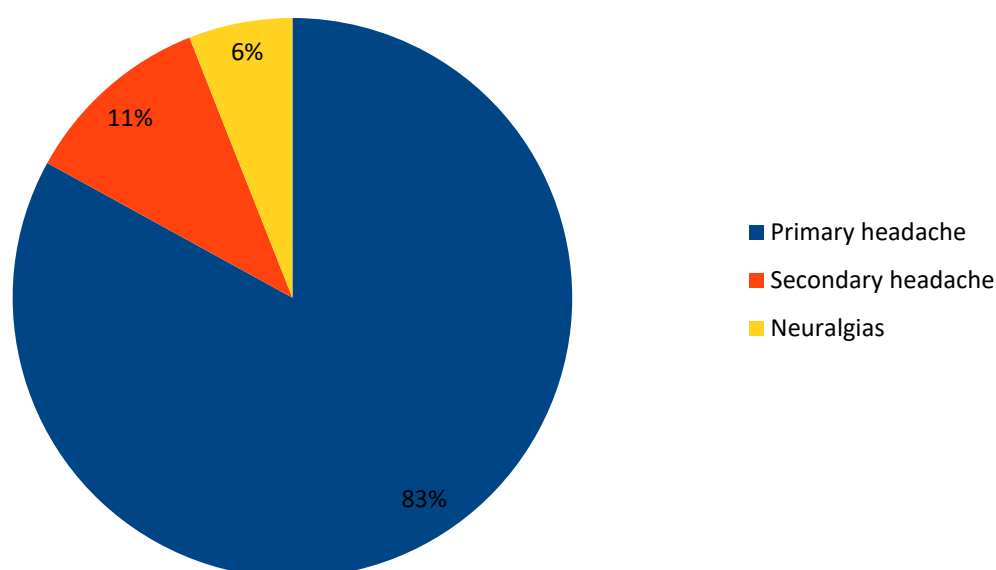


Figure 7. Distribution of headache forms.

According to the International Classification of Headache Disorders (ICHD), the primary headaches types include: migraine, tension-type headache (TTH), trigeminal autonomic headache (TACs) and other primary headache disorders, as presented in Table 8.

Table 8. Primary headache forms according to ICHD-3

Primary headaches
Migraine
Tension-type headache (TTH)
Trigeminal autonomic cephalalgias (TACs)
Other primary headache disorders

The total number of patients with primary headaches was dominated by tension-type headache (TTH), which occurred in 1 145 (51.2%) patients. Migraine was the second most common primary headache and present in 908 (40.3%) patients. Trigeminal autonomic headache was present in 179 (7.9%) patients. Other primary form of headaches was found in 14 (0.6%) patients.

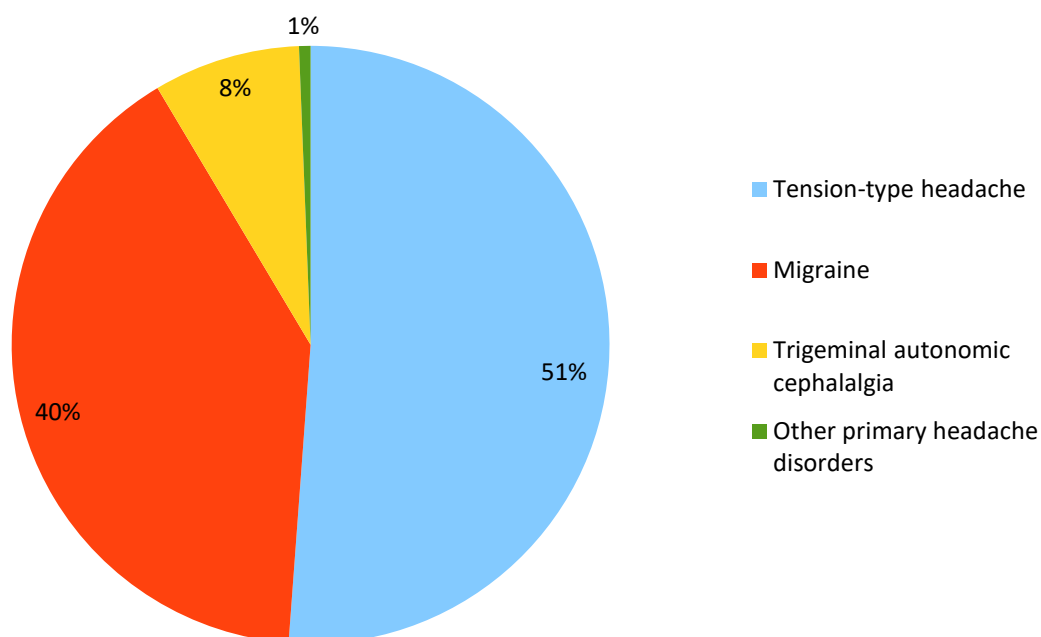


Figure 9. Distribution of primary headache forms.

Over the ten year period there were 179 (7.94%) patients presenting with trigeminal headaches in the general surgery and neurology outpatient clinic. According to the 2018 International Classification of Headache Disorders (ICHD), trigeminal neuralgias are subdivided into: cluster headaches, paroxysmal headaches, hemicrania continua, probable autonomic trigeminal headache and short-lasting unilateral neuralgiform headache attacks (SUNHA) (Table 10).

Short-lasting unilateral neuralgiform headache attacks (SUNHA) is a headache form featured by conjunctival injections and tearing (SUNCT) or with cranial autonomic symptoms (SUNA). SUNHA may be either episodic or chronic.

Table 10. Trigeminal autonomic headache subtypes

Trigeminal autonomic headache	Subtype
Cluster headache	episodic chronic
Paroxysmal headache	episodic chronic
Short-lasting unilateral headache attacks (SUNHA)	with conjunctival injection and tearing (SUNCT) episodic SUNCT chronic SUNCT with cranial autonomic symptoms (SUNA) episodic SUNA chronic SUNA
Hemicrania continua	of remitting type of chronic type
Probable trigeminal autonomic headache	probable cluster headache probable paroxysmal hemicrania probable short-lasting unilateral headache attack probable hemicrania continua

Out of the 179 patients presenting with trigeminal headaches, clinical treatment and neuroradiological diagnostics established cluster headache in 68 (38%) patients, paroxysmal headache in 57 (31.84%) patients, hemicrania continua in 32 (17.8%) patients and probable trigeminal autonomic headache in 3 (1.67%) patients. The diagnosis of short-lasting unilateral headache attacks (SUNHA) was in total established in 19 (10.61%) patients.

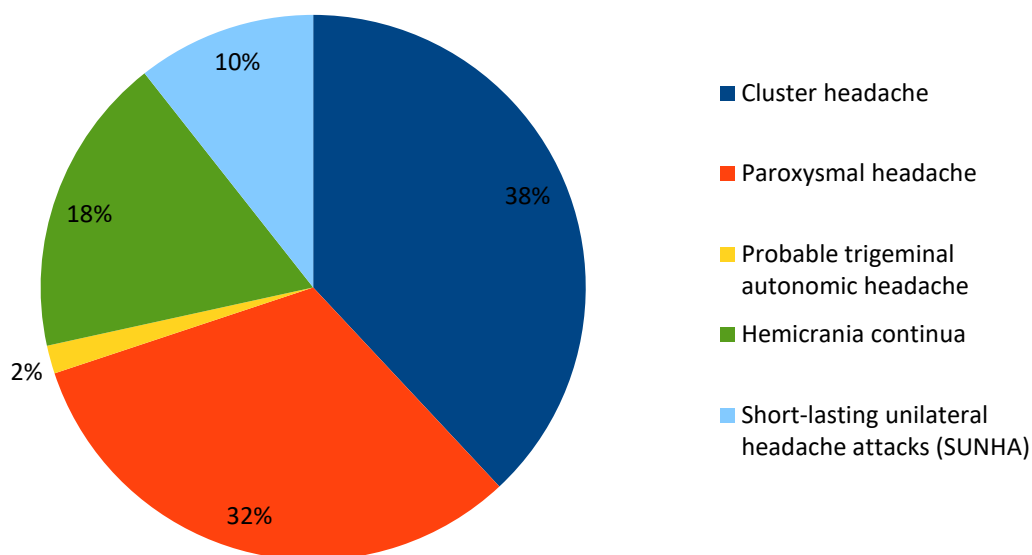


Figure 11. Distribution trigeminal headache subtypes.

In this group another distinction regarding SUNCT and SUNA was made, demonstrating that 11 (57.9%) patients had conjunctival injections characteristic of SUNCT and 8 (42.1%) patients had headache with cranial autonomic symptoms characteristic of SUNA.

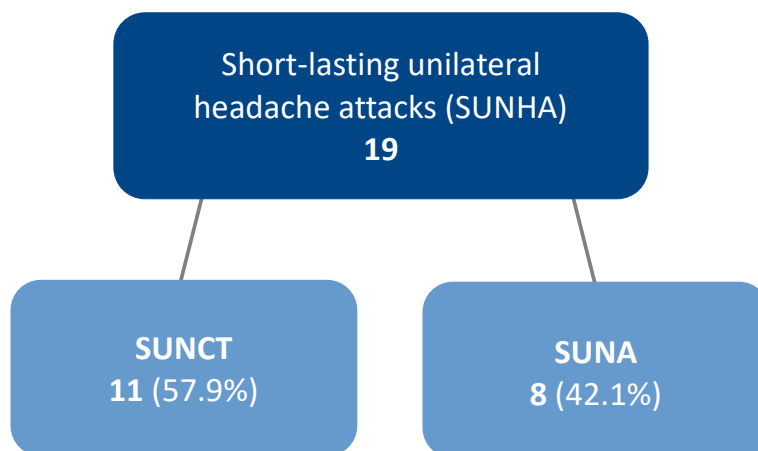


Figure 12. Prevalence of SUNCT and SUNA.

Among the 11 patients that were diagnosed with SUNCT headache, there was a gender distribution of eight men and three women. The average age of the patients was 43.42 ± 2.3 years. Three of the male patients experienced the chronic form of SUNCT, while the remaining five patients experienced episodic attacks.

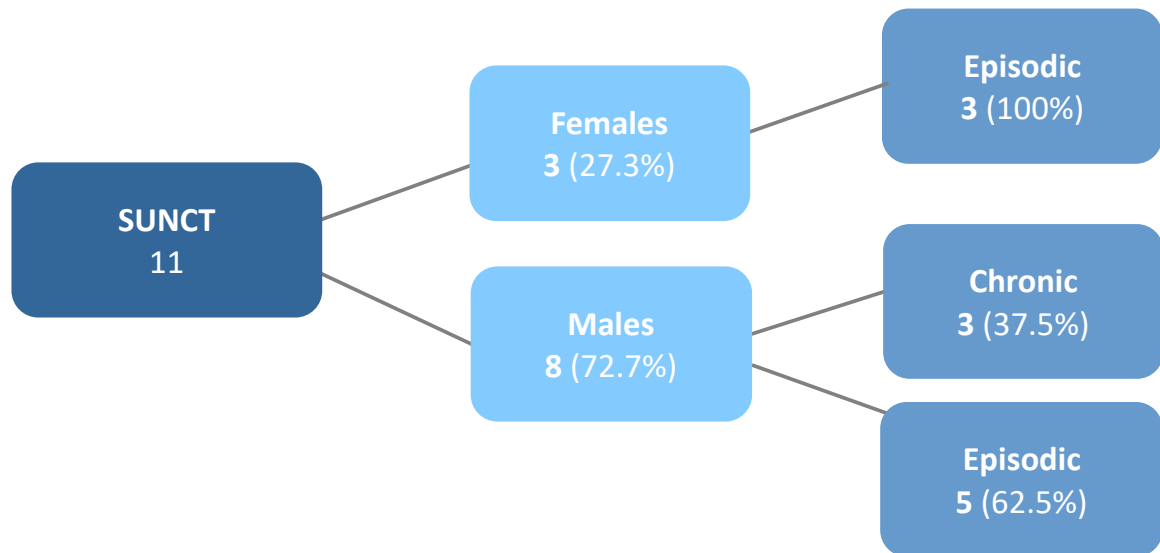


Figure 13. Gender distribution and episodic vs. chronic pattern among SUNCT patients.

5. DISCUSSION

SUNCT syndrome is one of the rarest forms of primary headaches, which probably contributes to the uncertainty of its prevalence and incidence, as well as the diagnostic challenges associated with the diagnosis (2).

During a ten year period, a total of 19 patients were diagnosed with SUNHA in the general surgery and neurology outpatient clinic in the University Hospital of Split. From these 19 patients, further subdivision revealed 11 patients with symptoms characteristic of SUNCT and eight patients with symptoms characteristic of SUNA. According to the latest version of the International Classification of Headache Disorders third edition (ICHD-3), SUNCT and SUNA are to be regarded as subcategories of SUNHA as their symptoms in many ways overlap (6).

In the ten year period, a total of 16 320 patients were examined in the general surgery and neurology outpatient clinic. 2 717 patients were diagnosed with some form of headache, in which primary headache was found to be most common (83%), followed by secondary headache (11%) and neuralgias (6%).

Cluster headache (38%) and paroxysmal headache (32%) were the two most common forms of trigeminal autonomic headaches. 11% of the trigeminal autonomic headaches were attributable to SUNHA. SUNCT appeared to be more common (57.9%) compared to SUNA (41.2%), which corresponds to previous study findings.

Other studies have demonstrated that SUNCT syndrome typically has an onset during the 5th decade of life with 48 years being the mean age of onset (9). The mean age of our patients with SUNHA was 43.42 ± 2.3 years. A male predominance has previously been reported in other studies and it was also confirmed in this patient group, with a male to female ratio of 1:2.7 (9).

Further division of SUNCT regarding its episodic or chronic pattern was also made. The episodic form of SUNCT is characterized by pain-free periods of at least one month, while the chronic form is categorized by attacks lasting for more than a year or with remission of less than one month. Some studies have found evidence that the chronic form of SUNCT is more common. However in our patient group, the episodic form was more common. All the patients with the chronic form were males and represented in total five patients. The episodic form was present in all three females and in three of the male patients.

Trigeminal neuralgia share many similarities with SUNHA with the main difference that there is an absence of autonomic symptoms in trigeminal neuralgia (2,12). Pathophysiological similarities that involve trigeminal vascular compression are however seen in both trigeminal neuralgias and SUNHA, suggesting that the two may be regarded as

diseases on the same spectrum (7,13).

SUNCT could also be misdiagnosed as cluster headache, a headache form that also present with daily attacks, male predominance, lacrimation, nasal congestion, rhinorrhea, periorbital unilateral headache and swelling around the eye. The main difference is the longer frequency of attacks in cluster headache where attacks typically lasts for 15-180 minutes, compared to SUNCT and SUNA where attacks tend to lasts 1-600 seconds. The frequency of SUNCT and SUNA attacks also tend to be higher, with up to 200 attacks per day. In cluster headaches attacks usually do not exceed eight per day (10).

There are also similarities between SUNHA and paroxysmal hemicrania and hemicrania continua. A distinction can be made by the fact that the two later forms shows complete resolution in response to indomethacin, the so called “indomethacin effect” (2,12).

Future studies could go deeper into individual treatment and treatment outcomes of the SUNCT patients, since currently there is no established guidelines regarding the treatment. Current evidence points toward that the antiepileptic drug lamotrigine is the most favorable prophylactic choice with response rates in approximately 60% of patients (19,21,22). Parenteral lidocaine appears to be the best choice in the acute setting with response rates of up to 100% (8,19,21). Many patients with SUNCT are still not achieving proper pain reduction and in these cases surgical treatment could be a potential option. Most studies of surgical interventions involve only a few patients but beneficial responses have been demonstrated with microvascular decompression (MVD) and occipital nerve stimulation (ONS), particularly in the medically intractable cases of SUNCT (11,20,23).

Limitations to this study are likely related to the challenges associated with diagnosing SUNCT. The rarity of the disorder as well as limited knowledge among general physicians regarding SUNCT may lead to lower detection of cases. Another problem is the difficulties in differentiating SUNCT from other trigeminal autonomic cephalalgias as well as trigeminal neuralgia due to their similar and overlapping symptoms.

6. CONCLUSION

- A total of 19 patients were diagnosed with short-lasting unilateral neuralgiform headache attacks (SUNHA) during a ten year period in University Hospital of Split.
- Further subdivision revealed 11 cases of SUNCT and eight cases of SUNA.
- Gender distribution among SUNCT patients demonstrated eight males and three females with a male to female ratio of 1:2.7.
- The episodic form of SUNCT was most common in this patient group and occurred in all three females and in five of the male patients, while the chronic form of SUNCT was present in three of the male patients.
- The mean age of the patients was 43.42 ± 2.3 years.

7. REFERENCES

1. Goadsby PJ, Lipton RB. A review of paroxysmal hemicranias, SUNCT syndrome and other short-lasting headaches with autonomic feature, including new cases. *Brain*. 1997;1:193-209.
2. Levy A, Matharu M. Short-lasting Unilateral neuralgiform Headache Attacks. *Ann Indian Acad Neurol*. 2018;5:31-8.
3. Eguia P, Garcia-Monco JC, Ruiz-Lavilla N, Diaz-Konrad V, Monton F. SUNCT and trigeminal neuralgia attributed to meningoencephalitis. *J Headache Pain*. 2008;9:51-3.
4. Ito Y et al. Secondary SUNCT syndrome caused by viral meningitis. *J Neurol*. 2009;4:667-68.
5. Cohen A. Trigeminal Autonomic Cephalalgias – A Diagnostic and Therapeutic Overview. *ACNR*. 2014;4:12-5.
6. Ichd-3.org [Internet]. The International Classification of Headache Disorders 3rd edition [cited 2021 February 2]. Available from: <https://ichd-3.org/3-trigeminal-autonomic-cephalalgias/>.
7. Goadsby P J. Trigeminal autonomic cephalalgias: fancy term or constructive change to the IHS classification? *J Neurol Neurosurg Psychiatry*. 2005;76:301-05.
8. Weng H-Y, Cohen A, Schankin C, Goadsby P J. Phenotypic and treatment outcome data on SUNCT and SUNA, including a randomised placebo-controlled trial. *Cephalalgia*. 2018;9:1554-63.
9. Cohen A, Matharu M, Goadsby P J Short-lasting unilateral attacks with conjunctival injection and tearing (SUNCT) or cranial autonomic features (SUNA) – a prospective clinical study of SUNCT and SUNA. *Brain*. 2006;10:2746-60.
10. Pareja J, Caminero A, Sjaastad O. SUNCT Syndrome: diagnosis and treatment. *CNS Drugs*. 2002;6:373-83.
11. Hassan S, Lagrata S, Levy A, Matharu M, Zrinzo L. Microvascular decompression or neuromodulation in patients with SUNCT and trigeminal neurovascular conflict? *Cephalalgia*. 2018;2:393-98.
12. Cohen A. Short-lasting unilateral neuralgiform headache attacks with conjunctival injection and tearing. *Cephalalgia*. 2007;7:824-32.
13. Lambru G, Matharu M. Trigeminal autonomic cephalalgias: A review of recent diagnostic, therapeutic and pathophysiological developments. *Ann Indian Acad Neurol*. 2012;1:51-61.
14. Arca K, Singh Halker R. SUNCT and SUNA: an Update and Review. *Curr Pain Headache Rep*. 2018;8:56.

15. Khalili Al Y, Veerapaneni KD. Short Lasting Unilateral Neuralgiform Headache. [Updated 2020 Jun 13]. In: StatPearls [Internet]. Treasure Island (FL): StatPearls Publishing; 2021 Jan. Available from <https://www.ncbi.nlm.nih.gov/books/NBK559088/>
16. Lei Q et al. Comorbid SUNCT syndrome and Opalski Syndrome Caused by Dorsolateral Medullary Infarction. *Front Neurol*. 2020;11:52.
17. Paliwal V, Singh P, Kumar A, Rahi S, Gupta R. Short-lasting unilateral neuralgiform headache with conjunctival injection and tearing (SUNCT) with preserved refractory period: report of three cases. *J Headache Pain*. 2021;2:167-69.
18. Lambru G, Trimboli M, Tan Veronica S, Al-Kaisy A. Medullary infarction causing coexistent SUNCT and trigeminal neuralgia. *Cephalalgia*. 2017;5:486-90.
19. Lambru G, Matharu M. SUNCT and SUNA: medical and surgical treatments. *Neurol Sci*. 2013;34:75-81.
20. Lambru G, Shanahan P, Watkins L, Matharu M. Occipital nerve stimulation in the treatment of medically intractable SUNCT and SUNA. *Pain Physician*. 2014;1:29-41.
21. Baraldi C, Pellesi L, Guerzoni S, Cainazzo M, Pini L. Therapeutical approaches to paroxysmal hemicrania, hemicrania continua and short lasting unilateral neuralgiform headache attacks: a critical appraisal. *J Headache Pain*. 2017;1:71.
22. Lambru G et al. Medical treatment of SUNCT and SUNA: a prospective open-label study including a single-arm meta-analysis. *J Neurol Neurosurg Psychiatry*. 2021;92:233-41.
23. Williams M, Bazina R, Tan L, Rice H, Broadly S. Microvascular decompression of the trigeminal nerve in the treatment of SUNCT and SUNA. *J Neurol Neurosurg Psychiatry*. 2010;9:992-96.
24. Kitahara I, Fukada A, Imamura Y, Ikawa M, Yokochi T. Pathogenesis, Surgical Treatment, and Cure for SUNCT syndrome. *World Neurosurg*. 2015;4:1080-83.
25. Mathew T et al. SUNCT syndrome treated with gamma knife targeting the trigeminal nerve and sphenopalatine ganglion. *J Headache Pain*. 2012;6:491-92.
26. Zaed I et al. Gamma Knife Radiosurgery for Short Unilateral Neuralgiform Headache Attacks with Conjunctival Injection and Tearing (SUNCT) Syndrome: Targeting the Trigeminal Nerve and the Sphenopalatine Ganglion. Case report and Literature Review. *World Neurosurg*. 2020;133:167-71.
27. Effendi K, Jarjoura S, Mathieu D. SUNCT syndrome successfully treated by gamma knife radiosurgery: case report. *Cephalalgia*. 2011;31:870-73.

28. Aggarwal A. Ketamine as a potential option in the treatment of short-lasting unilateral neuralgiform headache attacks with conjunctival injection and tearing. *Natl Med J India*. 2019;2:86-7.
29. Ikawa M, Imai N, Manaka S. A case of SUNCT syndrome responsive to zonisamide. *Cephalalgia*. 2011;4:501-03.
30. Zabalza J R. Sustained response to botulinum toxin in SUNCT syndrome. *Cephalalgia*. 2012;11:869-72.
31. Zhang Y et al. Botulinum Toxin A for the Treatment of a Child with SUNCT syndrome. *Pain Res Manag*. 2016. doi: 10.1155/2016/8016065.

8. SUMMARY

Objectives: The aim of this study was to retrospectively examine the incidence of patients diagnosed with SUNCT syndrome in University Hospital of Split during a ten year period.

Materials and methods: This work was organized as retrospective analysis of data from the 1st of January 2010 until 31st of December 2019 involving all patients who underwent first-time examination in the general surgery and neurology outpatient clinic. The patients were subdivided according to their main complaint which involved three major groups; lumboischialgia, headache and other symptoms with further division into primary or secondary headache forms.

Results: On average, 34 patients per week were examined in the general surgery and neurology outpatient clinic, with the total number of examinations being 16 320. 8 976 (55%) of the examinations represented follow-up examinations and 7 344 (45%) represented first-time visits. First-time visits complaints were dominated by lumboischialgia (46%), headaches (37%) and other symptoms (17%).

2 717 (37%) patients experienced some form of headache, which was further classified as either primary or secondary headache. A majority of these patients (83%) experienced primary headache. Tension-type headache (TTH) was the most common primary headache (51.2%) followed by migraine (40.3%), trigeminal autonomic cephalalgia (7.9%) and other primary headache disorders (0.6%).

A total of 179 (7.94%) patients experienced trigeminal autonomic cephalalgia, out of which 19 patients were classified as having short-lasting unilateral neuralgiform headache attacks (SUNHA). Further subdivision revealed 11 patients with symptoms characteristic of SUNCT and eight patients with symptoms characteristic of SUNA.

Out of the 11 patients diagnosed with SUNCT there were eight males and three females. All females experienced the episodic form of SUNCT. Five of the males experienced the chronic form of SUNCT and three experienced the episodic form. The mean age of the patients was 43.42 ± 2.3 years.

Conclusion: This study concluded that SUNCT is a very rare form of primary headache with a total of 11 patients diagnosed during a ten year period in University Hospital of Split.

9. CROATIAN SUMMARY

Ciljevi: Cilj ovog istraživanja bio je retrospektivno ispitati učestalost pacijenata sa dijagnozom SUNCT sindroma u Sveučilišnoj bolnici u Splitu tijekom desetogodišnjeg perioda.

Materijali i metode: Ovaj rad je organiziran kao retrospektivna analiza podataka od 1. siječnja 2010. do 31. prosinca 2019. uključujući sve pacijente koji su prvi put pregledani u ambulantu za opću kirurgiju i neurologiju. Pacijenti su podijeljeni prema glavnoj pritužbi koja je uključivala tri glavne skupine; lumboishialgija, glavobolja i drugi simptomi s daljnom podjelom na primarne ili sekundarne oblike glavobolje.

Rezultati: 34 pacijenata tjedno je u prosjeku pregledano u ambulantu za opću kirurgiju i neurologiju, s ukupnim brojem pregleda 16 320. 8 976 (55%) pregleda uključivalo je naknadne preglede i 7 344 (45%) predstavljali su prve posjete. U pritužbama prvih posjeta dominirali su lumboishialgija (46%), glavobolja (37%) i drugi simptomi (17%).

2 717 (37%) pacijenata imalo je neki oblik glavobolje, koja je potom klasificirana kao primarna ili sekundarna glavobolja. Većina ovih pacijenata (83%) imala je primarnu glavobolju. Tenzijska glavobolja (TTH) bila je najčešća primarna glavobolja (51.2%), a slijedila je migrena (40.3%), trigeminalna autonomna cefalalgija (7.9%) i ostali primarni poremećaji glavobolje (0.6%).

Ukupno je 179 (7.94%) pacijenata doživjelo trigeminalnu autonomnu cefalalgiju, od kojih su 19 pacijenata klasificirani kao kratkotrajni jednostrani neuralgiformni napadi glavobolje (SUNHA).

Daljna podjela otkrila je 11 pacijenata sa simptomima karakterističnim za SUNCT i 8 pacijenata sa simptomima karakterističnim za SUNA.

Od 11 pacijenata kojima je dijagnosticiran SUNCT bilo je osam muškaraca i tri žene. Sve su žene doživjele epizodni oblik SUNCT-a. Pet muškaraca doživjelo je kronični oblik SUNCT-a, a troje epizodni oblik. Prosječna dob pacijenata bila je 43.42 ± 2.3 godine.

Zaključak: Ovo istraživanje zaključilo je da je SUNCT vrlo rijedak oblik primarne glavobolje s ukupno 11 dijagnosticiranih pacijenata tijekom perioda od deset godina u Sveučilišnoj bolnici u Splitu.

10. CURRICULUM VITAE

Personal data:

Name and surname: Gabriella Maria Kröger

Date and place of birth: 13.01.1993, Hasslöv, Sweden

Citizenship: Swedish

E-mail: kroger.gaby@gmail.com

Education:

2014 – 2021: Medical studies, University of Split School of Medicine, Split, Croatia

Jan 2018 – Apr 2018: Gerontology, Jönköping University, Jönköping

Jan 2014 – May 2014: Pre-medical school, MD International Studies, Stockholm

Sep 2013 – Feb 2013: Chemistry and Biology, Miroi education, Laholm

2009 – 2012: High school diploma, Växjö Fria Gymnasium, Växjö

Knowledge and skills:

Aug 2018 – Sep 2018: Assistant nurse, retirement home, Sweden, Båstad

Jun 2017 – Sep 2017: Assistant nurse, retirement home, Sweden, Båstad

Oct 2013 – Jan 2014: Assistant nurse, retirement home, Sweden, Laholm

Summers 2010 – 2014: Assistant nurse, retirement home, Sweden, Laholm