

# Oral eplerenone for the management of acute serous chorioretinopathy (CSCR)

---

**Grimes, Rebecca Louise**

**Master's thesis / Diplomski rad**

**2017**

*Degree Grantor / Ustanova koja je dodijelila akademski / stručni stupanj:* **University of Split, School of Medicine / Sveučilište u Splitu, Medicinski fakultet**

*Permanent link / Trajna poveznica:* <https://urn.nsk.hr/urn:nbn:hr:171:468184>

*Rights / Prava:* [In copyright](#) / [Zaštićeno autorskim pravom.](#)

*Download date / Datum preuzimanja:* **2024-04-24**



*Repository / Repozitorij:*

[MEFST Repository](#)



UNIVERSITY OF SPLIT



**UNIVERSITY OF SPLIT  
SCHOOL OF MEDICINE**

**Rebecca Grimes**

**ORAL EPLERENONE FOR THE MANAGEMENT OF ACUTE SEROUS  
CHORIORETINOPATHY**

**Diploma thesis**

**Academic year:**

**2016/2017**

**Mentor:**

**Assist. Prof. Ljubo Znaor, MD, PhD**

**Split, June 2017.**

**UNIVERSITY OF SPLIT  
SCHOOL OF MEDICINE**

**Rebecca Grimes**

**ORAL EPLERENONE FOR THE MANAGEMENT OF ACUTE SEROUS  
CHORIORETINOPATHY**

**Diploma thesis**

**Academic year:**

**2016/2017**

**Mentor:**

**Assist. Prof. Ljubo Znaor, MD, PhD**

**Split, June 2017.**

## TABLE OF CONTENTS:

1. INTRODUCTION.....	1
1.1. Etiology.....	2
1.2. Epidemiology.....	3
1.3. Pathogenesis.....	3
1.4. Natural history.....	4
1.5. Clinical manifestations.....	4
1.6. Classification.....	5
1.7. Acute central serous chorioretinopathy (CSCR).....	5
1.8. Chronic central serous chorioretinopathy (CSCR) .....	5
1.9. Risk Factors.....	6
1.10. Diagnostic methods.....	6
1.10.1. Spectral domain optical coherence tomography device (SD-OCT).....	6
1.10.2. Pattern electroretinogram (PERG).....	7
1.10.3. Multifocal electroretinopathy (mfERG).....	8
1.10.4. Fundus autofluorescence (FAF).....	8
1.11. Treatment modalities.....	9
1.11.1. Anti-VEGF agents.....	9
1.11.2. Photodynamic therapy (PDT).....	10
1.11.3. Focal laser coagulation (FLC).....	10
1.12. Prognosis.....	11
1.13. Eplerenone.....	11
1.13.1. Definition.....	11
1.13.2. Mechanism of action.....	11
1.13.3. Drug interactions.....	12
1.13.4. Eplerenone use in CSCR treatment.....	12
1.13.5. Eplerenone side effects.....	14
2. OBJECTIVES.....	16
3. MATERIALS AND METHODS.....	18
3.1. Ethical background of data collection.....	19
3.2. Study purpose.....	19
3.3. Subjects.....	19

3.4. Methods.....	20
3.5. Statistical methods.....	21
3.6. Imaging protocol.....	22
4. RESULTS.....	24
4.1. Baseline characteristics.....	25
4.2. Study outcomes.....	25
4.2.1. First follow up.....	25
4.2.2. Second follow up.....	25
4.2.3. Third follow up.....	26
4.2.4. Summary of study outcomes.....	26
4.3. Safety analysis.....	31
5. DISCUSSION.....	32
6. CONCLUSIONS.....	36
7. REFERENCES.....	38
8. SUMMARY.....	50
9. CROATIAN SUMMARY.....	52
10. CURRICULUM VITAE.....	54

*To my thesis supervisor, Assist. Prof. Ljubo Znaor for his consistent positive support and mentorship, as well as to Dr. Batistic, for his collegiality.*

*To my friends, my heartfelt appreciation for their continued encouragement, and above all camaraderie.*

*To my sister and all my family, my profound gratitude, for their relentless and unparalleled love and support.*

*To my late grandmother, who always had great faith in me.*

*Finally, to my parents, to whom I am forever indebted, for providing me with the opportunities and experiences that have made me who I am. They selflessly encouraged me to explore new directions in life, and to seek my own path. This journey would not have been possible if not for them, and I dedicate this milestone to them.*

## **1. INTRODUCTION**

## 1.1. Etiology

Central serous retinopathy (CSR) also known as Central serous chorioretinopathy (CSC or CSCR) (1,2) is an ocular, chorioretinal condition (3,4) characterised by serous retinal detachment with or without accompanying retinal pigment epithelial (RPE) detachment. This results in fluid seeping through the RPE into the subretinal space beneath (5) accumulating as serous subretinal fluid (SRF) (6).

CSCR has a multifactorial aetiology, and a complex pathogenesis which is not fully understood (7,8). Gass (9) denotes that the disease may begin in the choroidal blood vessels (7), also known as the choriocapillaris (6). The choriocapillaris is a layer of capillaries within the choroid (10). The choroid can generally be subdivided into four layers, one of which is the choriocapillaris (11). Enhanced depth imaging optical coherence tomography (EDI-OCT) findings in CSCR patients (12,13) support this theory by demonstrating diffuse choroidal thickening which exerts vascular stress on the RPE (14). Studies with indocyanine green (ICG) angiography show subretinal leakage of the dye representing choroidal vascular hyperpermeability, (2,15,16) and support the concept that both the choroidal hyperpermeability, and serous detachment, lead to a mechanical flaw in the RPE and consequential detachment of the neurosensory retina (6). Fluorescein fundus studies (9) further support this theory suggesting that increased choroid permeability leads to focal or diffuse dysfunction of the RPE (17).

Fluid seepage is commonest in the macula area resulting in serous SRF accumulation (6) and subsequent localised detachment of the neurosensory retina (18). Fluid leakage occurs beneath the retina and consequently accumulates, it is this accumulation that is responsible for causing visual impairment in the form of metamorphopsia (blurred vision), which is a frequent complaint amongst patients (19).

Furthermore, it has been suggested that excessive glucocorticoid-dependent choroid mineralocorticoid receptor (MR) activation in choroidal vessels, may play a role in CSCR pathogenesis (20-23). This concept is supported by the fact that CSCR is heightened by both endogenous and exogenous glucocorticoids (20,21,24).

Zhao *et al* (20) findings based on rodent studies have demonstrated the changes in choroidal vessels induced by high dose glucocorticoids causing them to both dilate and leak (20,21). MR's are located in neuroretina (21,25), which indicates that the activation of MR promotes both retinal neovascularization and inflammation (7,8).



## 1.2. Epidemiology

Demographically, CSCR affects 1 in 10,000 people (14) and is predominantly a disease of young men, aged between 20-50yrs, without any concomitant disease (5,7,26). Spaide *et al* (27), observed men with a mean age of 51yrs and concluded that older patients had diffuse RPE loss, indicating prior disease onset to be initially asymptomatic (27), similarly Haimovici *et al* (28) and Kitzmann *et al* (29) observed patients with 45 and 41 years as the mean age respectively, supporting previous evidence that CSCR affects mainly young to middle aged men. Males are more commonly affected compared to females (30,31), with CSCR reported to be more frequent amongst the Caucasian population (32), although this can be refuted by one study which concluded that the rate of symptomatic CSCR is comparable in Caucasians and African-Americans (33).

## 1.3. Pathogenesis

CSCR pathogenesis is multifaceted and not fully understood, however most theories emphasise choroid, and the role it plays in CSCR development. EDI-OCT images demonstrate diffuse choroidal thickening leading to choroidal vascular stress and hyperpermeability (14). ICG angiography demonstrates choroidal hyperpermeability (16,34), whose role is additionally supported by EDI-OCT which typically visualises a thickened choroid in CSCR patients (35). Abnormal capillary permeability, low intraocular pressure and high interstitial pressure in the choriocapillaris, promote retina pigment epithelial detachments (PEDs) which leads to SRF accumulation between the retina and RPE, because the RPE no longer provides a sufficient barrier (5).

RPE dysfunction also plays a substantial role in CSCR pathogenesis, although it remains poorly understood. Diffuse retinal pigment epitheliopathy (DRPE), is evident on clinical exam and fundus autofluorescence (FAF) (17). RPE's role as a barrier is overwhelmed due to the increased tissue hydrostatic pressure (6) and the choroid engorged, resulting in SRF accumulation. There are distinct focal areas of RPE leakage, that are now characteristic of CSCR disease (36).

Neurosensory retinal detachment could be due to ischemia (37), the CSCR monkey model (38) and perfusion delays in leakage sites shown in ICG angiography suggest that choroidal ischemia contributes to damaging the RPE (5). Prunte *et al* (39), concluded that ischemia is the reason for the choroidal arterial filling delay and the subsequent hyperperfusion by distended capillaries and venules (39).

It can also be argued that RPE incompetence is due to an inflammatory cause (40), based on MR. MR are not only found in the neuroretina (21,22), but are present throughout the body, namely in the endothelial cells, kidney and vascular smooth muscle (41). Excessive MR activation can stimulate vascular oxidative stress whilst inhibiting vascular relaxation. Consequently, it can contribute to vessel inflammation, fibrosis and remodelling, all precursors of cardiac disease. There are several types of MR present in the neuroretina, which when excessively activated can induce retinal neovascularisation, inflammation and thus increase the production of reactive oxygen species, much like those seen in diabetic neuropathy (7). Following this theory, it is believed that MR antagonism such as that offered by eplerenone administration, offers protection for the retinal vascular pathology (23).

#### 1.4. Natural history

Generally CSCR is self-limiting, typically causing transitory central vision loss with a waxing and waning course (14). Although CSCR may result in spontaneous resolution (18), it nonetheless threatens vision (8). Some studies argue that SRF self-resolving within 6 months of symptom onset (18), however a study by Quin *et al* (55) found that the majority of acute CSCR cases, resolve spontaneously within 2-3 months.

#### 1.5. Clinical manifestations

An array of symptoms, are associated with CSCR. Detachment in the central macula provokes symptoms that primarily affect visual acuity, blurred vision with metamorphopsia (1), dyschromatopsia, decreased contrast sensitivity and central scotomas (9,42).

The visual impairment is often temporary, usually unilateral (43), and painless. Metamorphopsia which often can be described as a dark spot in the center of the visual field (44), may persist and lead to poor visual quality even after restoration of visual acuity. Severe metamorphopsia has a higher incidence of PED's in patients with active CSCR (19).

Which symptoms predominate can be attributed to visual outcomes (18). Clinical features including symptom duration, baseline visual acuity (45), outer nuclear layer (ONL) thickness, integrity of the inner and outer segment (IS/OS) junction (46), and cone outer segment tip (COST) line (47), are all factors in determining the severity of CSCR presentation (18). The goal of CSCR treatment is to improve visual acuity as well as other related symptoms to prevent permanent RPE impairment and retinal atrophy by SRF elimination (48).

## 1.6. Classification

The hallmark of CSCR is neurosensory serous retinal detachment at the posterior pole (49), and this has allowed CSCR to be subdivided based on OCT findings. Type I involves only neurosensory detachment, type II includes only pigment epithelial detachment and type III has both neurosensory and pigment epithelial detachments (50,51).

CSCR can also be divided according to its duration, into two groups either acute or chronic. What constitutes acute and chronic CSCR, is debatable and ill-defined. Yannuzzi *et al* (40), describes chronic CSCR as recurrent or persistent detachments lasting 6 months or longer (40), therefore defining acute CSCR to be less than 6 months. However, there is much discrepancy and ambiguity amongst definitions, with recent clinical trials using 3 months as the distinction between acute and chronic CSCR (52).

Some studies don't distinguish between acute or chronic according to duration alone, but rather link spontaneous resolution with the acute form, defining any cases which do not resolve spontaneously within the first three months as the chronic course of CSCR (53).

A similar, but distinct classification approach distinguishes acute and chronic CSCR according to treatment, defining acute CSCR to be the first treatment attempt, and all recurrent CSCR or CSCR refractory to treatment as chronic (54,55).

## 1.7. Acute central serous chorioretinopathy (CSCR)

Disruption in continuity of detached RPE leading to focal leakage, is seen in the acute setting. It is a mechanical alteration in the integrity of the RPE, referred to as 'micro rip' or 'blow out' shown as specific leakage areas.

PEDs commonly found in CSCR could represent RPE dysfunction in response to the engorged choroid (32,56,57). Hypofluorescence pinpoints PED areas which are seen in fluorescein, and leakage into the sensory retina occurs only when there's combined serous retinal detachment.

The combination of PED findings and serous retinal detachment increases the index of suspicion for acute CSCR diagnosis (58-60).

## 1.8. Chronic central serous chorioretinopathy (CSCR)

Irreversible visual acuity loss may occur in the chronic setting, as a result of chronic macular edema, cystoid macular degeneration and photoreceptor atrophy in the fovea (61). DRPE or widespread RPE damage ensues (62), due to diffuse choroidal vasculopathy (49).

Chronic fluid present in the macular region causes photoreceptor death (63), because the detachment deprives photoreceptors of their oxygen and nutrient source. EDI-OCT is used to evaluate retinal changes in both the acute and chronic forms (50,64), and observations show photoreceptor apoptosis, which reaffirms the correlation between visual loss and photoreceptor degeneration in the chronic form of CSCR (61).

### 1.9. Risk factors

Various predisposing factors for CSCR have been suggested and investigated. Glucocorticoids are one such factor and their possible association with CSCR was highlighted early in disease investigation, by Jain and Singh (65), and further supported by several subsequent studies (28,30,66), one of which determined that those taking corticosteroids have a higher likelihood of getting CSCR compared to those not taking corticosteroids (28).

The association between CSCR and Cushing's syndrome has also been explored (67), with the suggestion that the complement system may act as a genetic risk factor in CSCR development (68). A strong correlation between CSCR and exposure to endogenous and exogenous corticosteroids exists (24,28,69), but the exact pathogenesis is unclear.

CSCR is also believed to be associated with pregnancy (70,71), specifically to plasma cortisol levels which are highest during the third trimester (72), leading to endogenous hypercortisolism (24). Following this hypothesis, any condition which leads to endogenous hypercortisolism, such as psychological stress can be argued to correlate with CSCR development, Yannuzzi's study (32), of CSCR and personality types supports this theory (32). The study by Tittl and colleagues (30), further supports this concept as they concluded that CSCR patients were more likely to use psychopharmacologic medication (30), reinforcing the role of stress in CSCR development.

### 1.10. Diagnostic methods

#### 1.10.1. Spectral domain optical coherence tomography device (SD-OCT)

Early OCT devices' visualisation was limited to one highly reflective band located in the posterior ocular fundus. In 1996 commercial OCT machines were introduced and measurements of retinal thickness were initially made from the upper margin of the highly reflective band to the inner retina (73).

It wasn't until 2007 when the SD-OCT made its entry into the commercial market, creating profound insights into retinal resolution, that a practical terminology for retinal layers became a necessity (73).

The SD-OCT improved imaging sensitivity and signal-to-noise ratio, facilitating in the discovery of previously missed outer retinal findings. Such discoverable findings include that of the external limiting membrane (ELM) which is thought to persist at the retinal attachment area, whilst the IO/OS junction (74) exhibits disruption or irregularity (75). ONL thinning at the detached retinal portion, is also seen, supporting the belief that photoreceptor cells undergo apoptosis (63).

SD-OCT is a more sensitive and specific tool for diagnosis of CSCR compared to FAF (49). It facilitates in the early detection of CSCR manifestations, such as PED and serous retinal detachment (5). The high resolution images have enabled the discovery of more subtle CSCR findings, facilitating in its understanding (76).

In SD-OCT the choroid appears thicker bilaterally, not just in the affected eye (35), this abnormality is believed to be due to choroidal vasculature dysfunction leading to its hyperpermeability. Visual acuity in CSCR is decreased and the ONL thickness, measured with SD-OCT appears to correlate with this finding by thinning, the pathogenesis of which may be as a result of photoreceptor apoptosis (61).

SD-OCT also has the ability to readily image RPE defects. The area around a leakage on FAF commonly has a PED (77), occasionally with a detectable break in the RPE barrier which is overwhelmed by fluorescein from the choroid. Similarly, to choroidal changes observed with SD-OCT, the RPE layer also exhibits abnormalities in the asymptomatic eye, these changes may represent the early warning signs of decompensation of the RPE layer.

Long term atrophy in CSCR can be measured according to foveal thickness, it is decreased in the affected eye compared to the healthy eye even after resolution of SRF (78). Foveal thickness can be a predictive factor of visual acuity outcome (79). Individuals with CSCR with more foveal thinning have their vision more severely affected, compared to those without foveal thickness changes.

#### 1.10.2. Pattern electroretinogram (PERG)

An electrophysiological modality, pattern ERG is a useful tool in which to evaluate and monitor CSCR by giving an insight into the function of the macula. It measures the electrophysiological differentiation between the optic nerve and the macular dysfunction, this enables evaluation of both the retinal function and retinal ganglion cells (49).

Using an iso-luminant stimulus, which is detected by the retina, it works by producing waves, which are either negative (N95 wave) or positive (P50 wave). The N95 wave largely represents the retinal ganglion cells, whereas the P50 wave is derived from photoreceptors located in the macula. In CSCR, there is attenuation of the N95 wave and a decrease in the amplitude of the P50 wave which indicates a lack of retinal ganglion cell dysfunction. (49)

PERG also reveals that the functional recovery of the retina may take longer than the anatomical recovery. Despite anatomical resolution, a residual deficit remains, this offers an explanation as to why some patients still complain of qualitative visual abnormalities despite displaying normal quantitative visual acuity (49).

#### 1.10.3. Multifocal electroretinopathy (mfERG)

The retinal dysfunction in CSCR is shown to be more severe in mfERG compared to observed clinical findings. The changes in mfERG largely correspond to the specific areas of observed clinical disease (80), and amplitudes show vast improvement after SRF resolution (81). It is a reasonable mode in which to follow disease course, together with improvements in OCT findings.

#### 1.10.4. Fundus autofluorescence (FAF)

The way in which FAF works, is based on the breakdown product of certain cellular structures, more specifically, it is reliant on the autofluorescent properties of such components. Lipofuscin is a breakdown product, which contains fluorophores that when correctly stimulated by specific wavelengths are able to emit light. FAF is able to aid in CSCR detection because lipofuscin accumulates in RPE cells, causing hypoautofluorescence due to atrophy of the RPE cell layer (82,83).

Previously, it could be argued that FAF can reveal leakage, in both acute and chronic CSCR. In 1986 Spitznas *et al* (31), concluded that FAF can reveal leakage in upto 95% patients in the acute stage (31), whilst a more recent study in 2015 revealed a leakage in only 65% of patients with acute CSCR (49). It is now believed that FAF is more helpful in diagnosing chronic CSCR compared to acute CSCR, because autofluorescence changes are thought to take several months before they become detectable.

In chronic CSCR, abnormal autofluorescent patterns characterise areas of RPE damage or serous detachment of varying severity (84,85). Autofluorescent deposits which accumulate in the subretinal space, may exacerbate the damage to the RPE seen in CSC (86).

As well as highlighting CSCR pathophysiology, FAF also has a functional use in predicting visual acuity (83), with Imamura *et al* (84), concluding a correlation between autofluorescence patterns and visual function (84).

#### 1.11. Treatment modalities

Typically, acute CSCR is a self-limiting process (87), visual acuity is commonly restored within 4 months, with few if any visual sequelae (88). However, recurrences are frequent with an incidence amongst CSCR patients of 30-50% in one year (89,90).

Currently the commonest initial approach to CSCR is observation, partly due to the propensity for CSCR to spontaneously resolve (91). Gilbert *et al* (92) findings, report CSCR to be a benign condition, with 80-90% cases resolving spontaneously within 2-6 months (92). However there are some instances where treatment is desirable, including but not limited to, CSCR with reduced visual acuity and persistent SRF accumulation or patients with recurrent CSCR (5).

CSCR commonly affects the working age group and appropriate management will enable affected individuals to resume their normal daily activities and return to work quicker, improving their quality of life. Additionally, effective CSCR treatment is beneficial for the public health as a whole, decreasing the public health burden.

Ultimately there is no clear consensus on CSCR management, and there are a variety of treatment options some of which include: anti-vascular endothelial growth factor (anti-VEGF) agents (93) which are administered by intravitreal injection (94), photodynamic therapy (PDT) and focal laser coagulation (FLC) (8).

##### 1.11.1. Anti- vascular endothelial growth factor (VEGF) agents

Typically, anti-VEGF agents, such as bevacizumab and ranibizumab are not part of the standard treatment, when it comes to acute or chronic CSCR, but some trials have led to the hypothesis that ischemia, either in the choroid or RPE, creates a hypoxic environment which could lead to VEGF being present, yet undetectable in ocular aqueous samples (95).

Trials of anti-VEGF use in CSCR have yet to yield definite results. One trial examining the effect of intravitreal bevacizumab in acute CSCR patients concluded no difference between the control and study group (96).

Another trial examined the one-year results of low-fluence PDT versus ranibizumab for chronic CSCR, reporting some improvement in the study group in terms of reducing the SRF (97), but concluded that further investigation is needed.

### 1.11.2. Photodynamic therapy (PDT)

CSCR is fundamentally a macular disorder. The success of PDT in treating macular degeneration with PDT using the TAP protocol (98-100), has led to studies on its efficacy in treating CSCR.

In 1999, a randomised control trial (RCT) of age-related macular degeneration (ARMD) treated with photodynamic therapy (TAP) study group was performed. The RCT showed verteporfin to be superior compared to placebo, in treating wet ARMD ( $P < 0.01$ ). SRF was reduced in the group receiving PDT, compared to the control group (54), and visual acuity remained consistent or improved in the study group.

A subsequent study based on mfERG findings, supports these findings that PDT has some effect in CSCR treatment (101). Nevertheless, more studies are needed to explore this further.

### 1.11.3. Focal laser coagulation (FLC)

Initially, the xenon laser was favoured for acute CSCR treatment, now in FLC the argon laser is more commonly used (102). A low-intensity yellow or green argon laser is used in argon laser photocoagulation and through the use of heat, provokes tissue coagulation. The heat is generated from the light beam, which is intensified on the RPE (91).

FLC treatment is based on the concept that it can speed up SRF absorption and consequential elimination, through focusing the beam on foci of leakage, previously identified by FAF. The exact mechanism of action is unknown, but it is supposed that the photocoagulation manages to seal the leak, either indirectly by promoting healing and thus the recruitment of the necessary cells for the restorative process, or by acting directly on the RPE cells.

As early as 1979, the effectiveness of FLC in expediting the resolution of SRF was shown (103). Whilst the findings are promising, a subsequent more recent study examining the long-term follow up of the 1979 study, have shown no statistical significance in recurrence rates between the study and control groups (104). A retrospective study by Gilbert *et al* (92), further adds weight to the idea that FLC offers no difference in long-term outcomes (92). Another drawback of FLC is the fact that some patients are unsuitable for laser treatment, such as those with subfoveal leaks and those with widespread diffuse leakage (5).

CSCR largely remains an enigmatic condition. This is mainly due to the natural disease course of spontaneous regression, experienced by a significant proportion of patients,



combined with the lack of RCT's. None of the previous treatment modalities have provided sufficient evidence of efficacy and they all have variable outcomes (8).

Additionally, despite numerous interventions being investigated several limitations, such as the quality of study design and the relatively small number of participating patients evaluated in the study, limits the use and validity of the existing data. There is a definite need for more RCT's to systematically evaluate CSCR treatment modalities and provide clear evidence-based treatment guidelines.

### 1.12. Prognosis

Generally, CSCR has a good prognosis, with the symptom duration linked to CSCR severity, explaining why acute CSCR has a better prognosis compared to chronic (18).

Patients with acute CSCR, usually completely recover and are restored to their former premorbid state (86). Spontaneous recovery of central visual acuity to 1.0 or better, in more than 60% of the affected eyes can be seen (88), typically occurring within four months (5).

CSCR severity is directly proportional to its duration (105). Chronic CSCR therefore has a more variable prognosis due to the chronic pooling of SRF, that causes neurosensory retinal changes and may lead to permanent visual damage (26).

### 1.13. Eplerenone

#### 1.13.1. Definition

Eplerenone is a highly selective aldosterone blocker (106) and potassium-sparing diuretic (107). It acts as a competitive antagonist with specific selectivity for the MR (108), and is already approved for the treatment of hypertension in the United States, as aldosterone blockade is proven to be beneficial for both cardiovascular and renovascular diseases (106).

#### 1.13.2. Mechanism of action

It is believed that excessive MR activation in choroidal vessels plays a role in CSCR pathogenesis (20-23). Rodent studies conducted by Zhao *et al* (20), demonstrate choroidal vessel changes such as dilation and leakage induced by high dose glucocorticoids (20,21).

Several types of MR's are also located in neuroretina (21,25) and it is hypothesised that eplerenone, acting as a MR antagonist can prevent excessive MR activation and thus prevent the pathology that leads to CSCR. Eplerenone therefore, has been proposed as a treatment option for chronic CSCR (8).

#### 1.13.3. Drug interactions

Eplerenone is primarily metabolised by the CYP3A4 enzyme and therefore caution needs to be sought when it's administered together with certain drugs, which inhibit this enzyme. Ketoconazole is one such potent inhibitor of CYP3A4, other less potent inhibitors include, but are not limited to Verapamil, Fluconazole and Erythromycin (109).

Patients should be advised not to consume grapefruit juice whilst taking eplerenone medication, as studies show it increases drug exposure by 25% (109).

Eplerenone is category B in pregnancy (110), which means that reproduction studies conducted on animals have not demonstrated a risk to the foetus, but that there are inadequate studies in pregnant women.

#### 1.13.4. Eplerenone use in central serous chorioretinopathy (CSCR) treatment

Salz *et al* (111), conducted a retrospective review of 14 chronic CSCR patients to evaluate the effect of oral eplerenone on SRF, visual acuity and choroidal thickness. Patients were observed for a minimum of three months, using EDI-OCT as the monitoring tool to measure the choroidal thickness and subfoveal fluid (SFF) height (111).

According to the EDI-OCT, 71.4% of patients displayed improvement in SFF height after 1 month, with 2 out of 14 patients having complete SFF resolution. After 1 month, the mean SFF height decreased from 130 $\mu$ m to 62 $\mu$ m ( $P=0.05$ ). Promising changes were also observed in choroidal thickness, which decreased by 33 $\mu$ m from 315 $\mu$ m to 282 $\mu$ m ( $P=0.07$ ) (111).

At 3 months, all but one patient showed SFF decreases on EDI-OCT, and 64% of patients achieved complete SFF resolution. The mean SFF height after 3 months decreased to 21 $\mu$ m ( $P=0.004$ ) with the mean choroidal thickness decreasing to 253 $\mu$ m ( $P=0.10$ ). As a result, visual acuity improved to logMAR 0.28 ( $P=0.02$ ).

Overall, it can be concluded that the Salz *et al* (111) study provides encouraging results which highlights the potential that oral eplerenone could have in treating CSCR (111).

Singh *et al* (8) examined eplerenone as a treatment for chronic CSCR using a retrospective consecutive case series of 17 eyes in 13 patients treated with 25 or 50mg oral eplerenone daily. Patients ranged from 29-85 years, and 12 eyes were previously treated with other modalities. The primary outcome was to measure the hypothesised SRF reduction using SD-OCT at the baseline and subsequent follow-up visits, with total eplerenone administration lasting between 38-300 days.

The study demonstrated statistically significant reductions in SRF measurements and subfield thickness, together with improved visual acuity suggesting that oral eplerenone is effective in chronic CSCR treatment and should be examined further (8).

Sampo *et al* (112), evaluated eplerenone efficacy in the treatment of chronic CSCR. Twenty-seven patients were involved in a retrospective study and treated with eplerenone for at least 3 months.

Visual acuity and macular OCT including SRF height, choroidal thickness and retinal thickness were evaluated prior to eplerenone administration and at two intervals: 1 month and 3 months.

Prior to eplerenone treatment retinal thickness was 266-573 $\mu$ m and by 1 month 20 out of 27 patients showed a decrease in both retinal thickness and SRF height, the average was 322.6 $\mu$ m ( $P=0.01$ ).

At the 3 months follow-up, there was a further decrease in SRF and retinal thickness by 28.3 $\mu$ m decreasing to 294.3 $\mu$ m ( $P=0.002$ ). 22.2% of patients had complete SRF resolution at 1 month which remained the same at the 3 months observation. Another 6 patients experienced complete SRF resolution by the 3 months follow-up (112).

The conclusions of this study mirrors that of the Salz *et al* (111) study showing a decrease in retinal thickness and SRF height.

Leisser *et al* (113), evaluated the effects of eplerenone on long-term recurring CSCR. There were 11 patients in this retrospective case series. Of the 11 patients, 4 had previous PDT, 3 had prior anti-VEGF treatment and 4 had experienced several prior CSCR recurrences. The age range of patients was 47-76 years (113), older than the usual affected population which is 20-50 years (5).

Neurosensory detachment and resorption was seen in 4 patients, with another 4 patients experiencing vision improvement, despite persistent residual edema. In 73% of patients their visual acuity improved (113).

This study supports the previously mentioned by Salz *et al* (111) and Sampo *et al* (112) that eplerenone achieves a good treatment response and warrants further exploration.

A retrospective chart review with 24 patients with chronic CSCR was conducted by Cakir *et al* (114). All the participating patients examined, were resistant to conventional therapy and treated with eplerenone and followed for 4 months. Eplerenone was given for 1 week at a dose of 25mg/day followed by 50mg daily. SD-OCT recorded the SRF resolution as well as central macular thickness (CMT) and best-corrected visual acuity (BCVA) (114).

After 4 months, CMT decreased by 67 $\mu$ m and there was a modest improvement in BCVA from 0.35 to 0.3 logMAR. A correlation between the RPE integrity and favourable visual outcome was noted (114). Overall similarities to previous studies were observed and the proposed clinical value of eplerenone confirmed.

Cakir *et al* (114), also emphasises the importance of early treatment in CSCR, as patients with widespread RPE changes were far less likely to benefit from eplerenone treatment (114). It is important to determine whether eplerenone is valuable in the acute setting, because despite restoration of visual acuity, which may occur spontaneously (1,48), after SRF accumulation contrast sensitivity may not recover (45,46,115).

#### 1.13.5. Eplerenone side effects

Eplerenone has a plethora of side effects, although generally they're considered uncommon (116). Eplerenone adverse effects stem directly from its mechanism of action and the condition for which eplerenone is being used, to some degree depends on the frequency, with which particular side effects occur (117-119).

General side effects of eplerenone are flu-like symptoms and fatigue. Nervous system adverse effects, include dizziness and headaches. Renal and respiratory complaints are albuminuria and coughing, respectively. Abdominal pain and diarrhoea are amongst the gastrointestinal side effects.

Side effects also differ according to gender. Male patients can exhibit endocrine complaints, in the form of gynecomastia and mastodynia (8) which have both physical and psychological implications. Whilst females may experience vaginal bleeding, with some trials reporting the rate to be 0.8% (109).

Eplerenone is associated with a dose-related increase in serum K<sup>+</sup> levels (120), making hyperkalaemia (>5.5 mEq/L), its most worrisome side effect. As a result, patients receiving potassium supplementation or potassium-sparing diuretics, should avoid the use of eplerenone. Renal function and other certain patient variables, also affect the incidence of mineralocorticoid receptor antagonist (MRA)-related hyperkalaemia, that can be seen when taking eplerenone (117).

Additional laboratory adverse events, observed in eplerenone clinical trials, include mild dose-dependent hypercholesterolemia (0.4 mg/dL at 50 mg/d to 11.6 mg/dL at 400 mg/d) and hypertriglyceridemia (7.1 mg/dL at 50 mg/d to 26.6 mg/dL at 400 mg/d) (121). Rarely, elevated levels of serum alanine aminotransferase (ALT) and gamma glutamyl transpeptidase

(GGT) are seen (8), it is believed only 0.66% of patients will experience a 3-fold increase in their serum transaminase levels. Hepatic failure cases, thus far have not been reported (109).

The Cakir *et al* (114) study, highlighted the adverse effects of eplerenone, with 13% patients stopping their treatment prematurely, as a result of these side effects (114), indicating that more extensive studies are needed to further explore which patient subgroups may benefit the most from eplerenone treatment.



#### AIMS:

1. Determine the differences in best corrected visual acuity (BCVA) before and after eplerenone treatment in acute central serous chorioretinopathy (CSCR) patients
2. Determine the morphologic changes of the retina (subretinal fluid (SRF) diameter and height; cube volume (CV); cube average thickness (CAT) and central subfield thickness (CST)) in acute CSCR patients after eplerenone administration
3. Determine whether eplerenone is a safe and effective treatment for acute CSCR

#### HYPOTHESIS:

1. BCVA will be significantly improved after eplerenone treatment
2. Retinal morphologic parameters (SRF diameter and height; CV; CAT and CST) of SRF will be significantly lower after eplerenone treatment
3. Eplerenone is effective treatment of acute CSCR

### **3. MATERIALS AND METHODS**



### 3.1. Ethical background of data collection

All data used for this thesis was gathered at the Ophthalmology department of University Hospital of Split, and was approved by the Ethics Committee of University Hospital of Split. The study adhered to the tenets outlined in the declaration of Helsinki and informed consent was obtained from all study participants.

### 3.2. Study purpose

Currently, there is insufficient evidence to conclude that treating acute CSCR yields important clinical benefits, superior to that of observation alone, which may lead to spontaneous resolution and disease regression.

At present, there is no gold standard therapy for acute CSCR treatment but of the interventions studied to date, eplerenone appears as the most promising. Previous studies have proven the effectiveness of eplerenone therapy in chronic CSCR resulting in anatomic and visual improvements in the eyes (8,107,111,112,114,122,123), however no such studies exist on eplerenone usage in acute CSCR management and this is the purpose of the present study, to examine eplerenone, as a treatment option for acute CSCR.

### 3.3. Subjects

On the basis of findings, from a retrospective consecutive case series involving patients who received oral eplerenone for chronic CSCR (8), the decision was made to conduct the present study. The present study is a prospective analysis of patients who received off-label oral eplerenone for the treatment of acute CSCR.

The diagnosis of acute CSCR can be defined by OCT, ICG and fluorescein angiography findings by the presence of SRF for less than 3 months. Recent clinical trials use 3 months as the distinction between acute and chronic CSCR (53,77) with Chan *et al* (54) defining any cases which do not resolve spontaneously within the first three months as the chronic course of CSCR (54), and Zhao *et al* (20) defining, more than 3 months as chronic evolution.

The present study included 15 eyes in 15 patients, 2 women and 13 men who were diagnosed, with acute CSCR at the Ophthalmology department of University Hospital of Split. Participants were young to middle aged, ranging from 32-55 years with an average patient age of 42.2 years.

Prior to enrolment, the key inclusion criteria for patients was a confirmed diagnosis of acute CSCR using FAF and no prior treatment. Potential participants were excluded based on the key exclusion criteria, which included patients who had a prior history of retinal vascular

diseases, including diabetic retinopathy, retinal vein occlusion, diabetic macular edema, exudative age-related macular degeneration, prior uveitis within the affected study eye (8), the use of potassium-sparing diuretics, as well as patients with abnormal renal function and increased levels of serum  $K^+$ .

### 3.4. Methods

Study participants were subjected to an initial screening and baseline procedures which included: a detailed medical history, ocular exam, and blood test. Blood samples were obtained and sent for analysis to check potassium and creatinine levels, with serum creatinine concentration  $>220\mu\text{mol/L}$  and serum potassium concentration  $>5.0\text{mmol/L}$ , both important criteria for exclusion.

Eplerenone was administered orally at a dose of 50mg daily, for a total of 28 days. Patients were observed at 3 separate follow-up visits, which occurred at 7 days; 14 days and 28 days, with SD-OCT performed at each. Information about any adverse events experienced by patients, was checked and recorded at every follow-up visit. All 15 patients were treated with eplerenone, until the end of the cohort, with no patients dropping out.

The primary outcome measure of the study, was the best corrected visual acuity (BCVA) following eplerenone administration. Secondary outcome measures comprised, SRF diameter and height, cube volume (CV) cube average thickness (CAT) and central subfield thickness (CST).

Analysis of eye examination findings was carried out using Snellen visual acuity and SD-OCT imaging. Developed in 1862 and named after Herman Snellen, a Dutch ophthalmologist, Snellen visual acuity is determined by the Snellen chart. "Normal" visual acuity is commonly taken to mean, the ability to perceive an optotype, when it's subtended 5 minutes of arc, that is Snellen's chart 20/20 feet, 6/6 meter or 1.00 decimal.

The Snellen chart assesses distance vision, by comparing an individual's results with that of an average 'normal' person, the lines on the chart becoming smaller, the further you look down. The first number of visual acuity (VA) measurement refers to the distance from the chart, this is ordinarily 6m or 20ft. The second number is the distance from the chart, at which a 'normal' eye sighted person would see. VA should be measured with the correct (hypermetropia) glasses on because it's important in determining BCVA and whether glasses are worn or not, generally has little bearing on retinal conditions (124).

The SD-OCT automatically calculates the CV, CAT and CST, with SRF diameter and height being manually measured using the SD-OCT.

SRF accumulates in the subretinal space, which is between the RPE and photoreceptor layers. The subretinal space is an embryonic remnant of the optic vesicle and under normal conditions a vacuum is created (125). The RPE is firmly attached to the underlying choroid and overlying photoreceptors, which the RPE nourishes with oxygen and nutrients.

During SRF accumulation, the RPE stretches and leads to neurosensory retinal detachment, because of the firm attachment of RPE, to the underlying choroid, a fluid filled bulge referred to as a PED is created (Figure 1) (5).

Over time the surface tension exceeds, until it reaches a point where the RPE bursts and fluid leaks into the subretinal space. This seepage of fluid can be observed by fluorescein angiography, which refer to that phenomenon as ‘smokestack’ leak, the observation is said to have derived from the similarities seen when smoke comes out of a chimney (Figure 2) (129).

In CSCR, SRF is situated between the photoreceptors and the RPE, appearing anechoic on SD-OCT. SRF diameter is manually measured from the widest point of the anechoically visible SRF on the SD-OCT and SRF height is also manually measured between RPE and neurosensory retina at the point where it is thickest (Figure 3).

According to the standard Early Treatment Diabetic Retinopathy Study (ETDRS) the macula is divided into nine subfields (126). CST, is defined as the average thickness in the central 1mm diameter circle of the ETDRS grid. CV is defined as the sum of all volumes, of all nine sections (127), normal CV is 6mm x 6mm. CAT is defined as the mean of thicknesses in nine sections (127), measured from the internal limiting membrane (ILM) to the RPE.

### 3.5. Statistical methods

Statistical analysis was performed using the statistical software Statistica 10 (StatSoft Inc., Tulsa, OK, USA).

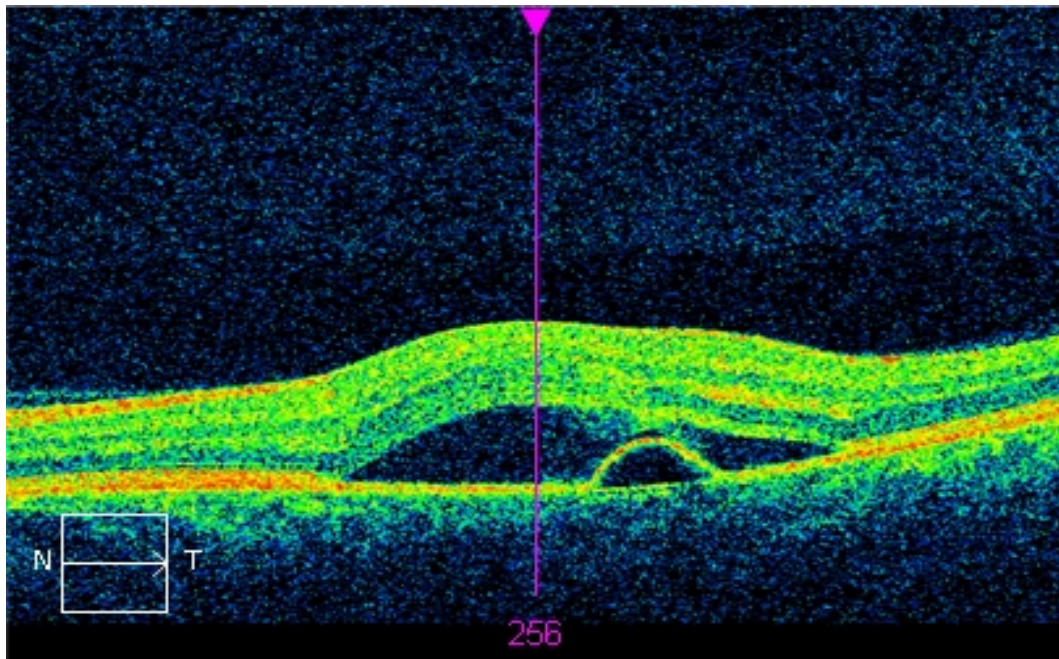
Mixed models assessed time effect within patients and outcome trends over time, evaluating both time effect and trend across all four time frames.

Nonparametric tests were used due to the smaller sample size. Significant findings were assessed using Wilcoxon matched pair test which detects which time parts differed. The test of trend was to determine whether the outcome followed a consistent trend over time by evaluating the means of each time frame. The statistical significance was set at  $P < 0.05$ .

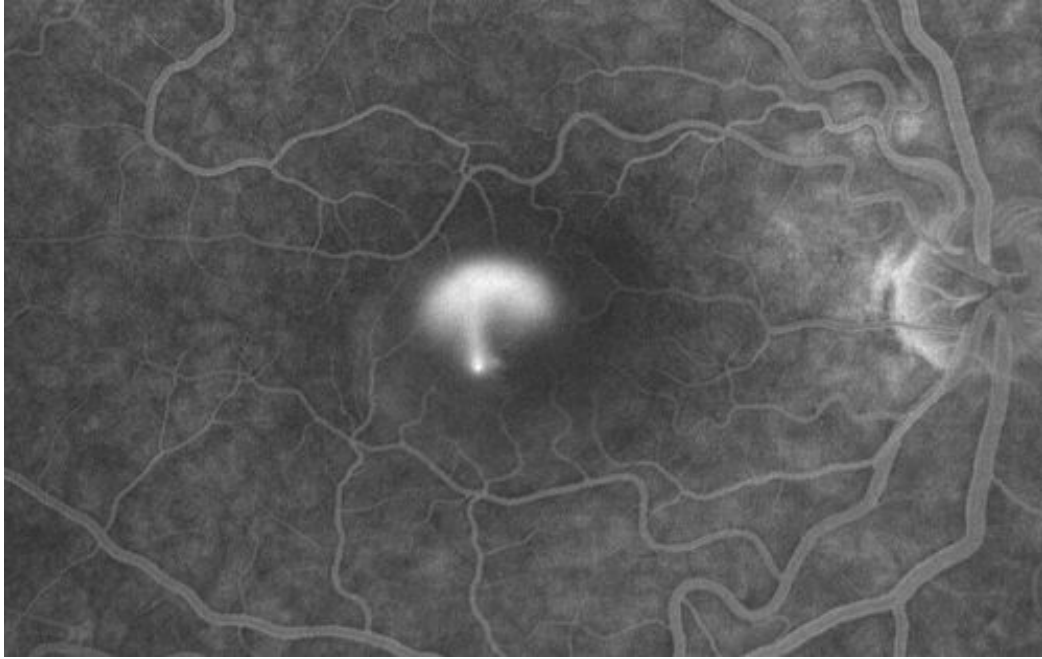
### 3.6. Imaging protocol

Percentage change as a measurement ratio at follow-up relative to baseline values, was used to compare each time frame against the baseline.

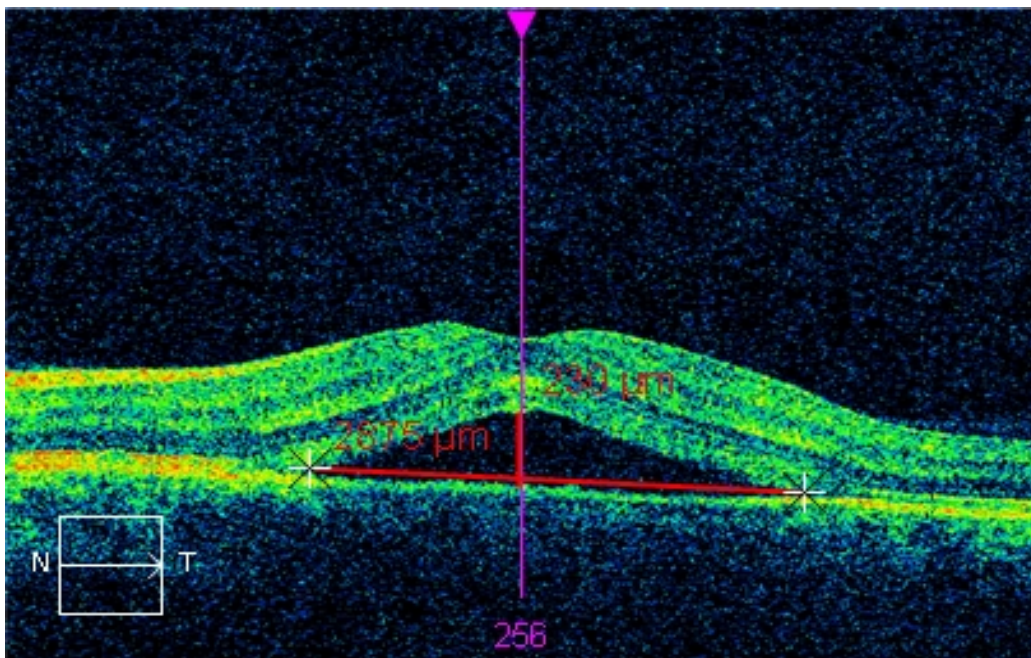
SD-OCT macular cube protocol were performed with a Zeiss Cirrus HD-OCT (Cirrus version 6.1 software) and macular cube  $512 \times 128$  protocol, at baseline and at each subsequent follow-up visit. SD-OCT measurements included CST, SRF diameter and height using reading software, CAT and CV.



**Figure 1.** Macular cube  $512 \times 128$  scan, serous retinal detachment combined with small retinal pigment epithelial detachment (PED) (*image taken from personal archive of mentor, with mentors' permission*)



**Figure 2.** Pathognomonic fluorescein angiography finding for central serous chorioretinopathy called “smokestack” leakage (*source: <http://retinagallery.com/displayimage.php?pid=5304>*)



**Figure 3.** Macular cube  $512 \times 128$  scan, manual measurements of subretinal fluid (SRF) diameter and height (*image taken from personal archive of mentor, with mentors' permission*)



#### 4.1. Baseline Characteristics

A prospective cohort of 15 eyes in 15 patients with acute CSCR were treated with 50mg/d eplerenone for a total of 28 days. The average patient age was 42 years, ranging from 32-55 years and the average BCVA was  $0.8 \pm 0.1$ .

The median baseline SRF diameter ( $\mu\text{m}$ ) was 181476 (range: 75076-10000000), median baseline SRF height ( $\mu\text{m}$ ) 1985 (range: 639-5350), median baseline CST ( $\mu\text{m}$ ) 393 (range: 337-707), median CV ( $\text{mm}^3$ ) 10.7 (range: 10-17.4) and median baseline CAT ( $\mu\text{m}$ ) 297 (range: 277-485).

The mean baseline SRF diameter ( $\mu\text{m}$ )  $239990 \pm 217450$ , mean baseline SRF height ( $\mu\text{m}$ )  $2129 \pm 1185$ , mean baseline CST ( $\mu\text{m}$ )  $431 \pm 99.0$ , mean baseline CV ( $\text{mm}^3$ )  $11. \pm 1.8$  and mean baseline CAT ( $\mu\text{m}$ )  $312 \pm 50$ .

#### 4.2. Study Outcomes

Follow-up time was divided into 3 separate physician visits of 7, 14 and 28 days, and plotted using a mixed model analysis.

##### 4.2.1. First follow-up

After 7 days, the median SRF diameter ( $\mu\text{m}$ ) was 154449 (range: 70225-767376), median SRF height ( $\mu\text{m}$ ) 1973 (range: 0.00-5112), median baseline CST ( $\mu\text{m}$ ) 392 (range: 286-737), median CV ( $\text{mm}^3$ ) 10.8 (range: 9.70-16) and median CAT ( $\mu\text{m}$ ) 299 (range: 270-448).

The mean SRF diameter ( $\mu\text{m}$ )  $191173 \pm 168432$ , mean SRF height ( $\mu\text{m}$ )  $2044 \pm 1402$ , mean CST ( $\mu\text{m}$ )  $409 \pm 111$ , mean CV ( $\text{mm}^3$ )  $11.1 \pm 1.5$  and mean CAT ( $\mu\text{m}$ )  $309 \pm 41$ .

At the first follow-up SRF height, CST, CV and CAT, did not show a statistically significant decrease, compared to the baseline ( $P=0.427$ ,  $P=0.156$ ,  $P=0.091$  and  $P=0.683$  respectively). SRF diameter did show a statistically significant decrease ( $P=0.261$ ). One patient or 6.6% of the study group demonstrated resolution of SRF height after 7 days.

##### 4.2.2. Second follow-up

The median SRF diameter ( $\mu\text{m}$ ) was 137641 (range: 40401-405769), median SRF height ( $\mu\text{m}$ ) 1396 (range: 0.00-4296), median CST ( $\mu\text{m}$ ) 350 (range: 250-520), median CV ( $\text{mm}^3$ ) 10.6 (range: 9.7-14) and median CAT ( $\mu\text{m}$ ) 295 (range: 270-384).

The mean SRF diameter ( $\mu\text{m}$ )  $151254 \pm 91207$ , mean SRF height ( $\mu\text{m}$ )  $1676 \pm 1259$ , mean CST ( $\mu\text{m}$ )  $366 \pm 82$ , mean CV ( $\text{mm}^3$ )  $10.9 \pm 1.0$  and mean CAT ( $\mu\text{m}$ )  $303 \pm 26$ .

SRF height, CST, CV, CAT and SRF diameter all had statistically significant decreases at the second follow-up compared with the baseline ( $P=0.012$ ,  $P=0.008$ ,  $P=0.013$ ,  $P=0.026$  and  $P=0.002$  respectively). 2 eyes or 13.3% of the patients achieved full resolution of SRF after 2 weeks.

The most significant decrease of SRF diameter was after the first follow up from a 7 days average of  $191173\mu\text{m}$  to a 14 days average of  $151254\mu\text{m}$ , exhibiting a 25.5% reduction.

CST decreased the most between the second and third parameter, from an average CST at 7 days of  $409\mu\text{m}$  to an average of  $367\mu\text{m}$  at 14 days.

#### 4.2.3. Third follow-up

The median SRF diameter ( $\mu\text{m}$ ) was 87616 (range: 37249-219024), median SRF height ( $\mu\text{m}$ ) 0.00 (range: 0.00-3516), median CST ( $\mu\text{m}$ ) 291 (range: 212-460), median CV ( $\text{mm}^3$ ) 10.5 (range: 9.6-12) and median CAT ( $\mu\text{m}$ ) 291 (range: 267-434).

The mean BCVA was  $0.9 \pm 0.1$  ( $P=0.01$ ), mean SRF diameter ( $\mu\text{m}$ )  $109709 \pm 62322$ , mean SRF height ( $\mu\text{m}$ )  $1047 \pm 1254$ , mean CST ( $\mu\text{m}$ )  $314 \pm 67$ , mean CV ( $\text{mm}^3$ )  $10.6 \pm 0.7$  and mean CAT ( $\mu\text{m}$ )  $295 \pm 19$ .

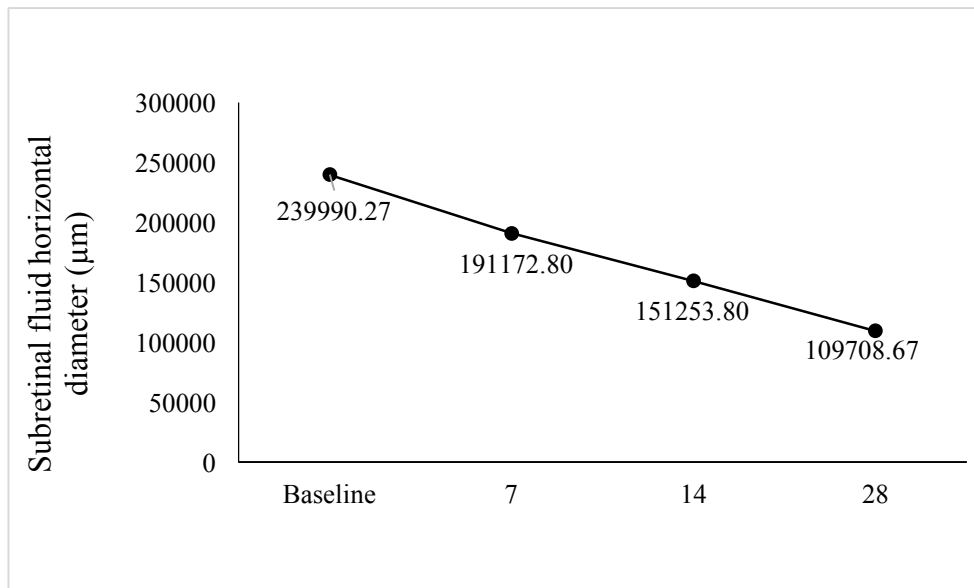
After 28 days, statistically significant decreases from the baseline were observed in, SRF diameter ( $P<0.01$ ), SRF height ( $P=0.001$ ), CST ( $P<0.01$ ), CV( $P<0.01$ ), and CAT ( $P=0.01$ ) (Figures 4-8 respectively).

CV showed the biggest difference in terms of reduction between 14 days and 28 days, showing a reduction of  $0.25\text{mm}^3$  and 5.3% decrease compared to baseline values.

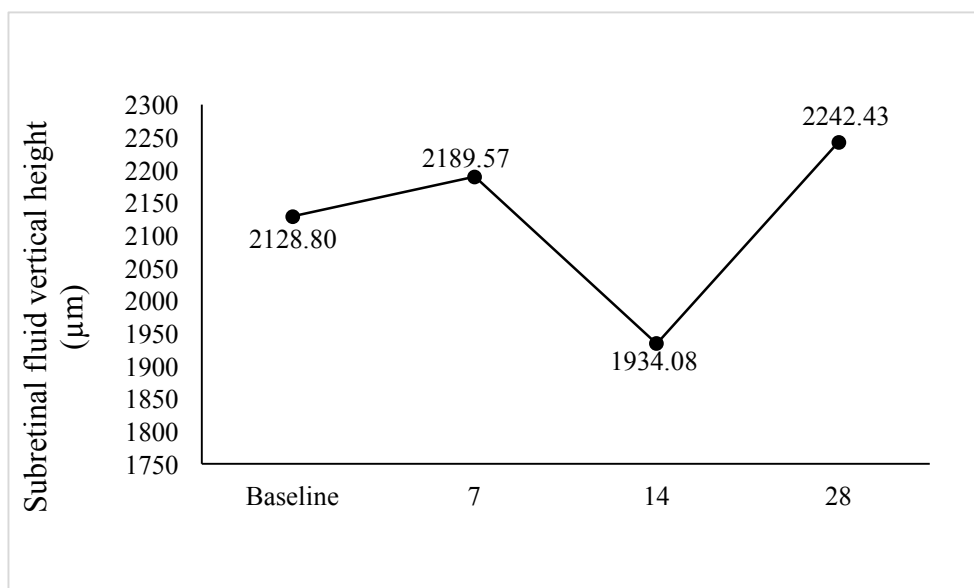
#### 4.2.4. Summary of study outcomes

At study conclusion, complete resolution of SRF was seen in 8 out of 15 (53.3%) eyes, a representative patient demonstrating eplerenone treatment response is seen in Figure 9. A further 5 eyes (33.3%) show an improvement, but failed to achieve full resolution after treatment. Out of the remaining 2 eyes, 1 eye demonstrated no treatment effect, whilst the other worsened, throughout treatment duration. After 28 days, the BCVA was  $0.9 \pm 0.1$  ( $P=0.001$ ), compared to baseline BCVA  $0.8 \pm 0.1$ .

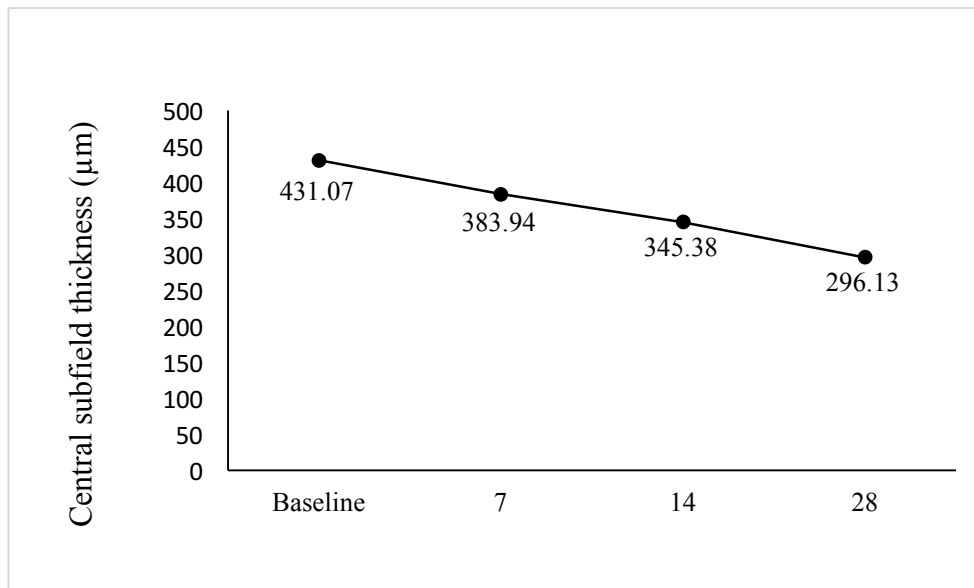




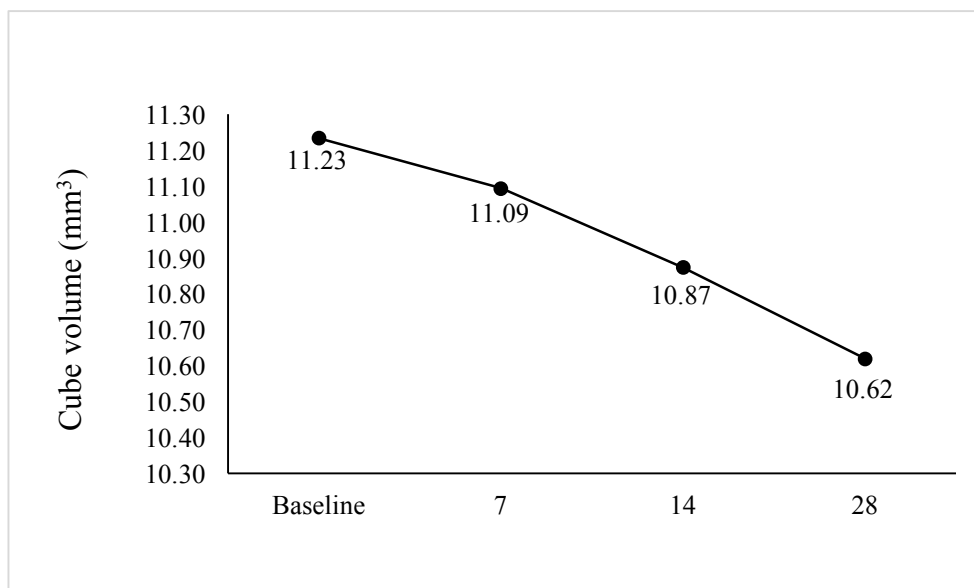
**Figure 4.** Average subretinal fluid (SRF) horizontal diameter (μm) in all patients treated with eplerenone for acute CSCR at different follow-up visits



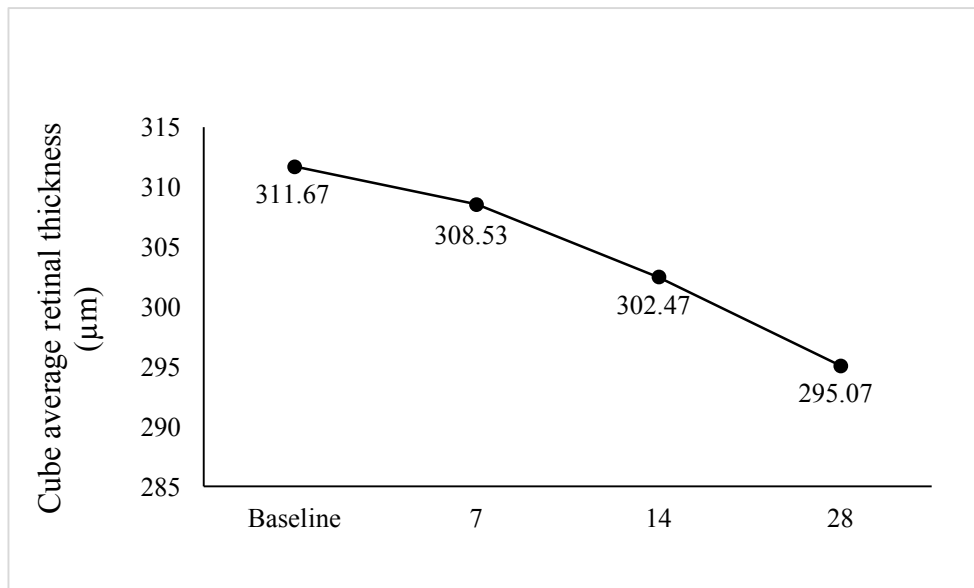
**Figure 5.** Average subretinal fluid (SRF) vertical height (μm) in all patients treated with eplerenone for acute CSCR at different follow-up visits



**Figure 6.** Average central subfield thickness (CST) ( $\mu\text{m}$ ) in all patients treated with eplerenone for acute CSCR at different follow-up visits



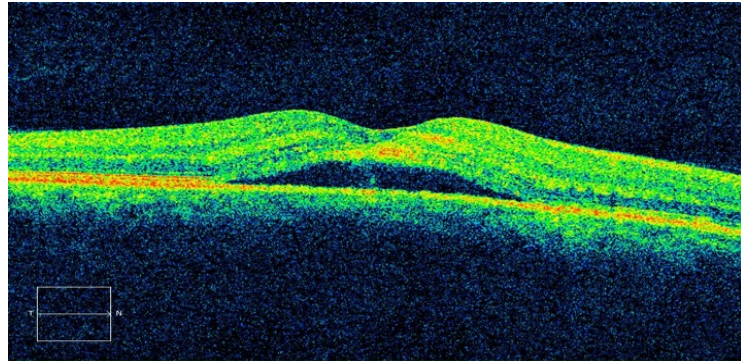
**Figure 7.** Average cube volume ( $\text{mm}^3$ ) in all patients treated with eplerenone for acute CSCR at different follow-up visits



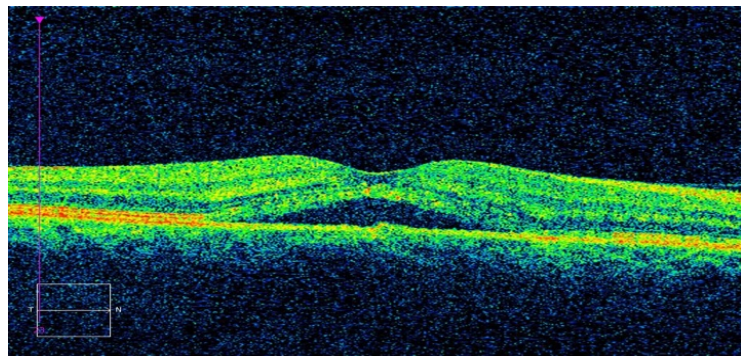
**Figure 8.** Average cube retinal thickness (CAT) (μm) in all patients treated with eplerenone for acute CSCR at different follow-up visits

Visit date      BCVA

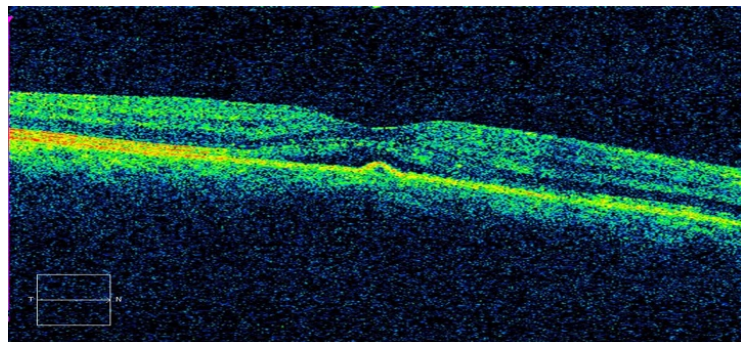
Baseline      0.8



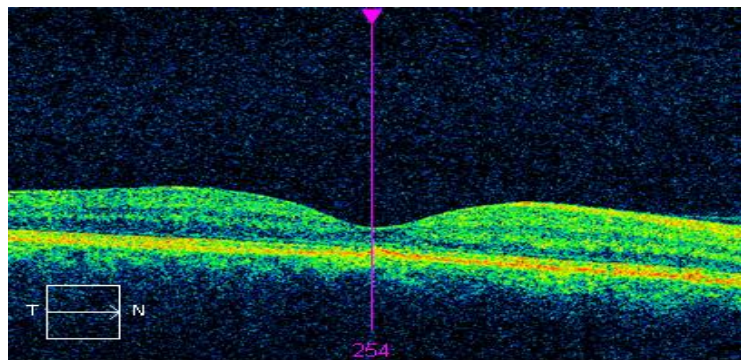
7 days



14 days



28 days      0.92



**Figure 9.** Representative patient treated with eplerenone demonstrating total resolution of SRF after 28 days

#### 4.3. Safety Analysis

Systemic adverse events (SAEs), non-ocular adverse events (AEs) and ocular assessments were used to assess safety. No side effects occurred as a result of eplerenone treatment and all 15 patients completed the study.



It is hypothesised that eplerenone, a competitive MR antagonist (108), can prevent excessive activation of MR's located in the choroidal vessels (20-23) and neuroretina (21,25), and thus prevent the pathology that leads to CSCR.

Determining whether eplerenone is effective in the acute CSCR is important, because despite restoration of visual acuity, which sometimes occurs spontaneously (1,48), the longer SRF is accumulated, the higher the likelihood that long-lasting damage to contrast sensitivity will occur (45,46,115).

The effectiveness of eplerenone in treating chronic CSCR has been suggested by previous studies, which have resulted in both anatomic and visual ocular improvements (8,20,111-114,128).

Retrospective reviews of 14 chronic CSCR patients by Salz *et al* (111) and 27 chronic CSCR patients by Sampo *et al* (112) who were both treated with eplerenone for 3 months, demonstrated full SRF resolution in 64% and 22.2% of patients respectively.

Leisser *et al* (113), evaluated the effect of eplerenone on long-term recurring CSCR, and Cakir *et al* (114) conducted a similar study on chronic CSCR patients, resistant to conventional therapy. Comparable results were seen in both, with statistically significant improvements in BCVA, which was demonstrated by 73% of patients in the Leisser *et al* (113) study.

Singh *et al* (8), examined 17 eyes in 13 patients with chronic CSCR, treating them for upto 300 days with 25/50mg/d oral eplerenone. A majority of the eyes exhibited stable SRF as a result of treatment, with a full SRF resolution seen in 35.3% (8). Singh *et al* (8) suggest the reason for their encouraging findings, is a result of eplerenones' mechanism of action. They suggest oral eplerenone is more beneficial than other treatment options, because it targets the entire retina as opposed to specific areas of foci (55,128), and that it has the advantage of being less invasive compared to either anti-VEGF injections or PDT (8).

Nevertheless, there is no gold standard therapy for CSCR treatment, and previous studies lack the sufficient evidence which is needed, to conclude that treating acute CSCR with eplerenone will yield the same promising results, seen in chronic CSCR.

Prognosis of acute CSCR is generally favourable but irreversible visual acuity loss may occur, as a result of photoreceptor atrophy in the fovea (61). Fluid present in the macular region causes photoreceptor apoptosis (63), because detachment of the neurosensory retina, causes the RPE to stretch under tension, becoming further away from the photoreceptors, depriving them of both oxygen and nutrients.

The Cakir *et al* (114) study further supports the notion that earlier intervention is associated with a tendency towards a more favourable visual outcome. They observed, that patients with widespread RPE changes, which are known to be attributable to disease duration, were far less likely to benefit from eplerenone treatment (114).

The goal of the present study was to expediently treat acute CSCR by accelerating the regression of SRF, thereby preventing photoreceptor apoptosis and improving visual acuity, enabling patients to sooner resume their daily activities unhindered and return to work faster. This is not only beneficial for the individual who experiences an improvement in quality of life, but beneficial for society at large, by decreasing the public health burden.

The natural course of acute CSCR, can be defined as SRF self-resolving within 6 months of symptom onset (18) or shorter, according to Quin *et al* (55) who argues that the majority of acute CSCR cases, resolve spontaneously within 2-3 months (55).

Taking the definition from Quin *et al* (55), best indications conclude that acute CSCR will resolve within a minimum of 2 months. The present study demonstrates that patients treated with 50mg/d eplerenone for acute CSCR have statistically significant reductions in BCVA, SRF diameter and height, CST, CV, and CAT, with a majority of patients demonstrating complete resolution of SRF after just 28 days. An additional 5 patients showed a marked improvement after study completion, but did not achieve full resolution.

The present study significantly decreases the disease duration compared to observation and we can propose that oral eplerenone is a safe and effective treatment modality for acute CSCR, further supporting Singh *et al* (8) that eplerenones probable mechanism of action is on CSCR pathophysiology.

Limitations to the present study include the small number of patients enrolled and followed up, which limits the utility of existing data. Moreover, as the follow-up time was relatively short, the rate of recurrence in our patients could not be assessed.

Further investigation, is a necessity, in order to explore the promising findings of the present study and to confirm the potential of eplerenone as a treatment choice in acute CSCR. This might be achieved by including more participants in large RCT's, to elucidate the precise role of eplerenone in acute CSCR, as well as increasing the patient follow-up time to determine the recurrence rate.

Furthermore, improvements in methods in the form of microperimetry and contrast sensitivity testing, will enable the evaluation of retinal sensitivity, specifically to determine the light sensitivity of the photoreceptors and whether they have undergone atrophy and apoptosis.



Contrast sensitivity provides an overall picture of retinal sensitivity in the fovea, by altering the spatial discrimination and contrast. It can be measured by the Pelli Robson chart, which is similar to the Snellen chart, in that instead of letters decreasing in size on each successive line, it is the contrast of the letters relative to the chart background that decreases, essentially the letters fade as your eyes move down the chart. A more sophisticated method known as the sine-wave gratings, is where parallel bars of differing contrast and varied spatial frequency replace letters, giving a more thorough evaluation.

Microperimetry is a form of visual field testing which enables the creation of a ‘retinal sensitivity map’ which depicts the quantity of light perceived in different retinal areas. The advantage microperimetry has over contrast sensitivity, is its ability to pinpoint exactly where light is seen, identifying blind spots which can be connected to organic changes in the fundus.

In the present study, eplerenone dosage is not investigated but the variability in eplerenone dosage was investigated by Bousquet *et al* (128), Zhao *et al* (20) and Singh *et al*(8), who all observed significant decreases in SRF, BCVA, and CMT, signifying that oral eplerenone may be effective in treating CSCR, regardless of dose variance and emphasising that more extensive studies are required to identify optimal eplerenone dosage and patient subgroups who would incur the most benefit.

## **6. CONCLUSIONS**

1. Eplerenone therapy accelerated subretinal fluid (SRF) resolution in acute central serous chorioretinopathy (CSCR), compared to the natural disease course.
2. Eplerenone treatment in acute CSCR resulted in a statistically significant improvement in best corrected visual acuity (BCVA).
3. Complete SRF resolution was seen in the majority (8 out of 15 eyes) of patients with acute CSCR following 28 days of eplerenone treatment.

## **7. REFERENCES**

1. Wang M, Munch IC, Hasler PW, Prunte C, Larsen M. Central serous chorioretinopathy. *Acta Ophthalmol.* 2008;86(2):126-45.
2. Guyer DR, Yannuzzi LA, Slakter JS, et al. Digital indocyanine green videoangiography of central serous chorioretinopathy. *Arch Ophthalmol.* 1994;112(8):1057-62.
3. Alkin Z, Ozkaya A, Agca A, Yazici AT, Demirok A. Early visual and morphologic changes after half-fluence photodynamic therapy in chronic central serous chorioretinopathy. *J Ocul Pharmacol Ther.* 2014;30(4):359-65.
4. Vasconcelos H, Marques I, Santos AR, et al. Long-term chorioretinal changes after photodynamic therapy for chronic central serous chorioretinopathy. *Graefes Arch Clin Exp Ophthalmol.* 2013;251(7):1697-705.
5. Nicholson B, Noble J, Forooghian F, Meyerle C. Central serous chorioretinopathy: update on pathophysiology and treatment. *Surv Ophthalmol.* 2013;58(2):103-26.
6. Maaranen T, Mantyjarvi M. Contrast sensitivity in patients recovered from central serous chorioretinopathy. *Int Ophthalmol.* 1999;23(1):31-5.
7. Gruszka A. Potential involvement of mineralocorticoid receptor activation in the pathogenesis of central serous chorioretinopathy: case report. *Eur Rev Med Pharmacol Sci.* 2013;17(10):1369-73.
8. Singh RP, Sears JE, Bedi R, et al. Oral eplerenone for the management of chronic central serous chorioretinopathy. *Int J Ophthalmol.* 2015;8(2):310-4.
9. Gass JD. Pathogenesis of disciform detachment of the neuroepithelium. *Am J Ophthalmol.* 1967;63(3):Suppl:1-139.
10. Luty GA, Hasegawa T, Baba T, et al. Development of the human choriocapillaris. *Eye (Lond).* 2010;24(3):408-15.
11. Lee WK, Baek J, Dansingani KK, Lee JH, Freund KB. Choroidal Morphology in Eyes with Polypoidal Choroidal Vasculopathy and Normal or Subnormal Subfoveal Choroidal Thickness. *Retina.* 2016;36 Suppl 1:S73-S82.
12. Carrai P, Pichi F, Bonsignore F, Ciardella AP, Nucci P. Wide-field spectral domain-optical coherence tomography in central serous chorioretinopathy. *Int Ophthalmol.* 2015;35(2):167-71.
13. Yang L, Jonas JB, Wei W. Optical coherence tomography-assisted enhanced depth imaging of central serous chorioretinopathy. *Invest Ophthalmol Vis Sci.* 2013;54(7):4659-65.
14. Chin EK, Almeida DR, Roybal CN, et al. Oral mineralocorticoid antagonists for recalcitrant central serous chorioretinopathy. *Clin Ophthalmol.* 2015;9:1449-56.

- 15.Spaide RF, Hall L, Haas A, et al. Indocyanine green videoangiography of older patients with central serous chorioretinopathy. *Retina*. 1996;16(3):203-13.
- 16.Piccolino FC, Borgia L, Zinicola E, Zingirian M. Indocyanine green angiographic findings in central serous chorioretinopathy. *Eye (Lond)*. 1995;9 ( Pt 3):324-32.
- 17.Ojima A, Iida T, Sekiryu T, Maruko I, Sugano Y. Photopigments in central serous chorioretinopathy. *Am J Ophthalmol*. 2011;151(6):940-52 e1.
- 18.Bae S, Jin K, Kim H, Bae SH. Clinical parameters related to metamorphopsia outcome in patients with resolved central serous chorioretinopathy using M-CHARTS: retrospective cohort study. *BMC Ophthalmol*. 2015;15:180.
- 19.Bae SW, Chae JB. Assessment of metamorphopsia in patients with central serous chorioretinopathy. *Indian J Ophthalmol*. 2013;61(4):172-5.
- 20.Zhao M, Celerier I, Bousquet E, et al. Mineralocorticoid receptor is involved in rat and human ocular chorioretinopathy. *J Clin Invest*. 2012;122(7):2672-9.
- 21.Zhao M, Valamanesh F, Celerier I, et al. The neuroretina is a novel mineralocorticoid target: aldosterone up-regulates ion and water channels in Muller glial cells. *FASEB J*. 2010;24(9):3405-15.
- 22.Golestaneh N, Picaud S, Mirshahi M. The mineralocorticoid receptor in rodent retina: ontogeny and molecular identity. *Mol Vis*. 2002;8:221-5.
- 23.Wilkinson-Berka JL, Tan G, Jaworski K, Miller AG. Identification of a retinal aldosterone system and the protective effects of mineralocorticoid receptor antagonism on retinal vascular pathology. *Circ Res*. 2009;104(1):124-33.
- 24.Bouzas EA, Karadimas P, Pournaras CJ. Central serous chorioretinopathy and glucocorticoids. *Surv Ophthalmol*. 2002;47(5):431-48.
- 25.Wang M, Sander B, Lund-Andersen H, Larsen M. Detection of shallow detachments in central serous chorioretinopathy. *Acta Ophthalmol Scand*. 1999;77(4):402-5.
- 26.Baran NV, Gurlu VP, Esgin H. Long-term macular function in eyes with central serous chorioretinopathy. *Clin Exp Ophthalmol*. 2005;33(4):369-72.
- 27.Spaide RF, Campeas L, Haas A, et al. Central serous chorioretinopathy in younger and older adults. *Ophthalmology*. 1996;103(12):2070-9; discussion 9-80.
- 28.Haimovici R, Koh S, Gagnon DR, Lehrfeld T, Wellik S, Central Serous Chorioretinopathy Case-Control Study G. Risk factors for central serous chorioretinopathy: a case-control study. *Ophthalmology*. 2004;111(2):244-9.

- 29.Kitzmann AS, Pulido JS, Diehl NN, Hodge DO, Burke JP. The incidence of central serous chorioretinopathy in Olmsted County, Minnesota, 1980-2002. *Ophthalmology*. 2008;115(1):169-73.
- 30.Tittl MK, Spaide RF, Wong D, et al. Systemic findings associated with central serous chorioretinopathy. *Am J Ophthalmol*. 1999;128(1):63-8.
- 31.Spitznas M. Pathogenesis of central serous retinopathy: a new working hypothesis. *Graefes Arch Clin Exp Ophthalmol*. 1986;224(4):321-4.
- 32.Yannuzzi LA. Type A behavior and central serous chorioretinopathy. *Retina*. 2012;32 Suppl 1:709.
- 33.Desai UR, Alhalel AA, Campen TJ, et al. Central serous chorioretinopathy in African Americans. *J Natl Med Assoc*. 2003;95(7):553-9.
- 34.Okushiba U, Takeda M. [Study of choroidal vascular lesions in central serous chorioretinopathy using indocyanine green angiography]. *Nippon Ganka Gakkai Zasshi*. 1997;101(1):74-82.
- 35.Imamura Y, Fujiwara T, Margolis R, Spaide RF. Enhanced depth imaging optical coherence tomography of the choroid in central serous chorioretinopathy. *Retina*. 2009;29(10):1469-73.
- 36.Negi A, Marmor MF. Experimental serous retinal detachment and focal pigment epithelial damage. *Arch Ophthalmol*. 1984;102(3):445-9.
- 37.Yannuzzi NA, Mrejen S, Capuano V, et al. A Central Hyporeflective Subretinal Lucency Correlates With a Region of Focal Leakage on Fluorescein Angiography in Eyes With Central Serous Chorioretinopathy. *Ophthalmic Surg Lasers Imaging Retina*. 2015;46(8):832-6.
- 38.Yoshioka H, Katsume Y. [Studies on experimental central serous chorioretinopathy. A light and electron microscopy]. *Nippon Ganka Gakkai Zasshi*. 1982;86(8):738-49.
- 39.Prunte C, Flammer J. Choroidal capillary and venous congestion in central serous chorioretinopathy. *Am J Ophthalmol*. 1996;121(1):26-34.
- 40.Yannuzzi LA. Central serous chorioretinopathy: a personal perspective. *Am J Ophthalmol*. 2010;149(3):361-3.
- 41.McCurley A, Pires PW, Bender SB, et al. Direct regulation of blood pressure by smooth muscle cell mineralocorticoid receptors. *Nat Med*. 2012;18(9):1429-33.
- 42.Legras M, Coscas G. Oedematous maculopathies and colour sense. *Mod Probl Ophthalmol*. 1972;11:111-6.
- 43.Erdem Toslak I, Erol MK, Toslak D, et al. Is the unaffected eye really unaffected? Color Doppler ultrasound findings in unilaterally active central serous chorioretinopathy. *J Med Ultrason* (2001). 2017;44(2):173-81.

- 44.Liegl R, Ulbig MW. Central serous chorioretinopathy. *Ophthalmologica*. 2014;232(2):65-76.
- 45.Aggio FB, Roisman L, Melo GB, et al. Clinical factors related to visual outcome in central serous chorioretinopathy. *Retina*. 2010;30(7):1128-34.
- 46.Matsumoto H, Sato T, Kishi S. Outer nuclear layer thickness at the fovea determines visual outcomes in resolved central serous chorioretinopathy. *Am J Ophthalmol*. 2009;148(1):105-10 e1.
- 47.Fujita K, Shinoda K, Imamura Y, et al. Correlation of integrity of cone outer segment tips line with retinal sensitivity after half-dose photodynamic therapy for chronic central serous chorioretinopathy. *Am J Ophthalmol*. 2012;154(3):579-85.
- 48.Gemenetzi M, De Salvo G, Lotery AJ. Central serous chorioretinopathy: an update on pathogenesis and treatment. *Eye (Lond)*. 2010;24(12):1743-56.
- 49.Goyal JL, Ghosh B, Sangit V, et al. Pattern ERG in central serous retinopathy. *Doc Ophthalmol*. 2015;130(2):141-7.
- 50.Hee MR, Puliafito CA, Wong C, et al. Optical coherence tomography of central serous chorioretinopathy. *Am J Ophthalmol*. 1995;120(1):65-74.
- 51.Iida T, Hagimura N, Sato T, Kishi S. Evaluation of central serous chorioretinopathy with optical coherence tomography. *Am J Ophthalmol*. 2000;129(1):16-20.
- 52.Chan WM, Lai TY, Lai RY, et al. Safety enhanced photodynamic therapy for chronic central serous chorioretinopathy: one-year results of a prospective study. *Retina*. 2008;28(1):85-93.
- 53.Lu HQ, Wang EQ, Zhang T, Chen YX. Photodynamic therapy and anti-vascular endothelial growth factor for acute central serous chorioretinopathy: a systematic review and meta-analysis. *Eye (Lond)*. 2016;30(1):15-22.
- 54.Chan WM, Lai TY, Lai RY, Liu DT, Lam DS. Half-dose verteporfin photodynamic therapy for acute central serous chorioretinopathy: one-year results of a randomized controlled trial. *Ophthalmology*. 2008;115(10):1756-65.
- 55.Quin G, Liew G, Ho IV, Gillies M, Fraser-Bell S. Diagnosis and interventions for central serous chorioretinopathy: review and update. *Clin Exp Ophthalmol*. 2013;41(2):187-200.
- 56.Gass JD. Photocoagulation treatment of idiopathic central serous choroidopathy. *Trans Sect Ophthalmol Am Acad Ophthalmol Otolaryngol*. 1977;83(3 Pt 1):456-67.
- 57.Yannuzzi LA, Shakin JL, Fisher YL, Altomonte MA. Peripheral retinal detachments and retinal pigment epithelial atrophic tracts secondary to central serous pigment epitheliopathy. *Ophthalmology*. 1984;91(12):1554-72.



58. Lewis ML. Idiopathic serous detachment of the retinal pigment epithelium. *Arch Ophthalmol*. 1978;96(4):620-4.
59. Laatikainen L, Hoffren M. Long-term follow-up study of nonsenile detachment of the retinal pigment epithelium. *Eur J Ophthalmol*. 1991;1(2):79-84.
60. Mudvari SS, Goff MJ, Fu AD, et al. The natural history of pigment epithelial detachment associated with central serous chorioretinopathy. *Retina*. 2007;27(9):1168-73.
61. Piccolino FC, de la Longrais RR, Ravera G, et al. The foveal photoreceptor layer and visual acuity loss in central serous chorioretinopathy. *Am J Ophthalmol*. 2005;139(1):87-99.
62. Kunavisarut P, Pathanapitoon K, van Schooneveld M, Rothova A. Chronic central serous chorioretinopathy associated with serous retinal detachment in a series of Asian patients. *Ocul Immunol Inflamm*. 2009;17(4):269-77.
63. Hisatomi T, Sakamoto T, Goto Y, et al. Critical role of photoreceptor apoptosis in functional damage after retinal detachment. *Curr Eye Res*. 2002;24(3):161-72.
64. Wang MS, Sander B, Larsen M. Retinal atrophy in idiopathic central serous chorioretinopathy. *Am J Ophthalmol*. 2002;133(6):787-93.
65. Jain IS, Singh K. Maculopathy a corticosteroid side-effect. *J All India Ophthalmol Soc*. 1966;14(6):250-2.
66. Wakakura M, Song E, Ishikawa S. Corticosteroid-induced central serous chorioretinopathy. *Jpn J Ophthalmol*. 1997;41(3):180-5.
67. Buelens T, Dewachter A. Bilateral central serous chorioretinopathy associated with endogenous Cushing's syndrome. *J Fr Ophtalmol*. 2015;38(4):e73-5.
68. Miki A, Kondo N, Yanagisawa S, et al. Common variants in the complement factor H gene confer genetic susceptibility to central serous chorioretinopathy. *Ophthalmology*. 2014;121(5):1067-72.
69. Carvalho-Recchia CA, Yannuzzi LA, Negrao S, et al. Corticosteroids and central serous chorioretinopathy. *Ophthalmology*. 2002;109(10):1834-7.
70. Sunness JS, Haller JA, Fine SL. Central serous chorioretinopathy and pregnancy. *Arch Ophthalmol*. 1993;111(3):360-4.
71. Hirji N, Watt L, Richardson E. Central serous chorioretinopathy secondary to childbirth. *BMJ Case Rep*. 2010;2010.
72. Cousins L, Yen SS, Meis P, Halberg F, Brink G. Circadian rhythm and diurnal excursion of plasma cortisol in diabetic pregnant women. *Am J Obstet Gynecol*. 1986;155(6):1176-81.

- 73.Kiernan DF, Hariprasad SM, Chin EK, et al. Prospective comparison of cirrus and stratus optical coherence tomography for quantifying retinal thickness. *Am J Ophthalmol.* 2009;147(2):267-75 e2.
- 74.Spaide RF, Curcio CA. Anatomical correlates to the bands seen in the outer retina by optical coherence tomography: literature review and model. *Retina.* 2011;31(8):1609-19.
- 75.Kim HC, Cho WB, Chung H. Morphologic changes in acute central serous chorioretinopathy using spectral domain optical coherence tomography. *Korean J Ophthalmol.* 2012;26(5):347-54.
- 76.Montero JA, Ruiz-Moreno JM. Optical coherence tomography characterisation of idiopathic central serous chorioretinopathy. *Br J Ophthalmol.* 2005;89(5):562-4.
- 77.Fujimoto H, Gomi F, Wakabayashi T, et al. Morphologic changes in acute central serous chorioretinopathy evaluated by fourier-domain optical coherence tomography. *Ophthalmology.* 2008;115(9):1494-500, 500 e1-2.
- 78.Eandi CM, Chung JE, Cardillo-Piccolino F, Spaide RF. Optical coherence tomography in unilateral resolved central serous chorioretinopathy. *Retina.* 2005;25(4):417-21.
- 79.Furuta M, Iida T, Kishi S. Foveal thickness can predict visual outcome in patients with persistent central serous chorioretinopathy. *Ophthalmologica.* 2009;223(1):28-31.
- 80.Vajaranant TS, Szlyk JP, Fishman GA, Gieser JP, Seiple W. Localized retinal dysfunction in central serous chorioretinopathy as measured using the multifocal electroretinogram. *Ophthalmology.* 2002;109(7):1243-50.
- 81.Chappelaw AV, Marmor MF. Multifocal electroretinogram abnormalities persist following resolution of central serous chorioretinopathy. *Arch Ophthalmol.* 2000;118(9):1211-5.
- 82.Schmitz-Valckenberg S, Holz FG, Bird AC, Spaide RF. Fundus autofluorescence imaging: review and perspectives. *Retina.* 2008;28(3):385-409.
- 83.Spaide RF, Klancnik JM, Jr. Fundus autofluorescence and central serous chorioretinopathy. *Ophthalmology.* 2005;112(5):825-33.
- 84.Imamura Y, Fujiwara T, Spaide RF. Fundus autofluorescence and visual acuity in central serous chorioretinopathy. *Ophthalmology.* 2011;118(4):700-5.
- 85.Matsumoto H, Kishi S, Sato T, Mukai R. Fundus autofluorescence of elongated photoreceptor outer segments in central serous chorioretinopathy. *Am J Ophthalmol.* 2011;151(4):617-23 e1.
- 86.Maruko I, Iida T, Sugano Y, et al. Subfoveal choroidal thickness after treatment of central serous chorioretinopathy. *Ophthalmology.* 2010;117(9):1792-9.

- 87.Daruich A, Matet A, Marchionno L, et al. ACUTE CENTRAL SEROUS CHORIORETINOPATHY: Factors Influencing Episode Duration. *Retina*. 2017.
- 88.Klein ML, Van Buskirk EM, Friedman E, Gragoudas E, Chandra S. Experience with nontreatment of central serous choroidopathy. *Arch Ophthalmol*. 1974;91(4):247-50.
- 89.Vacl J. [50th anniversary of Dr. Eduard Dobry, M.D., CSc]. *Vnitr Lek*. 1970;16(9):918-9.
- 90.Loo RH, Scott IU, Flynn HW, Jr., et al. Factors associated with reduced visual acuity during long-term follow-up of patients with idiopathic central serous chorioretinopathy. *Retina*. 2002;22(1):19-24.
- 91.Salehi M, Wenick AS, Law HA, Evans JR, Gehlbach P. Interventions for central serous chorioretinopathy: a network meta-analysis. *Cochrane Database Syst Rev*. 2015(12):CD011841.
- 92.Gilbert CM, Owens SL, Smith PD, Fine SL. Long-term follow-up of central serous chorioretinopathy. *Br J Ophthalmol*. 1984;68(11):815-20.
- 93.Ji S, Wei Y, Chen J, Tang S. Clinical efficacy of anti-VEGF medications for central serous chorioretinopathy: a meta-analysis. *Int J Clin Pharm*. 2017;39(3):514-21.
- 94.Ahn SJ, Woo SJ, Kim KE, Park KH. Association between choroidal morphology and anti-vascular endothelial growth factor treatment outcome in myopic choroidal neovascularization. *Invest Ophthalmol Vis Sci*. 2013;54(3):2115-22.
- 95.Lim JW, Kim MU, Shin MC. Aqueous humor and plasma levels of vascular endothelial growth factor and interleukin-8 in patients with central serous chorioretinopathy. *Retina*. 2010;30(9):1465-71.
- 96.Lim JW, Ryu SJ, Shin MC. The effect of intravitreal bevacizumab in patients with acute central serous chorioretinopathy. *Korean J Ophthalmol*. 2010;24(3):155-8.
- 97.Bae SH, Heo J, Kim C, et al. Low-fluence photodynamic therapy versus ranibizumab for chronic central serous chorioretinopathy: one-year results of a randomized trial. *Ophthalmology*. 2014;121(2):558-65.
- 98.Cardillo Piccolino F, Eandi CM, Ventre L, Rigault de la Longrais RC, Grignolo FM. Photodynamic therapy for chronic central serous chorioretinopathy. *Retina*. 2003;23(6):752-63.
- 99.Taban M, Boyer DS, Thomas EL, Taban M. Chronic central serous chorioretinopathy: photodynamic therapy. *Am J Ophthalmol*. 2004;137(6):1073-80.
- 100.Yannuzzi LA, Slakter JS, Gross NE, et al. Indocyanine green angiography-guided photodynamic therapy for treatment of chronic central serous chorioretinopathy: a pilot study. *Retina*. 2003;23(3):288-98.

101. Wu ZH, Lai RY, Yip YW, et al. Improvement in multifocal electroretinography after half-dose verteporfin photodynamic therapy for central serous chorioretinopathy: a randomized placebo-controlled trial. *Retina*. 2011;31(7):1378-86.
102. Mitsui Y, Matsubara M, Kanagawa M. [Xenon light-exposure as a treatment of central serous retinopathy (a preliminary report)]. *Nihon Ganka Kiyo*. 1969;20(3):291-4.
103. Leaver P, Williams C. Argon laser photocoagulation in the treatment of central serous retinopathy. *Br J Ophthalmol*. 1979;63(10):674-7.
104. Ficker L, Vafidis G, While A, Leaver P. Long-term follow-up of a prospective trial of argon laser photocoagulation in the treatment of central serous retinopathy. *Br J Ophthalmol*. 1988;72(11):829-34.
105. Castro-Correia J, Coutinho MF, Rosas V, Maia J. Long-term follow-up of central serous retinopathy in 150 patients. *Doc Ophthalmol*. 1992;81(4):379-86.
106. McMahon EG. Eplerenone, a new selective aldosterone blocker. *Curr Pharm Des*. 2003;9(13):1065-75.
107. Cioboata M, Alexandrescu C, Hopinca CA, et al. A new treatment approach - Eplerenone - in central serous chorioretinopathy - Case report. *J Med Life*. 2016;9(1):92-4.
108. Delyani JA. Mineralocorticoid receptor antagonists: the evolution of utility and pharmacology. *Kidney Int*. 2000;57(4):1408-11.
109. Brown NJ. Eplerenone: cardiovascular protection. *Circulation*. 2003;107(19):2512-8.
110. Sica DA. Eplerenone: a new aldosterone receptor antagonist--are the FDA's restrictions appropriate? *J Clin Hypertens (Greenwich)*. 2002;4(6):441-5.
111. Salz DA, Pitcher JD, 3rd, Hsu J, et al. Oral eplerenone for treatment of chronic central serous chorioretinopathy: a case series. *Ophthalmic Surg Lasers Imaging Retina*. 2015;46(4):439-44.
112. Sampo M, Soler V, Gascon P, et al. [Eplerenone treatment in chronic central serous chorioretinopathy]. *J Fr Ophtalmol*. 2016;39(6):535-42.
113. Leisser C, Hirschschall N, Hackl C, Plasenzotti P, Findl O. Eplerenone in patients with chronic recurring central serous chorioretinopathy. *Eur J Ophthalmol*. 2016;26(5):479-84.
114. Cakir B, Fischer F, Ehlken C, et al. Clinical experience with eplerenone to treat chronic central serous chorioretinopathy. *Graefes Arch Clin Exp Ophthalmol*. 2016;254(11):2151-7.
115. Ojima Y, Hangai M, Sasahara M, et al. Three-dimensional imaging of the foveal photoreceptor layer in central serous chorioretinopathy using high-speed optical coherence tomography. *Ophthalmology*. 2007;114(12):2197-207.
116. Taylor CT. Eplerenone (Inspra) for hypertension. *Am Fam Physician*. 2004;69(4):915-6.

- 117.Sica DA. Mineralocorticoid Receptor Antagonists for Treatment of Hypertension and Heart Failure. *Methodist Debaque Cardiovasc J.* 2015;11(4):235-9.
- 118.Mantero F, Lucarelli G. Aldosterone antagonists in hypertension and heart failure. *Ann Endocrinol (Paris).* 2000;61(1):52-60.
- 119.Stier CT, Jr., Koenig S, Lee DY, Chawla M, Frishman WH. Aldosterone and aldosterone antagonism in cardiovascular disease: focus on eplerenone (Inspra). *Heart Dis.* 2003;5(2):102-18.
- 120.Pitt B, Remme W, Zannad F, et al. Eplerenone, a selective aldosterone blocker, in patients with left ventricular dysfunction after myocardial infarction. *N Engl J Med.* 2003;348(14):1309-21.
- 121.Weinberger MH, Roniker B, Krause SL, Weiss RJ. Eplerenone, a selective aldosterone blocker, in mild-to-moderate hypertension. *Am J Hypertens.* 2002;15(8):709-16.
- 122.Rahimy E, Pitcher JD, 3rd, Hsu J, et al. A Randomized Double-Blind Placebo-Control Pilot Study of Eplerenone for the Treatment of Central Serous Chorioretinopathy (Ecselsior). *Retina.* 2017.
- 123.Singh RK, Dhadve A, Sakpal A, De A, Ray P. An active IGF-1R-AKT signaling imparts functional heterogeneity in ovarian CSC population. *Sci Rep.* 2016;6:36612.
- 124.Zapparoli M, Klein F, Moreira H. [Snellen visual acuity evaluation]. *Arq Bras Oftalmol.* 2009;72(6):783-8.
- 125.Marmor MF. Control of subretinal fluid: experimental and clinical studies. *Eye (Lond).* 1990;4 ( Pt 2):340-4.
- 126.Grading diabetic retinopathy from stereoscopic color fundus photographs--an extension of the modified Airlie House classification. ETDRS report number 10. Early Treatment Diabetic Retinopathy Study Research Group. *Ophthalmology.* 1991;98(5 Suppl):786-806.
- 127.Chan A, Duker JS, Ko TH, Fujimoto JG, Schuman JS. Normal macular thickness measurements in healthy eyes using Stratus optical coherence tomography. *Arch Ophthalmol.* 2006;124(2):193-8.
- 128.Bousquet E, Beydoun T, Zhao M, et al. Mineralocorticoid receptor antagonism in the treatment of chronic central serous chorioretinopathy: a pilot study. *Retina.* 2013;33(10):2096-102.

## **8. SUMMARY**

**Title:** ORAL EPLERENONE FOR THE MANAGEMENT OF ACUTE SEROUS CHORIORETINOPATHY (CSCR)

**Objectives:** Mineralocorticoid receptor (MR) are located in neuroretina and excessive glucocorticoid-dependent choroid activation in choroidal vessels is believed to play a large role in CSCR pathogenesis. The aim of this study was to examine eplerenone (Inspra, Pfizer), a MR antagonist as a potential treatment modality for acute CSCR.

**Materials and methods:** A prospective cohort was carried out on patients diagnosed with acute CSCR receiving oral eplerenone. Spectral domain optical coherence tomography (SD-OCT) imaging was performed, including manual measurements of subretinal fluid (SRF) diameter and height at baseline and subsequent follow-up exams. The primary outcome measure of the study, was the best corrected visual acuity (BCVA) following eplerenone administration. Secondary outcome measures comprised, SRF diameter and height, cube volume (CV), cube average thickness (CAT) and central subfield thickness (CST).

**Results:** 15 eyes of 15 patients diagnosed with acute CSCR, treated for a total of 28 days, with 50 mg/d of oral eplerenone. At study completion, statistically significant decreases from the baseline were observed in, SRF diameter ( $P<0.01$ ), SRF height ( $P=0.001$ ), CV( $P<0.01$ ), CAT ( $P=0.01$ ) and CST ( $P<0.01$ ). Complete resolution of SRF was seen in 8 out of 15 (53.3%) eyes, with further 5 eyes (33.3%) showing a marked improvement, but failing to achieve full resolution after treatment. 1 eye demonstrated no treatment effect and 1 eye worsened following treatment. The BCVA was  $0.9 \pm 0.1$  ( $P=0.001$ ) after 28 days, compared to baseline BCVA  $0.8 \pm 0.1$ .

**Conclusion:** Following eplerenone treatment for acute CSCR, an accelerated improvement of SRF resolution, in comparison to the natural disease course, and a statistically significant difference in BCVA was noted. The results of this study are in line with previous studies that eplerenone is effective mode of treatment for CSCR. However, as this study is the first of its kind to test the effectiveness of eplerenone in the acute setting of CSCR much more high-quality evidence, in the form of larger prospective RCT's are necessary to better elucidate the effectiveness of eplerenone in acute CSCR treatment.





## **Naslov:** ORALNA PRIMJENA EPLERENONA U LIJEČENJU AKUTNE CENTRALNE SEROZNE HORIORETINOPATIJE (CSCR)

**Ciljevi:** Receptori za mineralokortikoide (MR) se nalaze u mrežnici i žilnici te se smatra da prenaplašena aktivacija žilničkih krvnih žila ovisna o djelovanju glukokortikoida igra značajnu ulogu u patogenezi CSCRa. Cilj ove studije je bio ispitati učinkovitost eplerenona (Inspira, Pfizer) u liječenju akutnog CSCRa.

**Materijali i metode:** Ovo je bila prospektivna kohortna studija koja se provela na ispitanicima sa akutnom CSCR, a koji su bili liječeni oralnom primjenom eplerenona. Prilikom uključivanja u studiju i svih daljnjih kontrolnih pregleda rađena je optička koherentna tomografija te mjerenje visine i dijametra subretinalne tekućine. Primarna mjera ishoda je bila promjena vidne oštine nakon liječenja eplerenonom. Sekundarne mjere ishoda su bile: dijametar i visina subretinalne tekućine, CV (engl. Cube volume), CAT (engl. Cube average thickness) i CST (engl. Central subfield thickness).

**Rezultati:** U studiju je bilo uključeno 15 očiju od 15 bolesnika sa akutnom CSCR, koji su bili liječeni kroz 28 dana dnevnom dozom od 50 mg eplerenona. Na kraju studije nađen je statistički značajan pad dijametra subretinalne tekućine ( $P<0,01$ ), visine subretinalne tekućine ( $P=0,001$ ), CV ( $P<0,01$ ), CAT ( $P=0,001$ ), CST ( $P<0,01$ ) i u odnosu na početne vrijednosti. Potpuno povlačenje SRF je nađeno u 8 od 15 očiju (53,3%), a u daljnjih 5 očiju (33,3%) zabilježeno je značajno poboljšanje, no bez potpunog oporavka nakon terapije. U jednom oku nije zabilježen nikakav efekt terapije i u još jednom oku je bilo zabilježeno pogoršanje nakon liječenja. U usporedbi sa početnom vidnom oštrinom od  $0,8 \pm 0,1$ , 28 dana nakon terapije vidna oštrina je iznosila  $0,9 \pm 0,1$  ( $P=0,001$ ).

**Zaključak:** U usporedbi s prirodnim tijekom bolesti, nakon liječenja akutne CSCR eplerenonom zabilježeno je ubrzano povlačenje subretinalne tekućine, te je također nađena statistički značajna razlika u vidnoj oštrini. Rezultati ove studije se slažu s nalazom prethodnih studija koje kažu da je eplerenon učinkovita terapija za liječenje CSCR. No kako je ovo prva studija koja je ispitivala učinkovitost eplerenona u liječenju akutne forme CSCR, postoji potreba za većom količinom visokovrijednih dokaza dobivenih u randomiziranim kontroliranim studijama kako bi se bolje razjasnila djelotvornost eplerenona u liječenju akutnog CSCR.

## **10. CURRICULUM VITAE**

**Personal Data:**

Name: Rebecca Grimes

Date of birth: 20<sup>th</sup> May 1992

Citizenship: Irish

Address: Bijankinjeva 13, Bačvice, Split

Email: sgrgrime@gmail.com

**Education:**

2011-2017: University Split School of Medicine, Croatia

2003-2010: AS/A-levels, Merchant Taylors' Girls' School, GBR & NI

2003-2008: GCSE's, Merchant Taylors' Girls' School, GBR & NI

**Extracurricular:**

I am able to cultivate my study alongside healthy hobbies such as sport and music