

Treating vitreous floaters with Nd:YAG laser vitreolysis : determined by vision related quality of life questionnaire

Osmančević, Amar

Master's thesis / Diplomski rad

2019

Degree Grantor / Ustanova koja je dodijelila akademski / stručni stupanj: **University of Split, School of Medicine / Sveučilište u Splitu, Medicinski fakultet**

Permanent link / Trajna poveznica: <https://um.nsk.hr/um:nbn:hr:171:038107>

Rights / Prava: [In copyright](#) / [Zaštićeno autorskim pravom.](#)

Download date / Datum preuzimanja: **2024-04-24**



Repository / Repozitorij:

[MEFST Repository](#)



**UNIVERSITY OF SPLIT
SCHOOL OF MEDICINE**

AMAR OSMANCEVIC

**TREATING VITREOUS FLOATERS WITH ND: YAG LASER
VITREOLYSIS: DETERMINED BY VISION RELATED
QUALITY OF LIFE QUESTIONNAIRE**

Diploma thesis

**Academic year:
2018/2019**

**Mentor:
Assist. Prof. Ljubo Znaor, MD, PhD**

Split, 2019

**UNIVERSITY OF SPLIT
SCHOOL OF MEDICINE**

AMAR OSMANCEVIC

**TREATING VITREOUS FLOATERS WITH ND: YAG LASER
VITREOLYSIS: DETERMINED BY VISION RELATED
QUALITY OF LIFE QUESTIONNAIRE**

Diploma thesis

**Academic year:
2018/2019**

**Mentor:
Assist. Prof. Ljubo Znaor, MD, PhD**

Split, 2019

TABLE OF CONTENTS

1. INTRODUCTION.....	1
1.1. Anatomy and Histology of the Vitreous Humor	2
1.2. Physiology of the Vitreous Humor.....	6
1.3. Natural History – Aging of the vitreous	6
1.4. Etiology.....	9
1.5. Epidemiology	9
1.6. Classifications	10
1.7. Clinical Manifestations.....	12
1.8. Risk Factors.....	13
1.9. Complications	13
1.11. Diagnostic Methods.....	14
1.11.1. Ultrasonography	14
1.11.2 Optical Coherence Tomography.....	15
1.11.3 Scanning Laser Ophthalmoscopy	16
1.11.4 Dynamic Light Scattering	16
1.12 Clinical measurements.....	16
1.12.1 Quality of Life Assessment, Light Scattering and Contrast Sensitivity.	17
1.12.2 Psychological Perspective in Patients with Symptomatic Vitreous Floaters	17
1.13. Treatment Modalities.....	18
1.13.1. Pars Plana Vitrectomy.....	18
1.13.2. Pharmacologic vitreolysis	20
1.13.3. Neodymium-doped yttrium aluminum garnet laser vitreolysis.....	20
2. OBJECTIVES	25
3. MATERIALS AND METHODS.....	27
3.1. Ethical background and data collection.....	28
3.2. Study purpose.....	28
3.3. Participant recruitment.....	28
3.4 Inclusion and Exclusion Criteria	28
3.5 Vitreous Floaters Symptom Questionnaire	29
3.6 Ophthalmologic examination and posterior vitreous detachment evaluation.....	33
3.7 Intervention	33
3.8 Types of outcome measures	33
3.9 Statistical methods.....	34
4. RESULTS.....	35
5. DISCUSSION.....	44
6. CONCLUSION.....	48

7. REFERENCES	50
8. SUMMARY	57
9. CROATIAN SUMMARY	59
10. CURRICULUM VITAE.....	61

Firstly, I would like to express my profound gratitude to my mentor Assist. Prof. Ljubo Znaor for the ceaseless support of my thesis study and related research, for his patience, guidance, and substantial knowledge as well as to Ante Bašić MD, Josipa Bukić MPharm and Ivan Buljan PhD for their support and encouragement.

To my sister Selma, brother Adin and whole family, my utmost gratitude, for their interminable and unequalled love, compassion and endurance.

I wish to dedicate this diploma thesis to my mother Amra and father Edin for their relentless devotion, inspiration and self-sacrifice which has not only allowed me to follow my aspiration of finishing medical school, but enabled me to make the impossible become possible throughout my past, present and future life.

Finally, I also want to devote this thesis to the cities of Gothenburg and Srebrenica. You have always been the mitochondria to my cardiomyocytes.

1. INTRODUCTION

1.1. Anatomy and Histology of the Vitreous Humor

The vitreous derived from the greek word vitreum meaning glass is located between the lens and retina and its approximate volume of 4 mL constitutes about 80% of the globe, making it the largest structure within the eye (1). Anatomically the vitreous is to be divided into body, base and cortex, as presented in Figure 1.

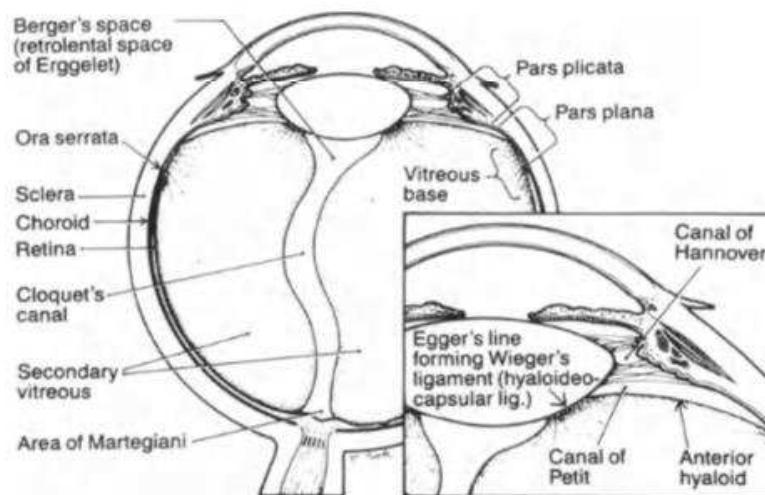


Figure 1: Anatomy of the eye and vitreous (1).

The body with its almost spherical appearance, except for the anterior part which is concave, corresponding to the presence of the crystalline lens. It consists of about 98% water, the rest are macromolecules, about 80% of proteins being albumin and immunoglobulins. Most important being collagen and hyluronan (1–3). In the emmetropic human eye the vitreous has an approximate 16.5 mm axial length with a depression posteriorly to the patellar fossa of the eye, due to the crystalline lens concavity. It is also called fossa hyaloidea. The hyaloideocapsulare or ligament of Weiger in the annular region of the vitreous, 1-2 mm width and 8-9 mm length respectively, with a sufficient diameter stabilizing the vitreous humor by attaching to the posterior capsule of the lens. The inner aspect of this attachment, known as Egger's line, delineates a space which is known as retrolental space of Erggelet's or Bergers space (1,4). Arising from this space flowing through the centrum of the vitreous, the former site of hyaloid artery in primary vitreous, is the canal of Cloquet (5). It opens anteriorly to the optic disc, an attribute called area of Martegiani (6).

Histologically the vitreous contains extracellular matrix proteins which contribute to the physical property of the vitreous, most important being the unbranched, non-cross-linked collagen fibrils. Concentration of collagen is low, approximately 300 µg/ml. Nevertheless, due

to its extensive mesh, providing gel-like properties to the vitreous (7). The distribution is heterogenic throughout the body having the most condensing area of collagen and lower of hyaluronan at its base, making it the strongest adhesion area of the vitreous (1). Concentration of collagen subsequently decreases centrally and posteriorly. Although, increases again in the posterior vitreous cortex. The collagen molecule is composed of three polypeptide chains, called α -chains that assemble into elongated fibrils, possessing high tensile strength. This fibril aggregation is due to the characteristic three amino acid sequence: proline, hydroxyproline and glycine. Hydroxyproline being unique for collagen, is used as a measurement for concentration of collagen in tissue. (8)

Type II collagen compromises 60-75% of total collagen (8,9). It is secreted as procollagens, having terminal aminopeptide and carboxypropeptide extensions, referred as N- and C- propeptides. When in extracellular environment these extensions are removed leaving non-collagenous telopeptides at each end of the tripple-helical structure, reducing the solubility and allowing them to participate in fibril formation. A non-fibril-producing collagen is type IV collagen in basement membranes which forms sheet-like structures, found in the inner limiting membrane of the retina. Other groups of collagens in the vitreous are types V/XI, constituting 20-25 % of vitreous collagen and types VI, IX (3,10).

Hyaluronic acid (HA) molecules are pure polysaccharides present in all intracellular matrices having different distribution from collagen. As opposite to the collagen, hylarunonan can be reproduced in the vitreous. However, evidence of its synthesis is circumstantial. According to an article by Jacobsen *et al.* supporting this hypothesis with their findings of enzymes essential for HA synthesis present inside hyalocytes, maintaining their continuous production, embedded in the vitreous cortex (8,12). Most abundant in the posterior cortical gel, hyalocytes decrease in concentration centrally and anteriorly (8). The basal lamina and its filter function prevents HA from diffusing into intracellular spaces of adjacent structures. One exception is diffusion through anterior cortical gel where HA enters the posterior chamber, leaving the eye through the trabecular meshwork (12). Consisting of polysaccharide chains with random coils, creating space filled with water. HA is responsible for vitreous transparency allowing light ray to reach the retina. Furthermore, due to the large domains of HA molecules there is a spread-apart effect on the collagen fibrils, minimizing light scattering. Another important function of HA is to stabilize the viscoelasticity of collagen fibrillar mesh as adjacent collagen fibrils have tendency to cross-link and alter vitreous properties. Interaction between HA and collagen is frictional, separating them promotes the gel-like composition of the

vitreous (7,13). Conversely, the interaction is not a permanent contact which can lead to vitreous floaters.

The vitreous base, a three-dimensional zone, extends 1.5-2 mm anteriorly and 1-3 mm posteriorly to the ora serrata, a band like configuration with a width of 4 to 6 mm. (8). The posterior border of the vitreous base is described as an irregular line with its “peaks and troughs”, also penetrating the vitreous body itself with several millimeters (8). The anterior aspect of the vitreous base, containing fibrils which intertwine, having a reticular complex consisting of basement-membrane material (6). Fibers from the vitreous body pierce the vitreous base spreading out to insert into the ora serrata anteriorly and posteriorly. In humans the diameters of collagen fibrils in the vitreous base range from 10.8 to 12.4 nm (1). Furthermore, importance is emphasized in posterior portion of the vitreous base where vitreous fibers are adjoining more adjacent than elsewhere (1). This plays an important part to why the vitreous base makes the strongest part of the vitreous. Other important structures of the vitreous base are the fibroblast-like cells found anteriorly and macrophage-like cells posteriorly (14). In the vitreous base we can also find damaged cells of the basal laminae in different stages, presumed to be embryonic remnants of the hyaloid vascular system.

The vitreous cortex, containing two layers that marks its borders, surrounds the vitreous humor. The anterior layer, beginning 1.5 mm in front of ora serrata, course from anterior vitreous base forming the anterior vitreous cortex, also know as anterior hyaloid face (14). In this region collagen fibrils are parallel to the surface of the cortex, creating a more compact relationship with adjacent tissue (14). The posterior layer, with a width of 100-110 μm , emerges from the posterior border of the vitreous base and forms the posterior vitreous cortex. There is no direct connection between the vitreous cortex with neither the optic disc nor retina. However, the posterior vitreous cortex is adherent to inner limiting lamina (ILL) of the basal lamina of retinal Muller cells (9). Thin adherents over the macula are found due to the low concentration of the collagen fibrils. The physiological adhesion between the posterior vitreous cortex and the internal limiting membrane is still not researched however, it remains hypothesized that it results from physicochemical properties of the extracellular matrix molecules (15). As mentioned before the cortex has embedded mononuclear hyalocytes found in a wide spread single layer 20-50 μm from the basal lamina of ciliary epithelium laterally and the ILL of the retina posteriorly. These oval or spindle-shaped hyalocytes, 10-15 μm in diameter, contain cell structures such as the Golgi-apparatus, smooth and rough endoplasmic reticula, PAS-positive lysosomal granules and phagosomes (9). It has been found that they are

arranged in a treelike branching pattern, possibly due to the retinal vessels. True function of the hyalocytes is still unknown. However, it is hypothesized to be similar to macrophages. Even though residential, they maintain an avascular and transparent vitreous (9). A structural feature of the posterior vitreous cortex is its lamellar organization of layers. Abnormality caused by a split between layers, inducing pathological conditions, is called vitreoschisis (9).

The interface is composed of a complexity formed by basal lamina of ciliary body and lens (the inner limiting lamina of retina which corresponds to basal lamina because of its analogous characteristics despite not being a true membrane in a lipid-rich, cell membrane sense), the posterior vitreous cortex and interconnecting extracellular matrix that is responsible for the adhesion (8). The only basal lamina deprived region is the perilenticular annulus of anterior hyaloid face where it is directly exposed to zonules and aqueous humor of posterior chamber (8). This area accounts for a direct communication between vitreous and posterior chamber enabling entrance and exit of aqueous fluid and substances such as erythrocytes, hyaluronic acid, growth factors (8). The basal lamina of pars plicata at the ciliary body consists of a network of lamina densa arranged as a reticular, multi-layered composition that fills the spaces between the crevices of the ciliary epithelium. However, at the pars plana true basal lamina is inserted with vitreous collagen fibrils.

The vitreous is most strongly connected to adjacent tissue at the vitreous base, the disc and macula, and over retinal blood vessels. The ILL contains an anterior (vitreous) side that is smooth and continuous whilst the posterior (retinal) is irregular, becoming more uneven as further posteriorly one goes from the ora serrata (10,14). The ILL varies in thickness with topography. Collagen fibrils oriented parallel to the ILL are found at other region with strong to weaker adhesion. The lowest density of collagen is found in the central vitreous and adjacent to the anterior cortical gel. Stronger adhesion is also found where ILL is thinner including areas such as margin of the optic disk and around fovea (3). The strength may also relate to thickness of the posterior vitreous cortex. Mechanism of attachment is not completely understood, however it is thought to result from interface macromolecules includes laminin, fibronectin and chondroitin and heparin sulphate proteoglycans, together forming a glue-like adhesion (3). Attachment plaques are to be found between muller cells and ILL at the vitreous base, equatorial regions of fundus and fovea but not in posterior pole where instead the ILL is thicker. At these sites the vitreous fibrils traverse the lamina and creates a denser interaction (3).

1.2. Physiology of the Vitreous Humor

The vitreous fluid plays a minor role in prevention of damage by filling up the entire vitreous cavity. With its presence it helps decreasing the risk development of larger retinal detachments. It helps absorb external forces, reducing mechanical deformation of the eye globe and supporting the lens during trauma to the eye. However, studies have shown this mechanical support to be of limiting significance (17,18). Thus eyes in which the vitreous has been removed during vitrectomy can still have a normal function, and the retina is not detached (8). The vitreous gel prevents topical administration of drugs and substances to reach the retina and the optic nerve due to slow diffusion and movement of flow in the vitreous gel. The ILL and the posterior cortex due to its close relationship also have the possibility to act as a metabolic buffer to the ciliary body and retina. Another physiological characteristic of the vitreous is its prospect of supplementing the retina with glucose and glycogen during anoxic conditions. The vitreous body contains electrolytes that have been additional in maintaining potassium homeostasis of the retina by acting on the muller cells. The vitreous solution contains a dense concentration of vitamin C which functions as a reservoir of antioxidants protecting the retina from induced free radicals (19). Though, it has been proved in multiple studies that normal function of the retina can be obtained after total vitrectomy. The metabolic buffer functions of the vitreous has also been shown to not play a crucial role in ocular physiology. One of the main physiological functions of the vitreous body is the allowance of unrestrained passage of light beams to the retina by maintaining optimal transparency (1,8).

1.3. Natural History – Aging of the vitreous

Physiological aging of the eye leads to a sequel of events in the vitreous. Vitreous floaters are an outcome of this biological process. Nonetheless, the clinical picture is usually not evident until either concurrent or post-current events transpire. Two main processes are essential in the aging of the vitreous; liquefaction of the vitreous gel and vitreoretinal interface weakening. Both etiologies may lead to the event where vitreous floaters become clinically important, most commonly associated with posterior vitreous detachment (PVD) (19). The vitreous body in an adult person is majorly homogenous and gel-like. However, as showed in Figure 2. liquefactions start early in life constituting about 25% of the vitreous volume after the age of 30 (19,20). With aging there is a physiological decomposition of gel substance called liquefaction or synchysis, most notable where collagen density is the lowest, in the center of the vitreous body. Synchysis appears to start early in life with a linear increase of liquid volume (8).

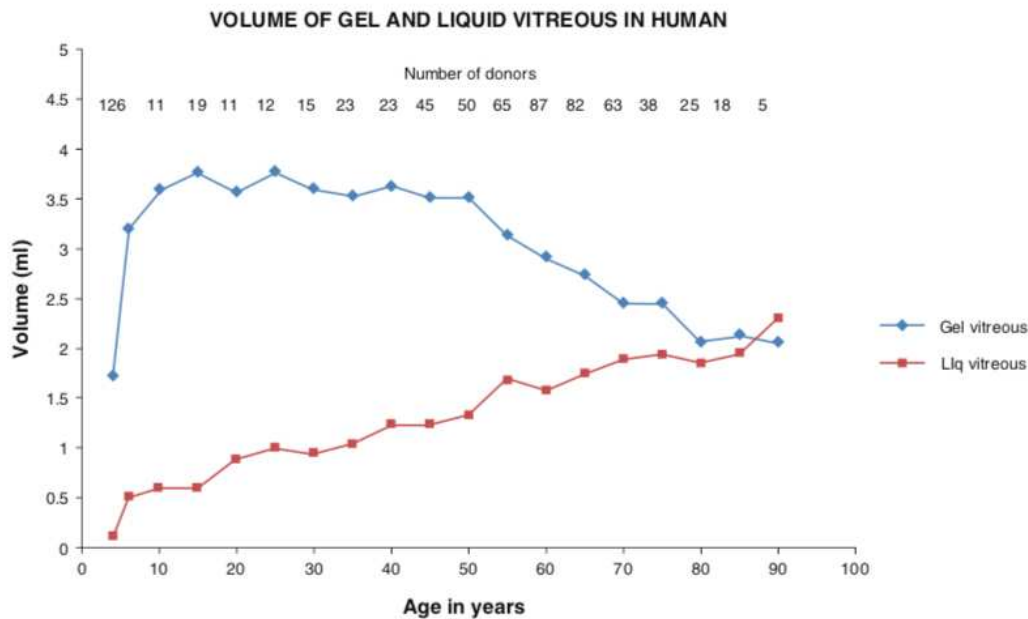


Figure 2. Graph portraying the vitreous volume constituting of both gel-like and liquid type fluid composing the fluid throughout life. Note the early start of synchysis and its life-long linear increase, appearing during the first 5 years of life in small concentrations. Each data point represents the average, derived from the number of eyes listed across the top of the graph (8).

The main reason to liquid formation is still unknown. There are three main theories to why synchysis occur. One of leading hypotheses is the change of hyaluronan structure either through HA-collagen interaction or through loss of HA. As mentioned above the hydrophilic glycoaminoglycans are important in prevention of cross-linking of collagen fibers by drawing water hydrating the matrix structure. Such a phenomenon would lead to collagen linking, collapse and formation of lacunae, with increasing size in time. Additionally, the distribution of collagen would further propagate formation (8,21). Support of this theory is found in patients diagnosed with PVD showing to have a decreased concentration of HA in comparison to patients with intact vitreous (8). Nonetheless, this theory has been criticized. Experimental studies have shown that with almost complete removal of HA, synchysis was not produced in the vitreous even with 90% extraction of of gel-volume HA (8). According to previous studies the effect of aging increase molecular weight of hyaluronan and collagen fibrils, causing covalent intermolecular crosslinking between peptide chains, an activity happening in collagen throughout the body (22). The first lacunae are formed in the pre-macular vitreous at the macula, being the prime sight for light interference and therefore also most vulnerable to its effects (23). Accumulative effect of light exposure and glycosylation producing free radicals

affect HA and collagen in presence of the photosensitizer riboflavin increasing both enzymatic and non-enzymatic cross-linking sequences (24). The generation of protein cross-linking is caused by the maillard reaction where formation of collagen binding between an amino group and glucose produce insoluble proteins. Acceleration of this process is found in patients with Diabetes Mellitus (25).

The effect of this imbalance causing liquefaction of vitreous is then replaced with aqueous lacunae that merge together throughout time. HA is further redistributed with concurring structural changes. Using dark- field microscopy, parallel anterior to posterior fibers are observed, attached to the vitreous base and ora serrata. This corresponds to aggregation of collagen fibers, no longer being separated by HA, becoming thicker and causing bundles which consequently leads to aqueous lacunae (4,26).

The second theory propose vitreous liquefaction associated with loss of type IX collagen from the surface of the collagen fibrils. Type IX collagen binds to type II collagen, which in physiological circumstances, maintaining spacing between fibrils. This inhibits them to bundle together by as type II collagen have high affinity to each other. Shown to have a shorter half-life of approximately 11 years the type IX collagen have shown to cause aggregation of collagen (27). A third less prevailing theory have proposed that primary cause to liquefaction could be collagen breakdown, more specifically type II collagen destruction throughout time (28). As a consequence of liquefaction collagen further aggregates and concomitantly cause dehiscence at the vitreoretinal interface results in entry of liquid between ILL and posterior vitreous cortex. This provokes a process called syneresis where the vitreous body collapses, further leading to PVD.

The second process in vitreous aging is the weakening of the vitreoretinal interface. Even though almost all human eyes produce synchysis of the vitreous, only a small percentage develop clinical symptoms of vitreous floaters. With a strong vitreoretinal interaction, vitreous liquefaction rarely produces vitreous body collapse or a clinical significant outcome (29). With time weakening happens at the interface and symptoms occur. However rarely before the age of 60 (30). The pathophysiological mechanisms of weakening are still unknown. One theory is that the muller cells interacting with ILL which leads to partial synthesis of extracellular matrix components of the vitreoretinal interface. Studies has shown an association between muller cell infarctions and ILL thickening that have overtime mechanically prevents production of matrix proteins to reach the interface, leading to vitreoretinal interference weakening (8).

These two processes cause inhomogeneity of the vitreous provoking light scattering and diffraction leading to visual perception of vitreous floaters. According to T.Ivanova *et al.* symptomatic vitreous floaters can be found without the definite weakening of the vitreoretinal interface causing posterior vitreous detachment (31).

Clinically important for symptomatology and the final step of vitreous aging, the most common cause of diagnostic vitreous floaters is PVD, defined as a complete separation of vitreous from retina everywhere posterior to the vitreous base. Splitting can also occur within the cortical vitreous or within the ILL resulting in components being present within the detached posterior hyaloid membrane. During PVD often a ring of fibrous tissue is found detached from the optic nerve. It is frequently visible in the cortical vitreous gel called “Weiss ring” (18,28,32). PVD can occur as a sequel of natural processing or be an initiator of vitreoretinal pathologies. Studies have suggested that up to 24 % of symptomatic PVDs result in retinal complications (33).

1.4. Etiology

Previously called myodesopsia (Greek) or muscae volitantes (Latin), vitreous floaters are opacities that produce linear gray shadows with focal dark spots, motile with head and eye movement, corresponding to inertia of vitreous body and intravitreal currents. The vitreous opacities move with characteristic damping due to viscous drag (33). Arising from endogenous and exogenous sources, etiology of vitreous floaters is divided into primary and secondary vitreous floaters. Endogenous or primary floaters, caused by collagen bundles interference with photon transmission to retina consecutively increasing the sensation of opacities. The origin of different types and their appearances is unknown (34). The most common etiology of primary vitreous floaters is posterior vitreous detachment followed by myopic vitreopathy.

Secondary or exogenous floaters consists mainly of proteins, amyloid or cells. Most common origin being pre-retinal or vitreous hemorrhage (3). Other causes are asteroid hyalosis, collagen disorders such as Marfan, Ehlers-Danlos, Sticker and Knobloch syndromes, all which have been associated with acceleration of vitreous liquefaction and symptomatic opacities (35).

1.5. Epidemiology

The clinical significance of vitreous floaters is determined mainly by underlying diseases or subjective symptomatology. Men and women appear to be affected equally (36). However, according to Schulz-Key *et al.* the onset of PVD started significantly earlier in the female gender compared to the male gender (37). The mechanism for the age disparity has been

attributed to postmenopausal loss of estrogen causing decreased synthesis of hyaluronan (31,38). According to a recent study made on patients younger than 50 years of age, an electronic survey administered 603 people via mobile phones demonstrated 76% of individuals reporting vitreous floaters and 33 % reported impairment in vision due to floaters. They concluded that floater prevalence was not significantly affected by respondent age, race, gender, and eye color and that they were found to be a very common phenomenon in the non-clinical general population sample (39). However, few studies have been done on the baseline characteristics and the prevalence of vitreous floaters on nonclinical populations (40). Schulz-Key *et al.* estimated the incidence of symptomatic vitreous floaters to 3.1/100.000 per year based on their cohort study of 80 patients over a 9-year period in Sweden (38). Epidemiology of PVD, one of the most common events that occur in vitreous and a strong indicator to symptomatic vitreous floaters have in studies showed to be present in 51 - 65 % of all eyes by the sixth decade of life (39). Several factors other than age have shown to influence onset of PVD.

1.6. Classifications

Vitreous floaters can be divided into subclinical and symptomatic floaters (41). Due to lack of symptoms the etiology to these subclinical floaters cannot be determined, as there seems to be a distinction between physiological, nonclinical floaters and floaters that distress patients and lead to clinical presentations (42). Perception originates from subjective, direct visualization. There is no standard classification for subclinical vitreous floaters. However, Institutional Repository University of Antwerpen designed a system of classification that would assist patients in indicating what they observed presented in (Figures 3 and 4). Their system structurize vitreous floaters into 3 main categorical groups. The first group being transparent floaters. They are described as delicate, see-through structures but with clear defined shapes. Subgroups of these shapes are delineated as cells (C), strands (S) and membranes (M) (Figure 3) (41). Quantity of floaters were graded 0-3. The second categorical group are opaque floaters which are optically dense structures with verifying size and morphology with further grading based on size and number. This group is also described as well-defined (sharp, dark edges) or ill-defined (fuzzy, indistinct edges) which are noted by additional letter "I" to the classification (Figure 3). Third group called "others" was added to account floaters with a ring-shaped morphology (41).

Reason to non-standardized classification may be owing to ophthalmologists, instead of categorizing type of floaters in symptomatic patients, they choose to use PVD classifications,

secluding the floaters as symptoms of an acute PVD, neglecting its importance. Another reason to this lack of assortment may be that floaters, until recently, have by medical community been viewed as an innocuous and benign activity with good outcome (no need for interventions) that improves over time needing no greater reason for classification. In most publications researchers usually describe symptomatic floaters as string and nod like or spider-web like floaters (3,41).

Due to lack of correlation between type of floater and discomfort of symptoms there seems to be of no great importance for detailed classifications of vitreous floaters in clinical ophthalmology. Nevertheless, due to lack of evidence, correlation between a patient's perception and change in measurable visual acuity creates a significant problem in treatment. Without a significant decline in visual acuity, surgeons are uneager to interfere. The difficulty is not associated with the patients' perception, but rather the lack of appropriate assessment tools and way of classifying symptomatic vitreous floaters creates a need for a metric to quantify the outcome (3). Worth mentioning in this diploma thesis is the review by T. Ivanova *et al.* dividing symptomatic vitreous opacities (SVO) into two main categories; SVO without PVD and SVO with PVD (31).

Floater Type	Characteristics
C	Cells, free-floating transparent dots, points, or "bubbles"
S	Strands, free-floating strings, lines of any length or shape
M	Membranes, free-floating larger nonlinear structures, curtains
SSI	Small, single free-floating point (ill-defined)
SMI	Small, multiple free-floating points (ill-defined)
LSI	Large, single free-floating point (ill-defined)
LMI	Large, multiple free-floating points (ill-defined)
VLI	Very large (ill-defined)
SS	Small, single free-floating point
SM	Small, multiple free-floating points
LS	Large, single free-floating point
LM	Large, multiple free-floating points
VL	Very large
Other	Ring shaped

Figure 3. Floater shapes (41).

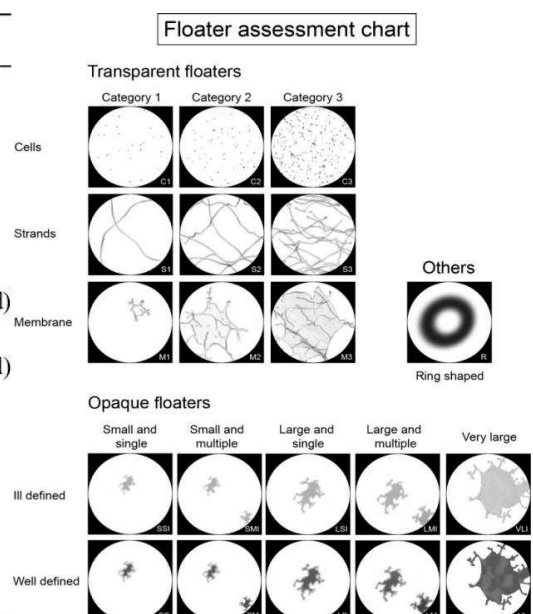


Figure 4. Floater classification system (41).

1.7. Clinical Manifestations

Symptomatic vitreous floaters found without PVD are caused by natural physiologic aging of the vitreous liquefaction causing aggregation of collagen fibrils, when sufficiently large become visible causing the opacity symptom. Liquefaction in conjunction with age-related weakening of the vitreoretinal adhesion result in symptomatic vitreous opacities with PVD. The clinical manifestation of vitreous floaters in this thesis is mainly based on the diagnosis of PVD. Usually PVD is asymptomatic until final stage of vitreo-retinal dehiscence. However, even then there may be no signs of manifestation. Most common symptom of PVD is vitreous floaters (1,28). Another common sign is photopsia or Moore's light flashes. These flashes occur within 27 to 42 % of cases, resulting from traction or impact exerted by the vitreous onto the retina increasing the risk of retinal tears. Similar traction on vascular structure of retina or optic disk can induce hemorrhage in 21% of eyes with symptomatic PVD (8). According to Sebag, PVD has during a long time been perceived as an acute process owing to a long activity of liquefaction. By the use of optical coherence tomography (OCT) efficient identification of PVD have been enabled. (7)

Floater emerging from intravitreal structural changes, example being myopic vitreopathy tend to be chronic and progressive as compared to floaters originating from PVD which tend to be acute in onset though, transient (41). Floaters are more noticeable when situated in the visual axis. Once floaters are formed, they cause an area of uniform partial illumination called penumbra radiated dorsally onto the retina. According to T.Ivanova *et al.* (31) over time residual gel continues to further collapses, moving the posterior hyaloid membrane anteroinferior, causing the primary floaters to become less visible, partly owing to adjustment. According to Serpetopoulos *et al.* there has been mathematically shown that the shadow of the vitreous opacity on the retina is determined by the diameter of the opacity and distance from the retina as the overall distance between the pupillary plane and retina. When the vitreous floaters move forward their shadow no longer reach the retina and the patient neglects perception of them or being aware of them intermittently (42,43). However, opposing this theory Milston *et al.* stated that no data has been proved to support the concept that these endogenous floaters become less symptomatic when confined below the visual axis (3).

Most patients with symptomatic vitreous floaters have no loss of visual acuity and the treatment is predominantly patient-driven. The majority of patients with transient symptoms learn to accommodate to the symptoms and even neglect them. Nonetheless, a small group complaining on vitreous floaters having a significant impact on the quality of life (44).

Symptomatic floaters have been associated with retinal breaks or serious retinal detachment, specifically when symptoms are sudden and accompanied by light flashes. PVD has been associated with significant reduction in contrast sensitivity function as well as functional quality of life when comparing effect of age-related macular degeneration or other systemic diseases on quality of life (3).

Kim *et al.* made a predicament in their cross-sectional study that patients with symptomatic vitreous floaters suffered more psychological problems such as depression, stress and anxiety when compared to control group (45). Furthermore, there was a degree of floater-related discomfort correlating with severity of psychological distress. Cipolletta *et al.* approached symptomatic vitreous floaters from a psychological perspective, suggesting that some patients who continued to complain on vitreous floaters after consulting an ophthalmologist, did not necessary associate with any ocular pathology (40).

1.8. Risk Factors

In previous articles there has been no mentioning of risk factors for vitreous floaters. The reason being that they most often are asymptomatic and benign (3). Aging of the vitreous humor being a great factor of importance is described as natural history as it's a physiological phenomenon and not a pathogenic one, only contributing to the sensation of vitreous floaters. PVD, myopia, asteroid bodies and others have been pointed out as etiological factors or causative factors of symptoms but are not increasing the risk for floaters merely the perception of already produced floaters (46). Collagen disorders such as Marfan and Stickler syndrome are two risk factors for earlier onset of PVD but once again causes earlier perception of vitreous floaters (3,47).

Therefore, in this diploma thesis no further discussion on risk factors for vitreous floaters will be debated.

1.9. Complications

PVD is mostly a natural part of physiological aging and does not usually result in any complications however, in few cases PVD can be the inciting cause of multiple vitreoretinal pathologies. Studies have suggested that up to 24 % of symptomatic PVDs result in retinal complications (8,35). Early PVD is often undetected and asymptomatic. Nevertheless, there has been described events where pre-clinical PVD antecedent to complete PVD led to substantial consequences affecting both the vitreous and retina. Sebag *et al.* postulated the concept of anomalous PVD (APVD) describing it as the disconnection between liquefaction

and interface dehiscence (8). Milston *et al.* described this as rhegmatogenous PVD (3). The pathological manifestation of APVD is determined by location of persistent gel adhesion. One example is the macula, causing vitreo-macular traction syndrome. At the disk or blood vessels vitreo-papillary traction or retinal hemorrhage was found, respectively. A second importance in pathology of APVD is the structural integrity of the vitreous cortex where the lamellar structure can split (vitreoschisis) causing more posterior vitreous cortex layers to remain adherent to the retina (8). In further studies by Johnson *et al.* advancement was made in understanding and creating two categories based on size of adhesion. Smaller sizes (500 μm or less) caused a localized tractional force with high stress over a small area of the central macula with negative quality of life outcomes and ocular pathologies such as full thickness macular holes, pseudo-operculum, vitreo-faveolar traction syndrome (48). Large adhesion zones (500 μm or greater) disperse the traction force, with less traction stress, being less likely to create macular holes but instead vitreomacular traction syndrome or traction diabetic macular edema and possibly neovascular age-related macular degeneration (8,48). Both Sebag and Johnsons models contrast physiologic, uncomplicated PVDs with PVDs that are complicated by vitreoretinal pathology, recognizing macular and peripapillary areas as most common sites of adhesion and that variations in size and strength are important factors in determining PVD complications (49). Johnson *et al.* emphasized evolution and complication of early stages of PVD as Sebag described the role of vitreoschisis. Both models suggest that late complications of PVD such as retinal tear, detachment and vitreous hemorrhage occur only after vitreopapillary separation due to increased traction forces. Another late complication is cataract formation, presumably due to changes in oxygen tension in the vitreous cavity (49).

1.11. Diagnostic Methods

1.11.1. Ultrasonography

Ultrasonography (US) is routinely used to establish the diagnosis of PVD and rule out retinal detachment. Quantitative ultrasonography of vitreous and quantitative index of vitreous echodensity have also been used to assess floater severity. The ultrasound is based on reflection or scattering of high-frequency sound waves caused by acoustic impedance inhomogeneity's or interfaces. Acoustic impedance is defined as the outcome of speed, sound and density. Similar to OCT there is a refractive index alteration causing light to scatter or reflect. The main advantage of US over OCT is its penetration. The US can visualize the entire vitreous without being disturbed by iris and sclera. Ultrasound is a good diagnostic tool for imaging opacities within the entire vitreous body based on echo-density and impedance difference at gel-liquid

interface. Using conventional B-scan ultrasound assessment can be made to differentiate sound wave impedance at interfaces of tissues with different densities. US can discriminate retina from vitreous or liquefied vitreous from physiological gel vitreous. There is also found to be a positive correlation between quantitative ultrasonography, contrast sensitivity and quality of life (quantified by National Eye Institute Visual Function Questionnaire) which can be used to measure effects of vitrectomy, Nd:YAG laser vitreolysis and pharmacologic vitreolysis (50). B-scan ultrasound can be used to visualize floaters since they have different acoustic reflection compared to normal vitreous gel. On the B-scan they are represented by increased speckling of the image which has also been shown to increase with age. Disadvantage of the US when compared to OCT is that it requires acoustic coupling, such as gel in a contact exam. On US, the posterior vitreous cortex is not detectable when attached to the retinal surface. It may detect and differ age-related PVD and pathologic phase alterations within the vitreous body. B-scan ultrasonography can be used in suspicion of a PVD however, it cannot define vitreous cortex due to insufficient level of resolution. When the posterior vitreous cortex is sufficiently displaced anteriorly the diagnosis of complete PVD can be reliably established by ultrasonography (8).

1.11.2 Optical Coherence Tomography

Optical Coherence Tomography (OCT) technology is used for retinal imaging, glaucoma imaging and imaging of the anterior segment. OCT signals are generated by reflection and scattering of light by refractive index inhomogeneity's present in tissue. By using a Michelson interferometer, it is possible to measure range and backscatter amplitude along numerous lines of sight from at cross-sectional image. Coherence is defined as a measure of ability of a light source to produce high contrast interference fringes when interfered with itself (8). In spectral-domain OCT (SD-OCT) the interference pattern between a reference mirror and the sample is broken into a spectrum by an optical grating with the spectrum being recorded. Swept- source OCT (SS-OCT) offer several advantages over grating-based SD-OCT, including more adequate sensitivity with imaging depth, longer imaging range, and higher detection efficiencies (3,51). OCT gives us a detailed imaging of both transverse and coronal aspects of the vitreoretinal interface. Combination of OCT with scanning laser ophthalmoscopy can be used to more adequately evaluate the interface in various pathological states. However, OCT only images floaters that are within a few millimeters of the retina and cannot therefore identify all vitreous opacities, those found in anterior and central vitreous (8). Nonetheless, OCT has demonstrated in vivo areas of shadowing behind vitreous opacities defining them as "floater

scotomas” (8). OCT technique can be misdiagnosed when empty space of posterior precortical vitreous pockets are thought to be complete PVD. When uncertainty is found it could be distinguished by observing the peripapillary region to ensure vitreous status because the area where the vitreous is attached until complete separation (3). Following the ultrasound nomenclature, a one-dimensional representation of amplitude along one line-of-sight is called an “A-scan,” while a two-dimensional cross-sectional image formed from a series of lines-of-sight is called a “B-scan”.

1.11.3 Scanning Laser Ophthalmoscopy

Scanning Laser Ophthalmoscopy (SLO) can be used for evaluating and documenting vitreous floaters. This imaging technique can conduct both the umbra and penumbra casts, and by visualizing these quantitative measures can be used as a diagnostic tool to measure the index of clinical severity (52). This instrument includes the features of large depth of field and also offers real-time recording. The use of monochromatic green as well as other wavelengths of light have been used for illumination. However, SLO only improves imaging of vitreous in prepapillary posterior vitreous and does not adequately image the vitreous body and posterior vitreous cortex. Thus to diagnose PVD alone is not sufficient. However, a combination of SLO imaging with OCT has shown in new studies to enable better visualization of the vitreous and vitreoretinal interface (48). SLO/OCT are able to perform OCT imaging in the coronal plane simultaneously to SLO imaging with exact point-to-point registration thus enabling the superimposing of the OCT image onto the SLO image (3,52).

1.11.4 Dynamic Light Scattering

Dynamic Light Scattering (DLS) uses a laser-based nanodetector as a noninvasive in-vivo visualization of particles ranging from 3 nanometers to 3 micrometers within the ocular media, including cornea, lens, aqueous and vitreous (8). This imaging technique can evaluate effects of vitreous macromolecules following pharmacologic vitreolysis (8). According to Sebag the use of DLS to study vitreous biophysical properties will play the future role in diagnosing and routinely evaluating the vitreous structure and its pathologies (3,53).

1.12 Clinical measurements

Objective clinical measures can determine the severity of floaters both on structural (quantitative ultrasonography, OCT) as well as functional (Quality of Life Assessment, Contrast Sensitivity and Light Scattering) criteria.

1.12.1 Quality of Life Assessment, Light Scattering and Contrast Sensitivity.

Studies suggest that vitreous floaters have a significant negative impact on the quality of life. A strong positive correlation was detected between quality of life assessment using standardized national eye institute visual function questionnaire and quantitative ultrasonography objectively supporting this theory (8). Other studies used non-standardized self-administered questionnaires. Though, also detecting same correlation (8). Wagle *et al.* cohort study on 266 patients using standardized utility value questionnaire, concluding that symptomatic degenerative vitreous opacities showed a negative impact on quality of life. According to the same study patients were willing to accept a 7 % risk of blindness (3,39). Light scattering or disability glare is perceived when light is spread around a bright light source. Van den Berg *et al.* published a review explaining that this phenomenon included symptoms such as hazy vision, difficulty driving at night and decreased facial recognition (54). De Nie *et al.* examined the effect on quality of life looking at vision-dependent tasks. In this study more than two-third of patients had moderate or extreme difficulty in reading small print as driving at night. They concluded that vitreous floaters for some individuals are just as problematic as other well-established ocular pathologies, despite patients with SVO having good visual acuity (3,55). Contrast sensitivity (CS) measurement is used to complement visual acuity testing, by evaluating 100% contrast within the central degrees of the visual field. Sedun and Sebag recently hypothesized that floaters affect vision, negatively impacting quality of life by reducing CS via light scattered from vitreous floaters. This creates large penumbras degrading the CS. Furthermore, they stated that CS in patients with vitreous floaters normalized following treatment with a positive correlation between quality of life and degree of vitreous opacification (56).

1.12.2 Psychological Perspective in Patients with Symptomatic Vitreous Floaters

Particular personality traits are more likely to consider SVO an ocular pathology severe enough to justify treatment. To today knowledge, two different hypotheses tries to explain this. Schiff *et al.* stated that professionally successful and intelligent participants noticed vitreous floaters more frequently and had an increased desire to have them treated (46). Roth *et al.* identified a correlation between subjective distress caused by SVO and level of education (3,56). Schulz-Key *et al.* suggested that patients with personal traits showing persuasive and stubbornness were more selected to treatment (37). All these studies have suggested certain potential personality traits. However, no definitive evidence has proved these two theories. According to Milston *et al.* most patients do not fit this profile and are simply seeking improved

quality of life, further stating that it's difficult to distinguish patients' dissatisfaction due to floaters and other psychological reasons thus fixating them on their vitreous opacities (3). In a cross-sectional study by Kim Y-K *et al.* (45) most patients, evaluating both objective anatomical status and subjective psychological features, showed a correlation between symptomatic vitreous floaters and patients suffering from more profound psychological problems, such as depression, anxiety and stress compared to the control group. The degree of floater-related discomfort was well correlated with severity of psychological stress. The psychological health questionnaire used showed that patients with symptomatic floaters to belong to sub-threshold depression. However, it is uncertain if participants with greater depression, rate their floater symptoms as more severe (3). An association between complete PVD and degree of vitreous opacity uncomfortableness was less significant, stating that a complete PVD might be an important initiating factor. Though, degree of symptoms is different from patient to patient. Yong *et al.* concluded that even if the presence of SVO was mostly determined by anatomical status the severity of symptoms was more related to the degree of patient's psychological distress (48).

1.13. Treatment Modalities

Patients being diagnosed with vitreous floaters are mainly managed conservatively with suggestions that they will adapt and neglect visual symptoms over time as the floaters will settle inferior to the visual axis. Before considering treatment options it is crucial to make a thorough family history of previous ocular pathologies, prematurity, feeding problematic, arthritis and midline defects (8). Fundoscopic examination is used to rule out differential diagnostics, as well as OCT and fluorescein angiography are used to detect areas of nonperfusion (8).

1.13.1. Pars Plana Vitrectomy

Surgical vitrectomy removes the vitreous and its associated floaters. Replacing it with saline solutions due to its translucency and inertia through small openings in the pars plana. A variety of techniques have been used: conventional 23-gauge pars plana vitrectomy (PPV) with 3-port trocar, bimanual 23-gauge vitrectomy with 4 port trocar, 25- gauge pars plana vitrectomy, vitrectomy combined with cataract surgery, as well as 27- gauge vitrectomy (3). Numerous studies have evaluated the success of vitrectomy for treating vitreous floaters when weighting potential risks. According to major review in 2016 by Milston *et al.* 630 cases were reported using various sized instruments and different degrees of invasiveness where all

vitrectomies removed collagen and hyaluronan as contradistinction to Nd:Yag laser treatments where only collagen is targeted.(3). Being the most common approach for surgical procedure in a variety of retinal pathologies such as retinal detachment, macular hole, epiretinal membrane and proliferative diabetic retinopathy, often using the three-port entry pars plana vitrectomy with microscope visualization and endoillumination (57). Current surgical techniques are transconjunctival sutureless vitrectomies having both minimal incisional size and adhesive characteristics of the eye (3). Aspiration settings and cut rates per minute are between 400-600 and 1800-2500, respectively. The amount of vitreous removed varies with individual surgery and amount of preservation. The salt solution infused varying from 5 – 15 ml, although no study on measurements have been performed (58).

Schiff *et al.* included 5 patients (6 eyes) who were either pseudophakic or aphakic, showed an increased postoperative visual acuity in all patients with no surgical complications (46). Assessing the quality of life with NEI VFQ showed positive impact in different measures (3,33). Delaney *et al.* presented a positive outcome in 15 patients (11 out of whom had been unsuccessfully treated with Nd:Yag laser), when using vitrectomy in these patients stated a complete resolution of symptoms in 14 patients was found (5). Schulz-Key *et al.* evaluated long-term results of pars plana vitrectomy for floaters in 73 cases with an average follow-up of 37 months using a questionnaire. Patient satisfaction was found in 88% of patients (37). Tan *et al.* analyzed the safety of vitrectomy by measuring the incidence of iatrogenic retinal breaks in all 116 patients, found in 16.4% of operations. 2.5 % of the patients were affected with post-vitrectomy retinal detachments (59). Across different study surveys, results showed a positive outcome on quality of life ranging from 85 to 100% (40). Sebag *et al.* published a prospective study on pars plana vitrectomy (PPV) performed in 76 eyes. Patients without PVD were induced with floaters-only-vitrectomy (FOV) stating that this theoretically would decrease the risk of iatrogenic retinal breaks by leaving anterior vitreous in situ to protect the lens against free oxygen radicals and reduce the post-surgery cataract development. It was concluded that with this technique contrast sensitivity was normalized in all cases up to 9 months postoperatively, with no case of post-PPV retinal breaks or retinal detachment (60).

Among these different research articles with 630 cases reviewed by Milston *et al.* a range of different complications were reported. The most common complication is the development of cataracts (3). Occuring in 53 to 76 % of cases, depending on pathology and systemic conditions, the studies have shown risk of cataract development within 2 years in patients over 50 years of age (63). However, with use of FOV with anterior vitreous sparing

reported a rate of cataract development being 23.5% (over 15 months) and 22.5 % (over 18 months) (3,33,40,61–63). Endophthalmitis is a potential complication ranging from 0.018-0.04 % in postsurgical cases. Retinal breaks varied between 0-16.4%, more commonly reported in studies with longer follow-up periods (3). The induction of PVD during surgery in non-symptomatic patients would often aggravate PVD during the vitrectomy. One common complication of PPV are changes in intraocular pressure which may lead to either hypo- or hypertension, the latter being more common (61).

1.13.2. Pharmacologic vitreolysis

Nonsurgical therapy has been under development, so far seven agents have been explored in 5 clinical studies that either failed or were stopped. Clinical trials of ocriplasmin, now being approved by FDA (US Food and Drug Administration), have shown safety and efficacy for symptomatic vitreomacular adhesion and traction. EUEMA (European Union European Medicines Agency) have approved using ocriplasmin for treating vitreomacular traction and macular holes (3). Theoretical concerns have been towards effects on zonules and photoreceptors. However, it has not been showed in clinical trials in patients receiving pharmacological treatment (62). Studies which carefully monitor the effects of pharmacologic vitreolysis are important due to the nature of the agent. Though, theoretical consideration and even clinical evidence have implicated that pharmacological treatment might rather than suspend floaters, induce them (62). In large multicenter clinical trials, the incidence of floaters in patients treated with ocriplasmin was twice as high as in controls (63).

1.13.3. Neodymium-doped yttrium aluminum garnet laser vitreolysis

Today neodymium-doped yttrium aluminum garnet (Nd:YAG) lasers are mostly used in treatment of posterior capsule and anterior vitreous membrane opacification. Recent clinical trials have developed a system called Reflex (Ultra Q Reflex laser) which allows coaxial lightning (light source positioned on same optical axis of slit-lamp microscope and laser beam) (64). Vitreous floaters are dissolved by focusing the laser together with a slit lamp showing the opacities. The main target of Nd:YAG laser is to reduce the mass of collagen fibril aggregates, disintegrating it down to small fragments which theoretically allows them to be displaced from the visual axis.(65). YAG laser achieves disruption by a high frequency electromagnetic field with a temperature of more than 4000°C creating plasma causing shock waves converting vitreous floaters into gas form. It has been defined as a treatment option for opacities found

further away from the retina. Unlike PPV, Nd:YAG laser is focusing on collagenous opacities minimally affecting the hyaluronan (3).

1.13.3.1. Treatment steps

In pre-treatment phase, importance is stressed in appropriate explanation of procedure and risks to the patient. The pupil should be fully dilated at eye examination with attention to retina and periphery. Recommendation for extending size of the pupil is to combine both tropicamide and phenylephrine. The topical anesthetic should be put with 2-3 instillations a few minutes apart. The Nd:Yag laser is fixated with a treatment spot size at 8 micrometers and pulse width of 4ns with fluctuating energy and number of pulses fired in one shot. The offset of the treatment laser beam in respect to the aiming beam can also be set anterior through to posterior. Prior to the treatment it is preferable to explain to the patient the sound of a shutter opening with every shot which occur after the doctor place the contact lens on the patient's cornea. The energy needed to perform vitreolysis requires high levels, having to pass through more optical media than during capsulotomy therapy. It is advocated to start with a low level of energy, titrating up to adequate vaporization levels causing collagen breakdown of vitreous opacities. According to Gerbrandy *et al.* the minimum level required to create this dissolution of vitreous opacities is theoretically around 2-2.5 mJ. Though, most treatments are performed at an energy quantity of 2.5-4.5 mJ depending on depth of vitreous floater (31). Pulses can be increased to double or triple per shot, which should be done before increasing the energy. Recommendation is to limit the number of shots per treatment to a maximum of 500. Obtaining a clear view is of uttermost importance as accidental shots to the lens or retina may occur if the aiming beams are not coincidental or superimposed. The adequate distance from the lens should be more than 2-4 mm from the retina considering a wide safety margin. Bonner *et al.* revealed that energies ranging from 2 to 6 mJ safely cause vitreolysis (in rabbits) if the membranes are at least 2 mm from retina (3,31). During the treatment the vitreous floaters may be moving due to shock waves from each shot fired. Advisable guidelines commence to treat anterior vitreous floaters first proceeding inwards, enabling the doctor to remove opacities that may impede vision of posterior structures. Likewise, treatment should start from superior to inferior as gas bubbles may occlude vision if inferior ones are treated first. Avoiding Nd:YAG laser in the direction of the macula is of superior importance. Post-treatment medications are usually not necessary. In rare cases inflammation of the anterior segment has been observed which was treated with non-steroidal anti-inflammatories. According to previous experience there are no restrictions on patient activities. They may see small, dark specks in their lower

visual field 15-30 minutes following the procedure. Patient cannot adequately evaluate the treatment outcome until constriction of pupils (64).

1.13.3.2. Efficacy

There have been several published studies claiming efficacy of Nd:YAG laser vitreolysis. However, only a few case reports are available. Due to highly variable design, treatment protocols, small sample size, assessing the outcome and success subjectively, not using standardized questionnaires, efficacy majorly rely on self-reporting. Milston argues that there were no objective outcome measures of neither vision nor vitreous structure in any of the studies (3). By using subjective measurements, the success rates were highly variable, ranging from 0 to 100%. The number of required sessions ranged between one and six (3). However, in a study performed by Shaimova *et al.* which included 144 patients (173 eyes) assessing the effectiveness of treatment where by using a patient questionnaire, basing objective data on SLO, OCT angiography and photo-registration. They stated that objective quantitative assessment, being highly significant for clinical purposes of dynamic observation would optimize indications for treatment and assess Nd:YAG laser vitreolysis effectiveness (40).

The original study on Nd:YAG laser vitreolysis in 1993 by Tsai *et al.* (3,5,67) stated no complications reported at post-interventional month 12 and complete resolution of symptoms in all 15 patient. The treated vitreous opacities in this study were located centrally and less than 3, with a minimal distance from the retina being 4 mm (67). Treatment modality and tool were an ophthalmoscope and a flat fundus lens of the Goldmann three-mirror lens, power set 5-10 mJ with one pulse per shot. The total energy depended on the size and varied from 71-742 mJ (40). Little *et al.* reported the use of Nd:YAG laser in 25 eyes with symptomatic vitreous opacities being effective in only 14 eyes using energy levels up to 15 mJ (66). Delaney *et al.* concluded that Nd:YAG laser relieved symptoms in one third of patients and a clinical improvement (only moderately graded) was assessed as 50% by 93.3 % of patients (5). However, in their study a maximum pulse energy of 1.2 mJ was used. At this low power levels, the vitreous collagen bundles are fractioned but not vaporized. (67). Vandorselaer *et al.* state that success directly correlate with type of floater and its suspension characteristics (68). Shah *et al.* publicized their study in 2017, containing 52 patients (52 eyes) with a maximum energy amount of 7 mJ, initially starting at levels of 3 mJ. They concluded a 53% significant or complete resolution at postoperative month 6 (69). Luo *et al.* conducted a study based on 30 patients (30 eyes) with an energy delivery of 1.5-2mJ per shot at beginning with gradually increased power up to 7 mJ. They recorded a 75 % “significant success” and a “partial

success” of 25 % with no postsurgical complications at month 6. Luo claims that the advantages of Nd:YAG laser were non-invasive, low cost, short duration with immediate effect and lesser risk of complications (70).

1.13.3.3 Safety and Risks with Procedure

When Nd:YAG laser achieves disruption and evaporation causing shock waves, these may not only disrupt opacities but also cause damage to the adjacent lens and retina. This depends on laser energy used and distance of the focal point (71).

Milston *et al.* reviewed that a minimal complication rate was reported with only one case of uveitis and transient increase IOP across all studies. She further claimed that studies had shown complications raised when Nd:YAG laser were used within 2-4 mm from the retina or lens, at high energy levels (3). Ivanova *et al.* discuss multiple studies reporting complications in all patients (post-surgical month 12) after using Nd:YAG laser including; cataract formation, retinal and choroidal haemorrhage, retinal breaks and damage to retinal pigment epithelium (31). Shah and Heir reported rare complications after postsurgical month 6. However, they stated that because sufficient data was not provided, Nd:YAG vitreolysis could not be concluded as a safe procedure (40).

Lim discussed that their rare complication rate cannot be generalized. Using an energy level of 7 mJ. (71) The study by Little *et al.* using 15 mJ concluding complications consisting of retinal hemorrhages, lens damage and retinal tears with retinal detachment (66). Hahn *et al.* reported a brief report assessing voluntary reports to the American Society of Retina Specialists during a six-month period in 2016-2017 describing complications in 15 patients similar to those found in the study by Little *et al.* study (66,72). Delaney *et al.* claimed a worsening of symptoms in 7.7% of their patients using an energy level of 1.5 mJ however, they did not conclude any post-surgical complications (5,31). Stein discussed that the most common cause of injury is directly correlated to both power of energy of laser as the proximity of injury. He further claims that experiments in eyes of humans and animals have shown harmful consequences of the retina and choroid haemorrhage at energy levels between 1-3 mJ (73). O'Day *et al.* published an article in 2018 describing a case of bilateral cataracts with posterior capsule defects caused by Nd:YAG laser vitreolysis (74).

Cowan *et al.* reported three cases of refractory open-angle glaucoma after Nd:YAG laser vitreolysis (75). There were no immediate complications as seen in some patients with transient increase in intraocular pressure (IOP), returning to normal levels after 5-7 days with

use of acetazolamide and timolol in majority of cases. No associated inflammation, steroid use or other identifiable origin was proved to cause chronic IOP. Cowan *et al* hypothesized that chronic increase in IOP is attributable to delayed migration of vitreous micro-debris into the anterior chamber angle, alternatively macrophage laden blocking trabecular meshwork or shockwave damage to the trabecular endothelial cells (75).

1.13.3.4 Prognosis

Kokavec *et al.* constituted a systematic review in 2017, trying to evaluate and compare effectiveness between Nd:YAG laser vitreolysis and PPV identifying 338 records (57). However, after duplications, removing irrelevant references, screening the remaining articles they concluded that they could not find any randomized control trial (RCT) or quasi-RCT that met their inclusion criteria. RCTs offer the ability to make causal inferences, providing strongest proof for a treatments effectiveness. They concluded that there was no strong evidence to recommend Nd:YAG laser vitreolysis over PPV (or vice versa) for treatment of symptomatic floaters. Kokavec *et al.* indicate that further evaluation must be done, longer follow-ups, standardized questionnaires and requirements of standardized thresholds of change. This would improve measurments of the outcomes (57). Nd:YAG laser vitreolysis is considered an alternative technique that can offer treatment of symptomatic vitreous floaters, expanding its use (75).

2. OBJECTIVES

Aims

1. Assess the benefits of treating vitreous floaters in symptomatic patients with Nd:YAG laser vitreolysis determined by a vision-related quality of life questionnaire, pre- and postoperatively.
2. Assess the efficacy of using Nd:YAG laser vitreolysis in SVO.
3. Assess the safety of using Nd:YAG laser vitreolysis in SVO.

Hypothesis

- 1). Based on vision-related life-quality questionnaire, treating SVO with Nd:YAG laser vitreolysis will improve quality of life in patients.
- 2). Nd:YAG laser vitreolysis is a safe and effective treatment in patients with vitreous floaters.

3.MATERIALS AND METHODS

3.1. Ethical background and data collection

All data used for this thesis was gathered at the Ophthalmology department of University Hospital of Split, and was approved by the Ethics Committee of University Hospital of Split. The study adhered to the doctrines outlined in the Declaration of Helsinki and a written informed consent was obtained from all study participants.

3.2. Study purpose

Currently, there is insufficient evidence in literature for the optional treatment of vitreous floaters with Nd:YAG laser vitreolysis. The variability of outcomes and complications with the majority of research articles, being retrospective makes it difficult to predict the effectiveness and safety of Nd:Yag laser vitreolysis in patients with vitreous floaters.

Patients with symptomatic vitreous floaters are most commonly treated conservatively. Today, one of the major optional interventions for highly symptomatic patients with persisting vitreous floaters impacting their quality of life is Nd:YAG laser vitreolysis. The purpose of this study is to assess Nd:YAG laser vitreolysis by measuring its outcome using a vision-related quality of life questionnaire.

3.3. Participant recruitment

Between April 2, 2019, and May 21, 2019 participants were recruited by medical doctors at the Ophthalmology Department, Split University Hospital. Patients with symptomatic vitreous floaters with a strong desire for treatment and who agreed to participate in this study were consecutively enrolled. On the account of previous studies, decision was made to conduct a prospective study of patients who received Nd:YAG laser vitreolysis as treatment for symptomatic vitreous floaters.

A total of 10 eyes from 10 patients (4 men, 6 women) were diagnosed with symptomatic vitreous floaters. Participants age was ranging from 45-77 years with an average patient age of 68.5 years.

3.4 Inclusion and Exclusion Criteria

In this study we included patients with clinical symptoms of vitreous floaters above the age of 18 years that were able to give a written informed consent to the procedure. They were clinically diagnosed with either symptomatic vitreous floaters or posterior vitreous detachment. Participants who were unable to undertake the procedure, had an obscured anterior segment of the eye, blurring of the natural lens or artificial lens and an indistinct posterior ocular segment

were excluded. Other exclusion criteria were: existing eye inflammations, adherence of opacities to the iris, uncontrolled elevation of the intraocular pressure and degenerative pathologies of the peripheral retina.

3.5 Vitreous Floaters Symptom Questionnaire

On the basis of findings, there is no standardized vision-related quality of life questionnaire for symptomatic vitreous floaters. In our study we constructed our own questionnaire that was partially based on Kim *et al.* (48) study to better evaluate clinical significance of symptomatic floaters.

Our examination was based on pre-and post-interventional questionnaires. In the first questionnaire, the primary part assessed general health, frequency of visitations to the ophthalmologist, previous surgeries, other ocular pathologies, interference associated with daily activities, frequency of disturbance (based on a visual disturbance scale), morphology and characteristics of the vitreous opacities (Figures 5 and 6). The immediate post-interventional or secondary part of the first questionnaire was to evaluate the response and approval of Nd:YAG laser vitreolysis procedure (Figure 6). The second questionnaire consisted of questions relating to change in vision-related quality of life to assess efficacy and safety of treatment (Figure 7).

Name and Surname: _____

OIB: _____

Eye (encircle your answer): Right Left Both

1. General health:

1/ Generally, you would say that your overall health is: (encircle your answer)

1. Excellent
2. Very Good
3. Good
4. Bad

2/ How often do you go to your ophthalmologist? (encircle your answer)

1. Never
2. Less frequently (1 x in 2 years)
3. Frequently (1 x 1 year)

3/ Do you use reading glasses? (encircle your answer)

1) Yes 2) No

4/ Have you had any previous eye surgeries? (encircle your answer)

1) Yes 2) No

4.1/ If yes, which one? (encircle your answer)

1. Cataract surgery
2. Glaucoma surgery
3. Other, _____

5/ Do you have any other eye pathologies? (encircle the answer) 1) Yes 2) No

5.1/ If YES, which one(s)? (Write it down)

6/ For how long have you noticed vitreous floaters? (encircle your answer)

1. ≤ 1 Month
2. 1 Month - 6 months
3. 6 months - 1 year
4. ≥ 1 year

7/ Are you experiencing interference during work? (encircle your answer)

1. No

2. Yes, mildly - I feel minor discomfort during work. But, it **doesn't** interfere with my work

3. Yes, modest - I feel moderate discomfort

4. Yes, severely - I have severe interference and discomfort.

7.1/ If yes, How often do you feel the problems daily? (encircle your answer)

1. ≤ 1 time
2. 2-3 times
3. 4-9 times
4. ≥ 10 times

8/ Do you have any problems while performing these activities? (encircle your answer)

1. - Driving: 1. Yes 2. No.
2. - Reading: 1. Yes 2. No.
3. - Computer / TV: 1. Yes 2. No.
4. When undertaking near-sight work? (i.e. cooking, sewing or using a hand tool) 1. Yes 2. No.

9/ Choose the picture that best represents the symptoms you are experiencing on a daily basis: (encircle your answer)

The grid contains 16 small images labeled A through P. Each image depicts a different visual symptom or disturbance, such as floaters, halos, blurring, or other optical effects. The labels are: A, B, C, D, E, F, G, H, I, J, K, L, M, N, O, P.

10/ On a scale of 1-10 how much does vitreous floaters cause disturbances? (0 none - 10 worst disturbance) (encircle the number)

Figure 5. Pre-interventional questionnaire.

0 1 2 3 4 5 6 7 8 9 10

No Disturbance Moderate disturbance Worst possible disturbance

11) Do you perceive any flashing lights? (encircle your answer) 1) Yes 2) No

11.1) If YES, how often do you perceive them during the day?

1. ≤ 1
2. 2-3
3. 4-9
4. ≥ 10

12) Do the vitreous floaters move? (encircle your answer) 1) Yes 2) No

13) Do the vitreous floaters follow your eye movement? (encircle your answer) 1) Yes 2) No

14) Are the vitreous floaters more pronounced in bright light? (encircle your answer)
1) Yes 2) No

14.1) If YES, Do you have to use sunglasses? (encircle your answer) 1) Yes 2) No

SECOND PART: Immediately after intervention

1) How uncomfortable was the procedure? (encircle your answer)

1. Not at all
2. A little bit
3. Very

2) Did you feel any pain/ flashing/ visual disturbance during the procedure? (encircle your answer) 1) Yes 2) No

2.1) If YES, Which disturbance? (Write it down)

Figure 6. Pre-interventional and immediate post-interventional questionnaire.

Name and Surname: _____

OIB: _____

Eye (encircle your answer): Right Left Both

Post-operative Questionnaire:

1 Did the disturbance of vitreous floaters change after surgery? (encircle your answer)

1. I feel an improvement

2. I feel worse

3. I feel no change

2 How much did quality of life improve after the intervention? (encircle your answer)

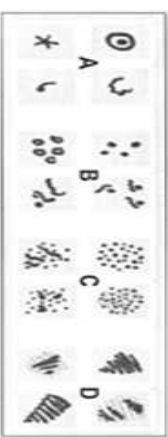
1. Not at all

2. A little bit

3. Moderately

4. A lot

3 Choose the picture that best represents the symptoms you are experiencing on a daily basis; (encircle your answer)



4 On a scale of 1-10 how much does vitreous floaters cause disturbances? (0 none - 10 worst disturbance) (encircle the number)

No	0	1	2	3	4	5	6	7	8	9	10	Worst possible disturbance
----	---	---	---	---	---	---	---	---	---	---	----	----------------------------

5 Do you have any problems while performing following activities: (encircle your answer)

1. - Driving: 1. Yes 2. No.

2. - Reading: 1. Yes 2. No.

3. - Computer / TV: 1. Yes 2. No.

4. When undertaking near-sight work? (i.e. cooking, sewing or using a hand tool)

1. Yes 2. No.

6 Do you feel any difficulties after the procedure? (encircle the answer) 1) Yes 2) No

6.1 If YES. Which: _____

7 Are you satisfied with the intervention? (encircle your answer)

1. Yes. I cannot see the vitreous floaters anymore.

2. Yes. The vitreous floaters do not disturb me.

3. No. I feel no difference.

4. No. I feel worsening of the symptoms.

Figure 7. Post-interventional questionnaire used in week 1 and month 1.

3.6 Ophthalmologic examination and posterior vitreous detachment evaluation

All patients with symptomatic floaters went through a complete ophthalmological examination. Best-corrected visual acuity (BCVA) was measured using a Snellen chart. Anterior segment analysis was performed on a slit lamp to exclude any inflammation or haziness. Natural lens or intraocular lens clarity was noted. Intraocular pressure using applanation tonometry was measured to exclude glaucoma. A posterior segment analysis through a dilated pupil using a 90D Volk SuperField NC lens was performed to exclude any degenerations of the posterior segment and during that examination if a posterior vitreous detachment would be observed it would be evaluated.

3.7 Intervention

Prior to the procedure, the patient's eyes were dilated with 1% Tropicamide and 2% Phenylephrine given with topical local anesthetic 0.4% Oxybupicaine hydrochlorid. The participants were positioned with a chin strap to the vitreous laser. Vitreolysis treatment was performed by the same ophthalmologist (L.Z) applying Nd:YAG laser ALCON 3000 LE Ophthalmic Laser version 3.2. Optical contact lens, panfundoscope Volk Quadr-Aspheric indirect laser treatment lens was appointed with methyl-cellulose on the corneal surface. The laser beam, being focused on the determined opacities start with an initial energy level of 3 mJ. Direct effect will adjust the laser beam power to achieve the desired result. Post-interventional a single dose of 1 % Dexamethasone is given, supported by an ocular bandage.

3.8 Types of outcome measures

Primary outcome measure

- Using a pre- and post-interventional questionnaire to determine changes in vision-related quality of life from baseline up to 1 month.
- Safety and efficacy of using Nd:YAG laser vitreolysis

Secondary outcomes

- Central Subfield Thickness
- Changes in visual acuity and intra ocular pressure

Adverse outcomes

- The occurrence of complications causing changes correlated to decreased vision or structure of the eye immediately after treatment, 1 week and 1 month, post-interventional.

- Potential Macular Edema
- Asymptomatic retinal tears
- Symptomatic retinal tears
- Retinal detachment
- Cataract formation
- Endophthalmitis

3.9 Statistical methods

Statistical analysis was performed using the statistical software Statistica 10 (StatSoft Inc., Tulsa, OK, USA). A questionnaire was used to assess time effect within participants and result trends over time, assessing both time effect and trend covering all three time frames.

Due to smaller sample size, nonparametric tests were used. Wilcoxon matched pair test was used to assess significant findings, detecting differentiation in the time frame. The test of trend was to determine whether the outcome followed a consistent trend over time by evaluating the means of each time frame. The statistical significance was set at $P < 0.05$.

4. RESULTS

A prospective cohort of 10 eyes in 10 patients (4 men and 6 women) were included in the study. The average age of the patients was 68 years (median, 95 % Confidence Interval 62.3 to 74.1), ranging from 45-77 years. The average of pre-interventional Best Spectacle-Corrected Visual Acuity (BCVA) was 0.68 (median, 95% Confidence Interval 0.50 to 0.91). The right eye was treated in 7 cases with an average number of laser spots being 158 (median, 95% CI ranging from 73.2 to 281.0). The average energy used, measured in mJ, was 5.075.

Day of treatment and follow-up time was divided into 3 physician visits, plotted using a pre, and immediately post-interventional questionnaire, and a 7 days' post-interventional questionnaire. The same post-interventional questionnaire was used in the second follow-up visit which was appointed 1 month after. The results of the pre interventional questionnaire are presented in Table 1.

Variable (pre- interventional).		N (proportion).
General Health	Excellent	1 (0.1).
	Very good	3 (0.3).
	Good	6 (0.6).
	Bad	0 (0.0).
Ophthalmologist visitation	Never	1 (0.1).
	Once in two years	5 (0.5).
	Once yearly	4 (0.4).
Use of reading glasses	Yes	10 (1.0).
Previous operations on the eye	Yes	4 (0.4).
	No	6 (0.6).
Type of previous operation	Cataract	2 (0.2).
	Retinal Detachment	2 (0.2).
Other eye pathologies	No	10 (1.0).
Diagnosis	Posterior Vitreous Detachment	10 (1.0).
Length of symptomatology	1 month – 6 months	3 (0.3).
	6 months – 1 year	2 (0.2).
	>1 year	5 (0.5).
Disturbance during daily activity	No disturbance	2 (0.2).
	Mild disturbance	3 (0.3).
	Moderate disturbance	3 (0.3).
	Severe disturbance	2 (0.2).
Frequency of disturbance/day	<1	2 (0.25).
	2-3	2 (0.25).
	4-9	1 (0.125).
	>10	3 (0.375).
Type of vitreous floater	Picture 1	5 (0.5).
	Picture 2	2 (0.2).
	Picture 3	3 (0.3).

	Picture 4	0 (0.0).
Flashing sensation	Yes	3 (0.3).
	No	7 (0.7).
Frequency of flashings	<1	1 (0.33).
	2-3	2 (0.66).
	4-9	0 (0.0).
	>10	0 (0.0).
Movement of vitreous floaters	Yes	10 (1.0).
Movement of vitreous floaters with movement of the eye(s).	Yes	10 (1.0).
Are the vitreous floaters more symptomatic in bright light	Yes	5 (0.5).
	No	5 (0.5).
If yes, does the patient need sunglasses?	Yes	3 (0.6).
	No	2 (0.4).

Table 1. Pre-interventional questionnaire.

Results obtained from the first questionnaire immediately after the intervention are presented in Table 2.

Variable (Immediately post-interventional).		N(proportion).
Unpleasantness of intervention	No	10 (1.0).
Feeling of pain/flashing/disturbance during intervention.	No	9 (0.9).
	Yes	1(0.1). - disturbance

Table 2. Immediate post-interventional questionnaire

In Table 3 results obtained a week and a month after the intervention are shown. Out of 10 participants, all but one was followed up 1 month after. This patient was unable to visit scheduled examination. Majority of the participants experienced a decline in symptoms. No one of patients suffered from post interventional difficulties. However, two participants complained on the adverse effects, one for choroid haemorrhage and one for retinal hit. Out of three patients with complete resolution of symptoms, before intervention two participants visualized floater category found in picture 1 (total laser energy of 369 mJ and 1925 mJ, respectively) whilst the third patient saw vitreous floaters found in picture 3 (total laser energy of 453 mJ).

Variable (Post-interventional).		N (proportion) 1 week	N (proportion) 1 month	P-value
Change of symptomatology after intervention	Yes, decrease of symptoms	9 (0.9).	9 (1.0).	Cannot be correlated
	No change in symptomatology	1 (0.1).	0 (0.0).	
Improved quality of life after intervention	Not at all	1 (0.1).	0 (0.0).	P = 0.8125
	Mildly improved	4 (0.4).	4 (0.44).	
	Moderately improved	1 (0.1).	2(0.22).	
	Much improved	4 (0.4).	3(0.22).	
Type of vitreous floater found after intervention	Picture 1	6 (0.6).	2 (0.22).	P = 0.1250
	Picture 2	1 (0.1).	3 (0.33).	
	Picture 3	3 (0.3).	1 (0.11).	
	No vitreous found	0 (0.0).	3 (0.33).	
Difficulties post-interventional	No	10 (1.0).	9 (1.0).	Cannot estimate P (small sample size).
Satisfaction with Nd:YAG laser vitreolysis	Yes, no symptomatology of vitreous floaters	1 (0.1).	1 (0.11).	P = 0.8125
	Yes, markedly decreased symptomatology of vitreous floaters	4 (0.4).	1 (0.11).	
	Yes, mildly decreased symptomatology of vitreous floaters	2 (0.2).	7 (0.77).	
	No, no change of symptomatology of vitreous floaters	1 (0.1).	0 (0.0).	
	No, worsening of symptomatology of vitreous floaters	2 (0.2).	0 (0.0).	

Table 3. Post-interventional questionnaires after 1 week and 1 month, respectively.

The correlating variables (included in both pre and post intervention questionnaires) were disturbance and improvement in: driving, reading, watching TV/computer and undertaking near-sight work. Comparison of these variables are presented in Figures 8 and 9. The statistically significant difference was observed in driving disturbance symptoms after 1 week ($P=0.031$).

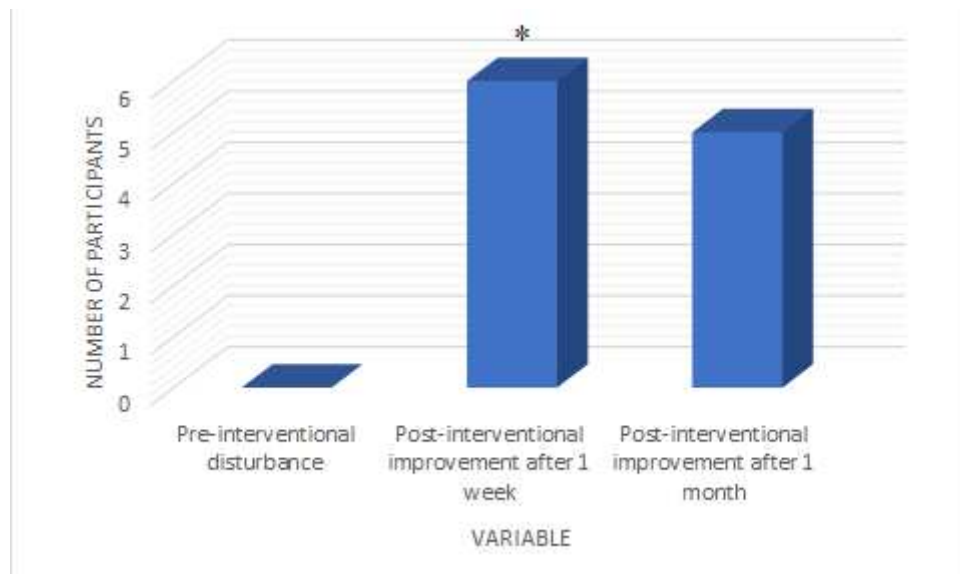


Figure 8. Comparison between pre-interventional driving disturbance and improvement in symptoms after 1 week and 1 month, respectively.

* Wilcoxon test $P=0.031$

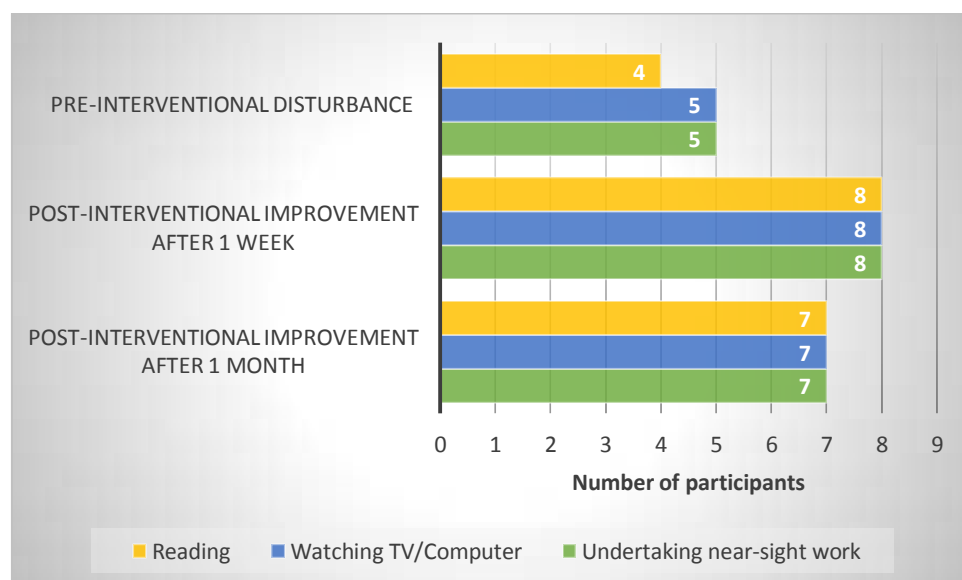


Figure 9. Comparison between pre-interventional symptom disturbances whilst reading, watching TV/Computer, undertaking near-sight work and improvement in these activities after post-interventional week 1 and month 1, respectively.

Difference between Best Spectacle-Corrected Visual Acuity (BCVA) before and after treatment are depicted in (Figure 10). Post-interventional, in 4 patients the BCVA increased, 3 patients had equal BCVA whilst 3 patients had decreased BCVA.

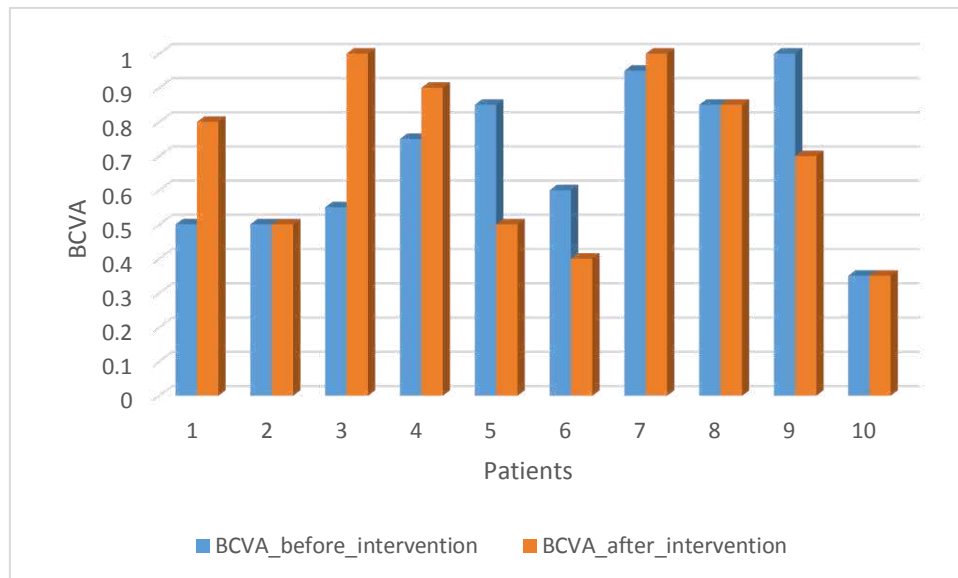


Figure 10. Comparison between BCVA before and after intervention.

- Wilcoxon test $P = 0.9375$

Difference in the Intra Ocular pressure (IOP) before and after intervention is depicted in (Figure 11). Out of 10 patients; 3 had a decrease in IOP, 2 had equal IOP and 5 had an increased IOP post-interventional.

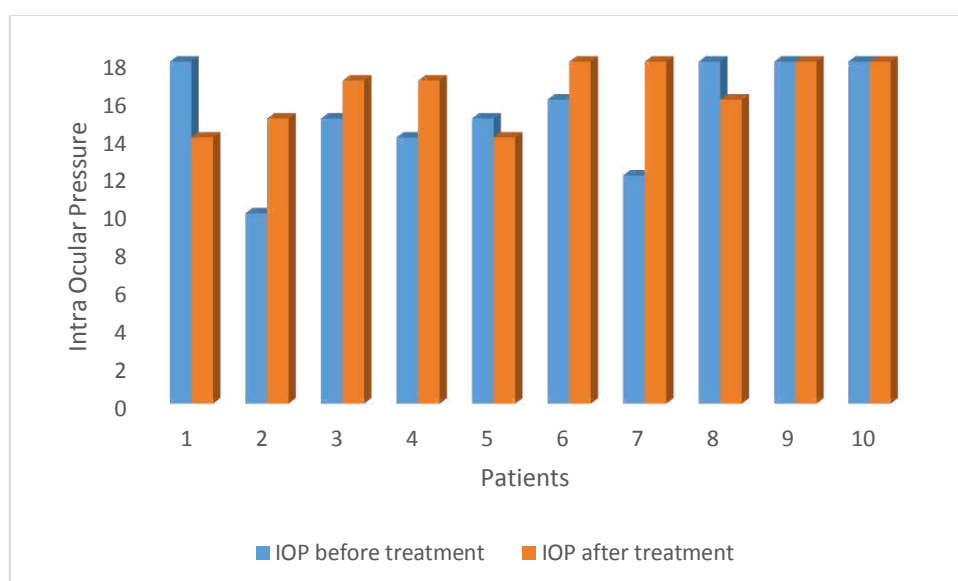


Figure 11. Change in Intra Ocular Pressure (IOP). pre- and post-interventional.

Difference between pre- and post-interventional visual disturbance grade was correlated with total laser energy (Figure 12). Energy levels varied between 3-8 mJ with number of laser spots ranging between 36-333. No significant correlation was found with the intensity level and decrease in visual disturbance scale (Spearman correlation $\rho = 0.06$, 95% CI -0.59 to 0.68). However, the visual disturbance scale before the surgery was 4.0 (95% CI from 0.0 to 8.05) on a scale from 0 to 10 and after the intervention the median relief of the initial symptoms was 45% (95% CI from 25.0% to 50.0%).

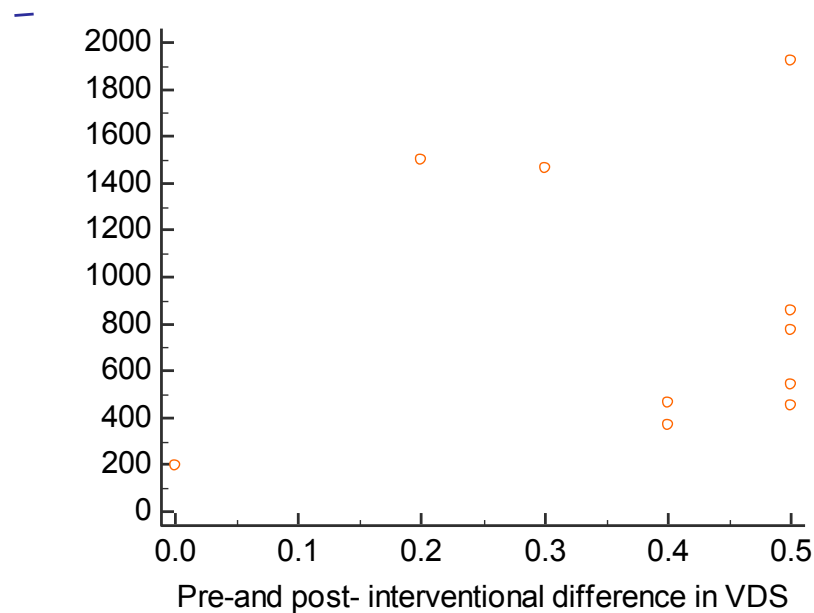


Figure 12. Total laser energy used in comparison to difference in postoperative and preoperative visual disturbance scale.

Total laser energy used in comparison with change in quality of life in post-interventional questionnaire after 1 week and 1 month are shown in (Figures 13 and 14). The influence of total laser energy on patients' quality of life was examined. However, no statistically significant correlation was observed, probably due to the small number of the study participants (Figure 13 and Figure 14).

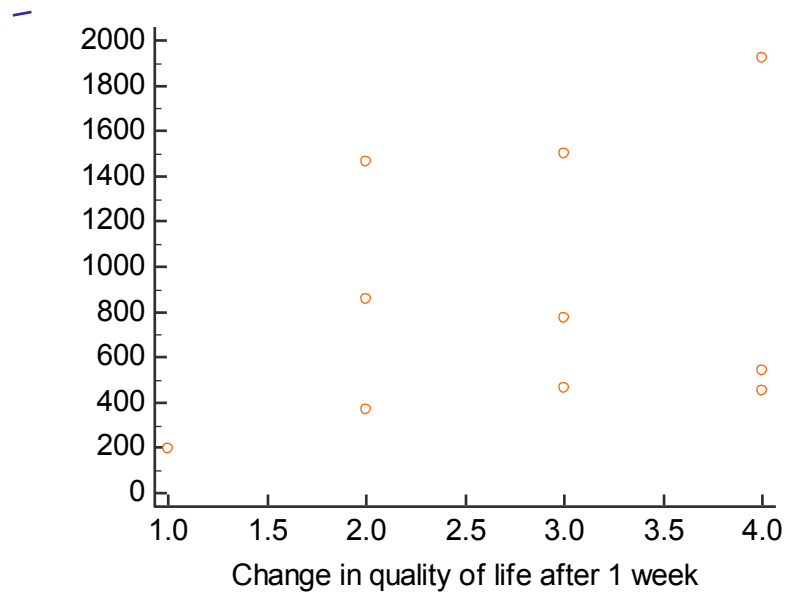


Figure 13. Total laser energy in comparison to change in quality of life in patients after 1 week.

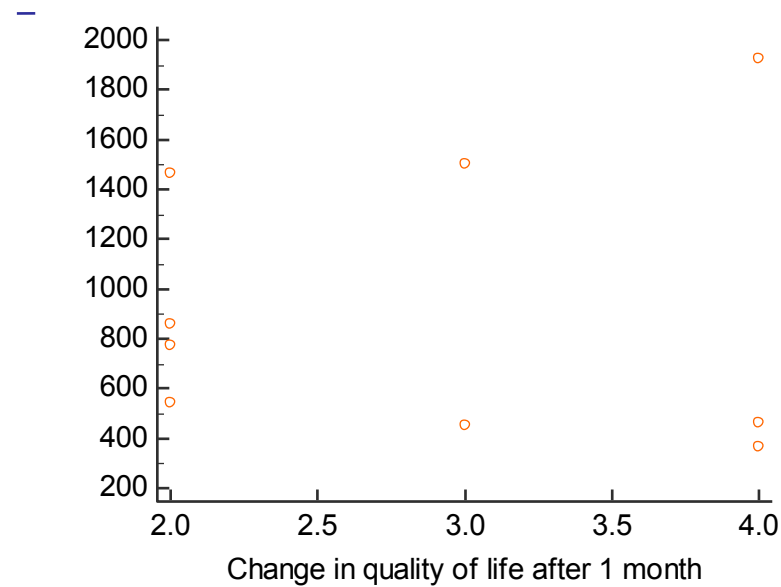


Figure 14. Total laser energy in comparison to change in quality of life in patients after 1 month.

Total laser energy in comparison to visual improvement after 1 week respectively 1 month is depicted in (Figures 15 and 16). Visual improvement was defined as a decrease in symptoms on the visual disturbance scale, pre- and post-interventional.

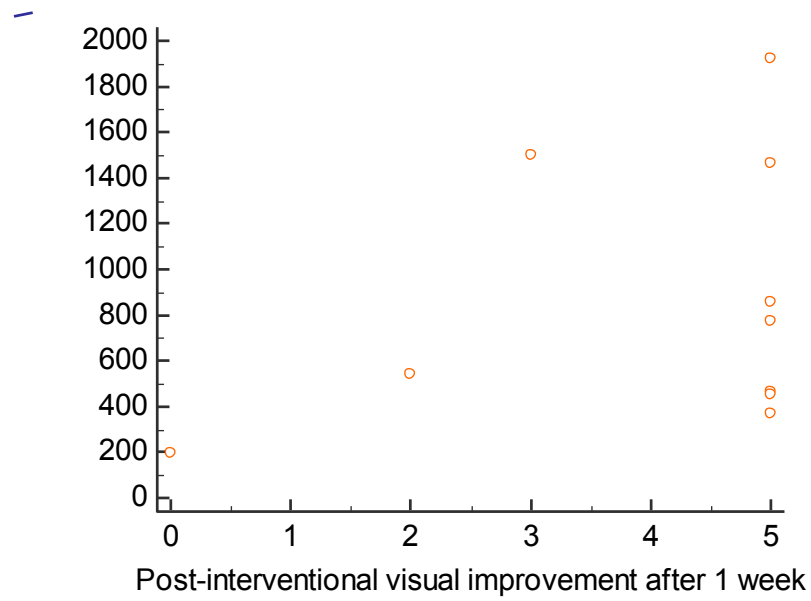


Figure 15. Total laser energy compared to visual improvement after 1 week.

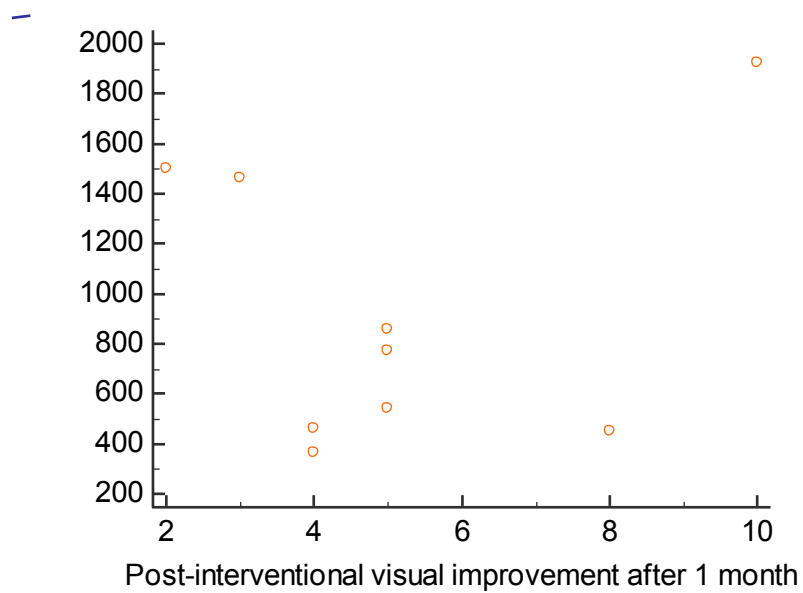


Figure 16. Total laser energy compared to visual improvement after 1 month.

5. DISCUSSION

Aging of the eye leads to a sequel of the events in the vitreous humor, one of the most common outcomes being vitreous floaters. This disturbance is found in 3.1/100.000 people per year. Liquefactions starts early in life. However, only in a minimal proportion of the population, clinical significance of vitreous floaters mostly developed later in life. It is determined mainly by underlying diseases or subjective symptomatology. In most cases preliminary symptoms are not bothersome. Nevertheless, in significant amount of cases they have a noteworthy impact on the patient's life.

The current study has shown a decrease in floater symptomatology with one laser session by post-interventional period week 1 and month 1, respectively. Described as the most common etiology to vitreous floaters, posterior vitreous detachment was diagnosed in all 10 patients, otherwise subjectively describing a general health of good or better. Many patients claim to experience floater symptoms, often being uncomplicated. As vitreous floaters are most commonly thought to be harmless, minimal attention is placed on the patients' discomfort and seriousness of pathology development with permanent consequences on vision and ocular anatomy. Most patients are treated conservatively, mainly consisting of education and reassurance. As shown in our results 50 % of the participants described the length of symptoms to be more than 1 year, 37.5% complaining of a disturbance rate of more than 10 times per day pointing out low awareness of frequent interference in patients with vitreous floaters. Previous studies have claimed that prevalence of vitreous floaters is increased with age, axial length and have been reported to be more common subsequent to cataract surgery. The average age of participants in this prospective study was 68 years, all of them using reading glasses. Four patients had either cataract or retinal detachment surgery previous to vitreous floaters. These features increase the risk of both developing and easier detect opacities disturbing their vision.

There are no clear universal guidelines to neither treatment nor categorization of vitreous floaters making it a complicated problem for symptomatic patients. Few studies have been made as to compare whether Nd:YAG laser vitreolysis or pars plana vitrectomy should be used as primary treatment. Tassignon *et al.* designed a classification system which would be a good primary way of establishing vitreous floaters into different subgroups. Recommendations suggest that site of treatment should be confined to the anterior vitreous where total energy of 1.5-7 mJ is well tolerated with no associated complications up to 6 months. In our one-session treatment of vitreous floaters with Nd:YAG laser vitreolysis, we did not confine a specific area of the vitreous with our intensity of energy extending between 3-8 mJ and number of laser spots ranging between 36-333. Even though our study overrides

recommended total energy to minimize difficulties, multiple studies have been using equal or higher intensity extending from 5-33 mJ (3,31,40,70,72). Our immediate post-interventional response showed no unpleasantness of intervention with only one patient (10%) complaining on the feeling of disturbance. 20% (2 participants) suffered from post-interventional adverse effects; one evolved choroid haemorrhage whilst the other experienced a retinal hit, although these findings were not significant to affect vision or structure of the eye. In our post-interventional questionnaire which compared difficulties after both one week and one month, 100% of the patients did not perceive any difficulties with vision or ocular function. Other studies have described safety of Nd:YAG vitreolysis to range from no complications to multiple studies reporting complications in all patients in post-interventional month 12 (3). The efficacy of Nd:YAG laser vitreolysis was measured by our post-interventional questionnaire showing a 90% decrease in symptoms in post-interventional week 1 and a 100% decrease in post-interventional month 1.

When it comes to improved quality of life, 4 participants stated a markedly improvement in reduction of symptoms after one week whilst after one month only 3 participants claimed an improvement. Only one patient stated no improvement at all after 1 week. However, in our second follow up all patients listed improvement. Correlating total laser energy with change in quality of life after second follow up, no observation showing a statistical significant correlation. Presumably due to a small participant size. When responding to satisfaction with Nd:YAG laser treatment 3 candidates expressed disappointment, out of which 2 stated worsening of symptomatology after 1 week. Nevertheless, in post-interventional month 1, no participant expressed dissatisfaction. 77% expressed mild reduction in symptoms. In this study we did not find a correlation with the total laser energy level and decrease between pre- and post-interventional difference in the visual disturbance scale nor a correlation with visual improvement after one week and one month, respectively. However, the median relief of initial symptoms was 45% which describes a decrease in visual disturbance scale in the studied sample.

Best Spectacle-Corrected Visual Acuity (BCVA) was improved in 40% of the patients with a decrease in intraocular pressure (IOP) with 30 %. 50% encountered an increase in IOP after first week. Cowan LA *et al.* discuss that in the very majority of cases IOP is transiently increased, returning to baseline levels 5-7 days post-interventional using acetazolamide and timolol in predominance of cases (75).

As there is no standardized questionnaire, in this prospective study we formed our own survey based on importance of symptomatology relief with guidance from other questionnaires used. In our pre-and post-intervention questionnaires a comparison between disturbance and improvement of daily activities was made. Statistically significant difference was observed in decrease of symptoms in driving after 1 week ($p=0.031$). Eight patients described no disturbance while driving before intervention, still 75% implied a decrease in symptoms. Despite low self-assessment of disturbance at baseline, majority of patients experienced improvement which can indicate unawareness of impaired quality of life and reduced functionality of daily activities. Participants, due to majority having a long period of symptoms, are assumed to adjust to the situation. This desensitization, being unaware of how much their visual acuity truly is compromised, correlates to vitreous opacities. Due to a small sample size other variables had no clinical significance. Though, assumption is made that larger studies need to be done to prove the clinical implication of decreased symptoms in patients with vitreous floaters. In our study a ratio of 6:4 (women: men) was found, similar to Stalmans P *et al.* study, stating that women and men are effected equally (36).

Limitations of this coherent study involves; a short follow-up period compared to other studies making it more difficult to conclude post-interventional benefits and adverse effects. Other restrictions included lack of a comparative study group, and minor sample size. When comparing to other studies there is a smaller amount of evidence based research for Nd:YAG laser vitreolysis in literature and more prospective studies are required. Additional restriction was that the efficacy and safety of Nd:YAG laser treatment was assessed by using pre-and post-interventional questionnaires compared to other studies that used photo-registrations, SLO imaging, US examinations or OCT angiography. Further limitation might be that patient expectations were not clearly assessed and predefined.

6. CONCLUSION

In this prospective study out of 10 patients diagnosed with symptomatic vitreous floaters with posterior vitreous detachment the results showed that Nd:YAG laser vitreolysis is an effective and compatible treatment which improves quality of life. Although results showed no statistical significance, majority of patients subjectively affirmed a decrease in symptom disturbance. Nevertheless, further studies have to be done in this field of ophthalmology involving randomized control trials, larger sample groups, comparability with other treatment options and a comprehensive follow-up time are needed.

7. REFERENCES

1. Lund- Andersen H, Sebag J, Sander B, La Cour M. The Vitreous. In: *Advances in Organ Biology*. New York: Springer; 2005.
2. Angi M, Kalirai H, Coupland SE, Damato BE, Semeraro F, Romano MR. Proteomic Analyses of the Vitreous Humour. *Mediators of Inflammation*. 2012.doi: 10.1155/edt.148039
3. Milston R, Madigan MC, Sebag J. Vitreous floaters: Etiology, diagnostics, and management. *Surv Ophthalmol*. 2016;61(2):211-27.
4. Sebag J, Buckingham B, Charles MA, Reiser K. Biochemical Abnormalities in Vitreous of Humans with Proliferative Diabetic Retinopathy. *Arch Ophthalmol*. 1992;110(10):1472-6
5. Delaney YM, Oyinloye A, Benjamin L. Nd:YAG vitreolysis and pars plana vitrectomy: Surgical treatment for vitreous floaters. *Eye*. 2002;16(1):21-6.
6. Hogan Mj. The vitreous, its structure, and relation to the ciliary body and retina. Proctor award Lecture. *Invest Ophthalmol Vis Sci*. 1963;2:418-45.
7. Lund- Andersen H, Sebag J, Sander B, La Cour M. The Vitreous. In: *Embryology of the Vitreous*. New York: Springer; 2005. p. 7-14.
8. Sebag J. *Vitreous*. 2nd ed. New York: Springer; 2014.
9. Sebag J, Balazs EA. Morphology and ultrastructure of human vitreous fibers. *Invest Ophthalmol Vis Sci*. 1989;30:1867-71.
10. Theopold H, Faulborn J. Scanning electron microscopic aspects of the vitreous body: Technique of preparation. *Graefes Arch Clin Exp Ophthalmol*. 1980;214(1):33-8.
11. Bishop PN, Crossman M V, McLeod D, Ayad S. Extraction and characterization of the tissue forms of collagen types II and IX from bovine vitreous. *Biochem J*. 1994;299(2):497–505.
12. Österlin SE, Jacobson B. The synthesis of hyaluronic acid in vitreous. I. Soluble and particulate transferases in hyalocytes. *Exp Eye Res*. 1968;7(4):497-510.
13. Sebag J, Balazs EA. Human vitreous fibres and vitreoretinal disease. *Eye*. 1985;104(2):123-8.
14. Gartner J. Histological observations on the behaviour of the vitreoretinal limiting layer in detachment of the vitreous. *Klin Monbl Augenheilkd Augenarztl Fortbild*. 1963;142:769-92.
15. Fine BS, Tousimis AJ. The Structure of the Vitreous Body and the Suspensory Ligaments of the Lens. *Arch Ophthalmol*. 1961;65:95-110.

16. Roth AM, Foos RY. Surface structure of the optic nerve head. 1. Epipapillary membranes. *Am J Ophthalmol*. 1972;5:977–85.
17. Jerdan JA, Glaser BM. Retinal microvessel extracellular matrix: An immunofluorescent study. *Invest Ophthalmol Vis Sci*. 1986;2:194-203.
18. Kohno T, Sorgente N, Ishibashi T, Goodnight R, Ryan SJ. Immunofluorescent studies of fibronectin and laminin in the human eye. *Investigative Invest Ophthalmol Vis Sci*. 1987;28:506-14.
19. Kaufman P, Levin L, Adler F, Alm A. Adler's Physiology of the Eye. In: Henrik Lund-Andersen & Birgit Sander, editors. The vitreous. 11th edition. Oxford: Elsevier Health Sciences; 2011. p. 164-79.
20. Newman EA. Regulation of potassium levels by Müller cells in the vertebrate retina. *Can J Physiol Pharmacol*. 2011;65(5):1028-32.
21. Seery CM, Davison PF. Collagens of the bovine vitreous. In: *Invest Ophthalmol Vis Sci*. 1991;32:1540-50.
22. Larsson L, Österlin S. Posterior vitreous detachment - A combined clinical and physicochemical study. *Graefes Arch Clin Exp Ophthalmol*. 1985;223(2):92-5.
23. Bishop PN, McLeod D, Reardon A. Effects of hyaluronan lyase, hyaluronidase, and chondroitin ABC lyase on mammalian vitreous gel. *Invest Ophthalmol Vis Sci*. 1999;40(10):2173-8.
24. Akiba J, Ueno N, Chakrabarti B. Age-related changes in the molecular properties of vitreous collagen. *Curr Eye Res*. 1993;12(10):951-4.
25. Jongebloed WL, Worst JFG. The cisternal anatomy of the vitreous body. *Doc Ophthalmol*. 1987;67(1-2):183-96.
26. Akiba J, Ueno N, Chakrabarti B. Mechanisms of photo-induced vitreous liquefaction. *Curr Eye Res*. 1994;13(7):505-12.
27. Sebag J. Abnormalities of human vitreous structure in diabetes. *Graefes Arch Clin Exp Ophthalmol*. 1993;231:257-60.
28. Sebag J. Age-Related Differences in the Human Vitreoretinal Interface. *Arch Ophthalmol*. 1991;109(7):966-71.

29. Bishop PN, Holmes DF, Kadler KE, McLeod D, Bos KJ. Age-related changes on the surface of vitreous collagen fibrils. *Invest Ophthalmol Vis Sci.* 2004;45:1041-6.
30. Los LI, Van der Worp RJ, Van Luyn MJA, Hooymans JMM. Age-related liquefaction of the human vitreous body: LM and TEM evaluation of the role of proteoglycans and collagen. *Invest Ophthalmol Vis Sci.* 2003;44:2828-33.
31. Ivanova T, Jalil A, Antoniou Y, Bishop PN, Vallejo-Garcia JL, Patton N. Vitrectomy for primary symptomatic vitreous opacities: an evidence-based review. *Eye.* 2016;30(5):645–55.
32. Klöti R. Experimental occlusion of retinal and ciliary vessels in owl monkeys. I. Technique and clinical observations of selective embolism of the central retinal artery system. *Exp Eye Res.* 1967;6:393-9.
33. Foos RY, Wheeler NC. Vitreoretinal Junction: Synchysis Senilis and Posterior Vitreous Detachment. *Ophthalmol.* 1982;89(12):1502-12.
34. Yonemoto J, Noda Y, Masuhara N, Ohno S. Age of onset of posterior vitreous detachment. *Curr Opin Ophthalmol.* 1996;7(3):73-6.
35. Coupland SE. The pathologist's perspective on vitreous opacities. In: *Eye.* 2008;10:1318-29.
36. Stalmans P, Benz MS, Gandorfer A, Kampik A, Girach A, Pakola S, et al. Enzymatic Vitreolysis with Ocriplasmin for Vitreomacular Traction and Macular Holes. *N Engl J Med.* 2012;367(7):606-15.
37. Schulz-Key S, Carlsson JO, Crafoord S. Longterm follow-up of pars plana vitrectomy for vitreous floaters: Complications, outcomes and patient satisfaction. *Ophthalmologica.* 2011;89(2):159-65.
38. Favre M, Goldmann H. Zur Genese der hinteren Glaskörperabhebung. *Ophthalmologica.* 2010;117:1199–206.
39. Webb BF, Webb JR, Schroeder MC, North CS. Prevalence of vitreous floaters in a community sample of smartphone users. *Int J Ophthalmol.* 2013;6(3):402-5.
40. Shaimova VA, Shaimov TB, Shaimov RB, Galin AY, Goloshchapova ZA, Ryzhkov PK, et al. Evaluation of YAG-laser vitreolysis effectiveness based on quantitative characterization of vitreous floaters. *Vestn Oftalmol.* 2018;134(1):56.

41. Tassignon MJ, Dhubhghaill SN, Hidalgo IR, Rozema JJ. Subjective grading of subclinical vitreous floaters. *Asia Pac J Ophthalmol (Phila)*. 2016;5(2):104-9.
42. Novak MA, Welch RB. Complications of acute symptomatic posterior vitreous detachment. *Am J Ophthalmol*. 1984;97(3):308-14.
43. Serpetopoulos CN, Korakitis RA. An optical explanation of the entoptic phenomenon of “clouds” in posterior vitreous detachment. *Ophthalmic Physiol Opt*. 1998;18(5):446-51.
44. Gale J, Ikuno Y. Myopic vitreopathy. In: *Vitreous: In Health and Disease*. 2014.
45. Kim Y-K, Moon SY, Yim KM, Seong SJ, Hwang JY, Park SP. Psychological Distress in Patients with Symptomatic Vitreous Floaters. *J Ophthalmol*. 2017;3191576.
46. Schiff WM, Chang S, Mandava N, Barile GR. Pars plana vitrectomy for persistent, visually significant vitreous opacities. *Retina*. 2000;20(6):591-6.
47. Sendrowski DP, Bronstein MA. Current treatment for vitreous floaters. *Optometry*. 2010;81(3):157–61.
48. Johnson MW. Posterior Vitreous Detachment: Evolution and Complications of Its Early Stages. *Am J Ophthalmol*. 2010;149(3):371-82.
49. Hlekamp NM. The Vitreous Gel: More than Meets the Eye. *Am J Ophthalmol*. 2010;149(1):32-6.
50. Mamou J, Wa CA, Yee KMP, Silverman RH, Ketterling JA, Sadun AA, et al. Ultrasound-Based Quantification of Vitreous Floaters Correlates with Contrast Sensitivity and Quality of Life. *Invest Ophthalmol Vis Sci*. 2015;56(3):1611–7.
51. Schwartz SG, Flynn HW, Fisher YL. “Floater Scotoma” Demonstrated on Spectral-Domain Optical Coherence Tomography and Caused by Vitreous Opacification. *Ophthalmic Surg Lasers Imaging Retina*. 2013;44(4):415-8.
52. Ansari RR, Suh KI, Dunker S, Kitaya N, Sebag J. Quantitative molecular characterization of bovine vitreous and lens with non-invasive dynamic light scattering. *Exp Eye Res*. 2001;6:859-66.
53. Sebag J. Pharmacologic vitreolysis - Premise and promise of the first decade. *Retina*. 2009;29(7):871-4.

54. Van Den Berg TJTP, Franssen L, Coppens JE. Straylight in the human eye: Testing objectivity and optical character of the psychophysical measurement. In: *Ophthalmic Physiol Opt.* 2009;29(3):345-50.
55. De Nie KF, Crama N, Crama MAD, Klevering BJ, Boon CJF. Pars plana vitrectomy for disturbing primary vitreous floaters: Clinical outcome and patient satisfaction. *Graefes Arch Clin Exp Ophthalmol.* 2013;251(5):1373-82.
56. Roth M, Trittibach P, Koerner F, Sarra G. [Pars plana vitrectomy for idiopathic vitreous floaters]. *Klin Monbl Augenheilkd.* 2005;222(9):728-32.
57. Kokavec J, Wu Z, Sherwin JC, Ang AJS, Ang GS. Nd: YAG laser vitreolysis versus pars plana vitrectomy for vitreous floaters. *Cochrane Database Syst Rev.* 2017;6:CD011676.
58. Mason JO, Neimkin MG, Mason JO, Friedman DA, Feist RM, Thomley ML, et al. Safety, Efficacy, and Quality of life following sutureless vitrectomy for symptomatic vitreous floaters. *Retina.* 2014;34(6):1055–61.
59. Tan HS, Mura M, Lesnik Oberstein SY, Bijl HM. Safety of vitrectomy for floaters. *Am J Ophthalmol.* 2011;151(6):995-8.
60. Sebag J, Yee KMP, Wa CA, Huang LC, Sadun AA. VITRECTOMY FOR FLOATERS. *Retina.* 2014;34(6):1062–8.
61. Sebag J. Molecular biology of pharmacologic vitreolysis *Am J Ophthalmol.* 2006;103:473–94.
62. Khoshnevis M, Sebag J. Pharmacologic vitreolysis with ocriplasmin: Rationale for use and therapeutic potential in vitreo-retinal disorders. *BioDrugs.* 2015;29(2):103-12.
63. Stalmans P, Benz MS, Gandorfer A, Kampik A, Girach A, Pakola S, et al. Enzymatic Vitreolysis with Ocriplasmin for Vitreomacular Traction and Macular Holes. *N Engl J Med.* 2012;367(7):606–15.
64. Floater-lft.com [Internet]. Minneapolis: YAG Laser Vitreolysis. Treatment of Vitreous Strands and Opacities, [updated 2018; cited 2013]. VB0002H 8437391EN ECR 05980 Available from: <https://www.floater-lft.com/physician-portal/treatment-guidelines/>
Gerbrandy F, Johnson JH. YAG Laser Vitreolysis. Treatment of Vitreous Strands and Opacities. 2013;2–5.

65. Bonner RF, Meyers SM, Gaasterland DE. Threshold for Retinal Damage Associated with the use of High-Power Neodymium-Yag Lasers in the Vitreous. *Am J Ophthalmol*. 2014;96(2):153-9.
66. Little HL, Jack RL. Q-Switched neodymium: YAG laser surgery of the vitreous. *Graefes Arch Clin Exp Ophthalmol*. 1986; 224:240-6.
67. Tsai WF, Chen YC, Su CY. Treatment of vitreous floaters with neodymium YAG laser. *Br J Ophthalmol*. 1993;77(8):485–8.
68. Vandorselaer T, Van De Velde F, Tassignon MJ. Eligibility criteria for Nd-YAG laser treatment of highly symptomatic vitreous floaters. *Bull Soc Belge Ophtalmol*. 2001;(280):15-9.
69. Shah CP, Heier JS. YAG Laser Vitreolysis vs Sham YAG Vitreolysis for Symptomatic Vitreous Floaters. *JAMA Ophthalmol*. 2017;135(9):918-23.
70. Luo J, An X, Kuang Y. Efficacy and safety of yttrium-aluminium garnet (YAG). laser vitreolysis for vitreous floaters *J Int Med Res*. 2018;46(11):4465-71.
71. Lim JI. YAG Laser Vitreolysis—Is It as Clear as It Seems? *JAMA Ophthalmol*. 2017;135(9):924-5.
72. Hahn P, Schneider EW, Tabandeh H, Wong RW, Emerson GG. Reported complications following laser vitreolysis. *JAMA Ophthalmol*. 2017;135(9):918-23.
73. Gregory E. Stein, Jesse J. Jung, Steven Bodine, Stephen L. Trokel, Stanley Chang. Vitrectomy for macular hole following Nd:YAG laser injury. *Taiwan J Ophthalmol*. 2016;6(4):195-8.
74. O'Day R, Cugley D, Chen C, Fabinyi D. Bilateral posterior capsule injury after Nd:YAG laser vitreolysis: unintended consequence of floaters treatment. *J Clin Exp Ophthalmol*. 2018;46(8):956-8.
75. Cowan LA, Khine KT, Chopra V, Fazio DT, Francis BA. Refractory open-angle glaucoma after neodymium-yttrium-aluminum-garnet laser lysis of vitreous floaters. *Am J Ophthalmol*. 2015;159(1):138-43.

8. SUMMARY

Title: Treating vitreous floaters with Nd:YAG laser vitreolysis: determined by vision related quality of life questionnaire

Objectives: Assess the efficacy, safety and benefits of treating vitreous floaters in symptomatic patients with Nd:YAG laser vitreolysis determined by a vision-related quality of life questionnaire, pre- and post-interventional.

Materials and methods: Participants diagnosed with symptomatic vitreous floaters at Split University Hospital, Department of Ophthalmology from April to May 2019, were consecutively admitted in this prospective study. We included adult patients with clinical symptoms of vitreous floaters or posterior vitreous detachment. Those with an obscured anterior segment of the eye, blurring of natural/artificial lens, endophthalmitis, adherence of opacities to the iris, uncontrolled intraocular pressure or degenerative pathologies were excluded from this study. The study participants were intervened with Nd:YAG laser vitreolysis and examined by a pre- and post-interventional questionnaire, being completed after one week and one month, respectively. Intraocular pressure (IOP) and best spectacle-corrected visual acuity (BCVA) were assessed before and after intervention.

Results: 10 eyes in 10 patients, having symptomatic vitreous floater, were diagnosed with posterior vitreous detachment and treated with a single-session Nd:YAG laser vitreolysis. Statistical significance was observed in decrease of symptomatology disturbance after week 1 ($P=0.031$) and a 45% median relief of the initial symptoms. Out of 10 participants, all but one was followed up 1 month after. Majority of patients experienced decrease of the disease symptoms. In this study no one claimed to suffer from post interventional difficulties. 2 participants complained on the adverse effects, one for choroid haemorrhage and one for retinal hit. However, no negative effect on vision or ocular anatomy was found. BCVA was improved in 40% of the patients with a 30% decrease in IOP.

Conclusion: Nd:YAG laser vitreolysis is an effective and compatible treatment which improves vision related quality of life. Although results showed no statistical significance, the coherent study showed a 90% decrease in symptoms after week 1 and a 100% decrease in month 1, subjectively affirmed by the participants. In two participants, adverse events were found. However, not significant to affect vision or structure of the eye. In our post-interventional questionnaire, comparing disturbances after one week and one month, 100% of the patients did not perceive any difficulties with vision or ocular function. Further studies have to be done in this field of ophthalmology involving randomized control trials, larger sample groups, comparability with other treatment options and a comprehensive follow-up time are needed.

9. CROATIAN SUMMARY

Naslov: Liječenje simptomatskih opaciteta staklovine YAG laserom: određivanje kvalitete života vezane za vid korištenjem upitnika

Ciljevi: Ispitati učinkovitost, sigurnost i zadovoljstvo pacijenata tretirani vitreolizom YAG laserom te istražiti kvalitetu života vezanu za vid prije i nakon intervencije.

Ispitanici i metode: Sudionici dijagnosticirani sa simptomima opaciteta staklovine pri Kliničkom Bolničkom Centru u Splitu, Klinici za očne bolesti, u period od travnja do svibnja 2019 uključeni su u ovo prospektivno istraživanje. Kriteriji isključenja iz ovog istraživanja bili su redom: nemogućnost podnošenja zahvata, zamagljenje prednjeg segmenta oka, zamućenje prirodne leće, aktivna upala oka i dr. Ispitanici su ispunjavali upitnik o kvaliteti života prije i tjedan odnosno mjesec dana nakon intervencije. Nadalje, svima su izmjereni intraokularni tlak te najbolja korigirana vidna oštrina, prije i nakon intervencije.

Rezultati: U istraživanje je uključeno ukupno 10 pacijenata sa simptomima opaciteta staklovine. Svi su ispitanici podvrgnuti vitreolizi Nd:YAG laserom. Statistički značajna razlika pronađena je u smanjenju simptoma bolesti nakon tjedan dana ($p=0.031$), a prosječno smanjenje početnih simptoma bilo je 45%. Nitko od ispitanika nije imao poteškoće nakon intervencije Nd:YAG laserom. Dvoje ispitanika je izrazilo sumnju na nuspojavu intervencije, preciznije krvarenje u zilnici kod jednog ispitanika, a kod drugoga puknuće/povreda mrežnice. Najbolja korigirana vidna oštrina se poboljšala kod 40 % ispitanika, a smanjenje intraokularnog tlaka uočeno je kod 30 % ispitanika.

Zaključak: Vitreoliza Nd:YAG laserom kod ispitanika sa simptomatskim opacitetom staklovine pokazala se učinkovitom i sigurnom u ovom istraživanju te je dovela do poboljšanja kvalitete života vezane za vid. Devedeset posto ispitanika je tjedan nakon intervencije izrazilo subjektivno smanjenje simptoma, a njih 100%, odnosno svi su imali subjektivno smanjenje simptoma nakon mjesec dana od intervencije. Iako su dva ispitanika izrazile sumnju na nuspojavu uzrokovanu intervencijom, ove nuspojave nisu imale utjecaj na njihov vid ili dovele do promjene anatomske strukture samog oka. Potrebna su buduća istraživanja u ovom polju oftalmologije, posebice randomizirani kontrolirani klinički pokusi, ali i istraživanja koja će uključivati veći broj ispitanika, duži period praćenja ispitanika te usporedbu s drugim intervencijama.

10. CURRICULUM VITAE

Personal Data:

Name and Surname: Amar Osmancevic

Date of birth: 23 rd of January 1994 in Mariestad, Kingdom of Sweden

Citizenship: Swedish

Address: Ul. Marina Getaldica 23, 21000 Split, Croatia

E-mail: osmancevicamar@gmail.com

Education:

2001-2004 Gustaviskolan, Gothenburg, Sweden

2004-2007 Backa Skolan, Gothenburg, Sweden

2007-2010 Narturvetenskapsklassen, Skälltorpsskolan, Gothenburg, Sweden

2010-2013 Jensen Gymnasium, Natur, Gothenburg, Sweden

2013-2019 University of Split, School of Medicine, Split, Croatia

Languages: Swedish (first language)

English (C1); Bosnian (C1); Croatian (C1) Spanish (A1)

Extracurricular: I am a dynamic person who constantly strives for improving my personal development, characterized by strong communication, high stress resistance and great dedication.